

Otorhinolaryngologica Italica

Volume 35

4

August 2015

*Official Journal of the Italian Society of Otorhinolaryngology
Head and Neck Surgery*

Organo Ufficiale della Società Italiana di Otorinolaringologia
e Chirurgia Cervico-Facciale

Review

Sialoendoscopy: state of the art, challenges and further perspectives.
Round Table, 101st SIO National Congress, Catania 2014

Head and neck

Clinicopathologic characteristics of familial versus
sporadic papillary thyroid carcinoma

Analysis of risk factors for pharyngocutaneous fistula after total laryngectomy
with particular focus on nutritional status

Otology

Musical training software for children with cochlear implants

Individualised headband simulation test for predicting outcome
after percutaneous bone conductive implantation

Pediatric otorhinolaryngology

Foreign body injuries in children: a review

Audiology

Does the addition of a second daily session of hyperbaric oxygen therapy
to intratympanic steroid influence the outcomes of sudden hearing loss?

Basic research in otorhinolaryngology

Quantification of cells expressing markers of proliferation and apoptosis
in chronic tonsillitis

Clinical techniques and technology

Correction of a mandibular asymmetry after fibula reconstruction
using a custom-made polyetheretherketone (PEEK) onlay after implant
supported occlusal rehabilitation

Case series and reports

Parapharyngeal metastases from thyroid cancer: surgical management
of two cases with minimally-invasive video-assisted technique

Giant pleomorphic adenoma of the parotid gland:
an unusual case presentation and literature review

Minimally invasive surgical removal of an intracochlear schwannoma causing
an intractable paroxysmal positional vertigo

PACINI
EDITORE
MEDICINA

www.actaitalica.it



ACTA

Otorhinolaryngologica Italica

Official Journal of the Italian Society of Otorhinolaryngology - Head and Neck Surgery
Organo Ufficiale della Società Italiana di Otorinolaringologia e Chirurgia Cervico-Facciale

Former Editors-in-Chief: C. Calearo†, E. de Campora, A. Staffieri, M. Piemonte, F. Chiesa

Editorial Board

Editor-in-Chief:

G. Paludetti

President of S.I.O.:

R. Filipo

Former Presidents of S.I.O.

and Editors-in-Chief:

I. De Vincentiis, D. Felisati, L. Coppo,

G. Zaoli, P. Miani, G. Motta,

L. Marcucci, A. Ottaviani,

P. Puxeddu, M. Maurizi, G. Sperati,

D. Passali, E. de Campora, A. Sartoris,

P. Laudadio, M. De Benedetto,

S. Conticello, D. Casolino,

A. Rinaldi Ceroni, M. Piemonte,

A. Staffieri, F. Chiesa, R. Fiorella,

A. Camaioni, A. Serra, G. Spriano

Editorial Staff

Editor-in-Chief:

G. Paludetti

Deputy Editor:

J. Galli

Associate Editors:

G. Almadori, F. Ottaviani

Editorial Coordinator:

E. De Corso

Editorial Assistant:

P. Moore

Treasurer:

L. de Campora

Italian Scientific Board

L. Bellussi, G. Danesi, C. Grandi,

A. Martini, L. Pignataro, F. Raso,

R. Speciale, I. Tasca

International Scientific Board

J. Betka, P. Clement, M. Halmagyi,

L.P. Kowalski, M. Pais Clemente,

J. Shah, H. Stammberger, R. Laszig,

G. O'Donoghue, R.J. Salvi, R. Leemans,

M. Remacle, F. Marshal, H.P. Zenner,

B. Scola Yurrita, R.W. Gilbert

Editorial Office

Editor-in-Chief:

G. Paludetti

Department of Head and Neck Surgery -

Otorhinolaryngology

Catholic University of the Sacred Heart

“A. Gemelli” Hospital

L.go F. Vito, 1 - 00168 Rome, Italy

Tel. +39 06 30154439

Fax + 39 06 3051194

actaitalicaorl@rm.unicatt.it

Editorial Coordinator:

E. De Corso

eugenio.decorso@rm.unicatt.it

Editorial Secretary:

R. Gallus

gallusroberto@gmail.com

Argomenti di Acta

Otorhinolaryngologica Italica

Editor-in-Chief: G. Paludetti

Editorial Coordinator: M.R. Marchese

raffaellamarchese@gmail.com

© Copyright 2015 by

Società Italiana di Otorinolaringologia

e Chirurgia Cervico-Facciale

Via Luigi Pigorini, 6/3

00162 Rome, Italy

Publisher

Pacini Editore SpA

Via Gherardesca, 1

56121 Pisa, Italy

Tel. +39 050 313011

Fax +39 050 3130300

info@pacinieditore.it

www.pacinimedicina.it

Acta Otorhinolaryngologica Italica is cited

in Index Medicus, MEDLINE, PubMed

Central, Science Citation Index Expanded,

Scopus, DOAJ, Open-J Gate, Free Medical

Journals, Index Copernicus, Socolar

Journal Citation Reports:

Impact Factor 1.640

Acta Otorhinolaryngologica Italica is

available on Google Scholar

PACINI
EDITORE
MEDICINA

www.actaitalica.it



Contents

Review

- Sialoendoscopy: state of the art, challenges and further perspectives. Round Table, 101st SIO National Congress, Catania 2014
Scialoendoscopia: stato dell'arte, limiti e prospettive future. Tavola Rotonda, 101° Congresso Nazionale SIO, Catania 2014
A. Gallo, M. Benazzo, P. Capaccio, L. de Campora, M. De Vincentiis, M. Fusconi, S. Martellucci, G. Paludetti, E. Pasquini, R. Puxeddu, R. Speciale pag. 217

Head and neck

- Clinicopathologic characteristics of familial versus sporadic papillary thyroid carcinoma
Caratteristiche clinicopatologiche del carcinoma tiroideo papillare familiare a confronto con il carcinoma tiroideo papillare sporadico
L. Jiwang, L. Zhendong, L. Shuchun, H. Bo, L. Yanguo » 234
- Analysis of risk factors for pharyngocutaneous fistula after total laryngectomy with particular focus on nutritional status
Fistola faringocutanea dopo laringectomia totale: analisi dei fattori di rischio con particolare attenzione allo stato nutrizionale
F. Mattioli, M. Bettini, G. Molteni, A. Piccinini, F. Valoriani, S. Gabriele, L. Presutti » 243

Otology

- Musical training software for children with cochlear implants
Software di training musicale per bambini con impianto cocleare
W. Di Nardo, L. Schinaia, R. Anzivino, E. De Corso, A. Ciacciarelli, G. Paludetti » 249
- Individualised headband simulation test for predicting outcome after percutaneous bone conductive implantation
Il test di simulazione individualizzato con headband per la predizione dei risultati dopo impianto uditivo percutaneo
S. Monini, C. Filippi, F. Atturo, M. Biagini, A.I. Lazzarino, M. Barbara » 258

Pediatric otorhinolaryngology

- Foreign body injuries in children: a review
Lesioni da corpo estraneo nei bambini: una revisione
D. Passali, D. Gregori, G. Lorenzoni, S. Cocca, M. Loglisci, F.M. Passali, L. Bellussi » 265

Audiology

- Does the addition of a second daily session of hyperbaric oxygen therapy to intratympanic steroid influence the outcomes of sudden hearing loss?
L'aggiunta di una seconda sessione giornaliera di camera iperbarica al trattamento steroideo intratimpanico influenza i risultati terapeutici nella sordità improvvisa?
G. Attanasio, E. Covelli, L. Cagnoni, E. Masci, D. Ferraro, P. Mancini, E. Alessandri, G. Cartocci, R. Filipo, M. Rocco. . . . » 272

Basic research in otorhinolaryngology

- Quantification of cells expressing markers of proliferation and apoptosis in chronic tonsillitis
Quantificazione delle cellule che esprimono i marcatori di proliferazione e apoptosi nelle tonsilliti croniche
V. Avramović, V. Petrović, M. Jović, P. Vlahović » 277

Clinical techniques and technology

- Correction of a mandibular asymmetry after fibula reconstruction using a custom-made polyetheretherketone (PEEK) onlay after implant supported occlusal rehabilitation
Correzione di asimmetria mandibolare a seguito di ricostruzione con fibula mediante protesi customizzata in polietheretherketone (PEEK) dopo riabilitazione protesica impianto supportata
M. Berrone, C. Aldiano, M. Pentenero, S. Berrone. . . . » 285

Case series and reports

- Parapharyngeal metastases from thyroid cancer: surgical management of two cases with minimally-invasive video-assisted technique
Metastasi dello spazio parafaringeo da carcinoma della tiroide: trattamento chirurgico di due casi con tecnica video-assistita mini-invasiva
L. Giordano, F. Pilolli, S. Toma, M. Bussi. . . . » 289
- Giant pleomorphic adenoma of the parotid gland: an unusual case presentation and literature review
Adenoma pleomorfo gigante della ghiandola parotide: caso clinico e revisione della letteratura
A. Tarsitano, A. Pizzigallo, F. Giorgini, C. Marchetti » 293
- Minimally invasive surgical removal of an intracochlear schwannoma causing an intractable paroxysmal positional vertigo
Trattamento chirurgico mini-invasivo di un neurinoma cocleare scatenante una vertigine parossistica posizionale non responsiva al trattamento
B. Sergi, E. De Corso, D. Lucidi, G. Paludetti » 297
- In Memoriam of Prof. Giorgio Sulenti
P. Palma, I. Tasca » 300

- Notiziario SIO » 301

- Calendar of events - Italian and International Meetings and Courses » 304

Information for authors including editorial standards for the preparation of manuscripts
available on-line: www.actaitalica.it

REVIEW

Sialoendoscopy: state of the art, challenges and further perspectives. Round Table, 101st SIO National Congress, Catania 2014

Scialoendoscopia: stato dell'arte, limiti e prospettive future. Tavola Rotonda, 101° Congresso Nazionale SIO, Catania 2014

A. GALLO¹, M. BENAZZO², P. CAPACCIO³, L. DE CAMPORA⁴, M. DE VINCENTIIS⁵, M. FUSCONI⁵, S. MARTELLUCCI¹, G. PALUDETTI⁶, E. PASQUINI⁷, R. PUXEDDU⁸, R. SPECIALE⁹

¹ Department of Medico-surgical sciences and biotechnologies, ENT Section, Sapienza University of Rome, Italy; ² Department of Otorhinolaryngology, University of Pavia, IRCCS Policlinico "S. Matteo" Foundation, Pavia, Italy, ³ Department of Biomedical, Surgical and Dental Sciences, Fondazione I.R.C.C.S. Ospedale Maggiore Policlinico "Mangiagalli e Regina Elena", University of Milano, Italy; ⁴ Department of Otorhinolaryngology, "Fatebenefratelli" Hospital, Roma, Italy; ⁵ Department of Sense Organs, ENT Section, Policlinico "Umberto I", Sapienza University of Rome, Italy; ⁶ Department of Head and Neck Surgery, Institute of Otorhinolaryngology, Università Cattolica del Sacro Cuore, Italy; ⁷ Ear, Nose and Throat Unit, "Sant'Orsola-Malpighi" Hospital, Bologna, Italy; ⁸ Department of Otorhinolaryngology, AOU, PO "S. Giovanni di Dio", University of Cagliari, Italy; ⁹ Department of Biomedicine and Neurosciences Clinic, Otorhinolaryngology Unit, University of Palermo; Italy

SUMMARY

This draft of the Official Round Table held during the 101st SIO National Congress is an updated review on sialoendoscopy, a technique used for diagnosis and treatment of obstructive pathologies of salivary glands in a minimally invasive fashion. This review treats many aspects of salivary gland endoscopy, starting from anatomy to deal with the more advanced surgical techniques and analyses the main decisional algorithms proposed in the literature. In addition, particular attention was directed to the current limitations of this technique and to the potential developments that sialoendoscopy could have in the near future.

KEY WORDS: Sialoendoscopy • Salivary glands • Endoscopic surgery • Sialoadenitis • Sialolithiasis • Salivary duct

RIASSUNTO

Questo testo è un estratto della Tavola Rotonda Istituzionale tenutasi durante il 101° Congresso Nazionale SIO. Si tratta di una revisione aggiornata sulla scialoendoscopia, metodica che mira all'esplorazione e al trattamento mini-invasivo delle patologie ostruttive delle ghiandole salivari maggiori. Il lavoro proposto analizza i molteplici aspetti dell'endoscopia dei dotti salivari, a partire dall'anatomia endoscopica per approfondire le tecniche chirurgiche più avanzate, passando per l'analisi dei principali algoritmi decisionali proposti in letteratura. Particolare attenzione è inoltre stata rivolta ai limiti attuali della metodica e ai potenziali sviluppi che l'endoscopia delle ghiandole salivari maggiori potrà vivere nel prossimo futuro.

PAROLE CHIAVE: Scialoendoscopia • Ghiandole salivari • Chirurgia endoscopica • Scialoadenite • Scialolitiasi • Dotti salivari

Acta Otorhinolaryngol Ital 2015;35:217-233

Introduction

Sialoendoscopy is a recently developed technique for diagnosis and treatment of obstructive pathologies of the major salivary gland. Described for the first time in the early 1990s by Katz¹, this minimally invasive technique has become widespread in the last 15 years, especially thanks to two European schools (Geneva and Erlangen) and to the school of Ashkelon, Israel. The clinical research by the pioneers of this technique, associated with technological advances, have deeply modified the management of salivary ductal patholo-

gies, changing the treatment of obstructive sialoadenitis.

This review treats many aspects of salivary gland endoscopy, starting from anatomy, to focus on the more advanced surgical techniques and analyses the main decisional algorithms proposed in literature. The objective of this article is to describe the main features of salivary gland endoscopy and provide an overview of its current and future fields of application.

Anatomy of the salivary ducts

The parotid excretory duct (Stensen's duct, SD), first de-

scribed by Niels Stensen, forms from the convergence of second and third-order tributary ducts that arise from the deep and superficial lobe, joining near the anterior border of the gland and leaving the gland in its anterosuperior third. SD runs forward over the lateral surface of the masseter muscle and turns around its anterior border, approximately a finger's breadth below the zygomatic arch, and then passes through the buccal fat pad, the buccopharyngeal fascia and the buccinator muscle. It runs forward obliquely for a short distance between the buccinator and oral mucosa before opening on it with a small papilla at the level of the maxillary second molar.

The surface markings of the duct are obtained by joining a line from the anterior point of the tragus with the mid-point of a line drawn between the lowest point of the alar cartilage and the angle of the mouth. When dividing this line into three equal parts, the middle section corresponds to the position of the parotid duct. The duct lies approximately 1 cm below the transverse facial vessels.

The length of SD varies from 4 to 7 cm with an average diameter of 1.4 mm at the hilum, 1.2 mm passing through the buccinator muscle and 0.5 mm at the papilla orifice². Some authors have reported the existence of small muscle fibres originating from the buccinator muscle which fit on the outer layer of the distal portion of the SD, thus playing a role in the regulation of salivary secretion and acting as a passive sphincter system³⁻⁵.

The submandibular duct (Wharton's duct, WD) was first described by Thomas Wharton. It forms from the joining of numerous branches arising from the deep surface of the gland, running backwards along the inferior border of the mylohyoid muscle. Once it reaches the posterior border of the muscle, it turns upward forming the WD genu. Then, the WD runs forward laterally to the hyoglossus and genioglossus and medially to the attachment of the mylohyoid muscle to the mandible along the medial side of the sublingual gland. It runs superiorly to the hypoglossal nerve and at the anterior border of the hyoglossus. It is crossed laterally by the lingual nerve.

WD then opens into the oral cavity through a narrow orifice, with a diameter of 0.1-0.5 mm, on the top of the sublingual caruncle behind the lower incisor. WD is approximately 4-6 cm long, with an average diameter of 1.5 mm^{2,6,7}. Sometimes the major sublingual duct is joined to WD⁸.

WD genu is defined as the angle between the main duct and the main intraglandular duct, but it represents the change in angulation when the duct turns around the posterior free margin of the mylohyoid muscle¹³. The genu angle varies significantly from 24° to 178°, but this variability does not appear to be associated with sialolithiasis or sialadenitis⁶.

In both SD and WD, the epithelium lining is smooth and pale pink, showing the blood vessels in transparency. Furthermore, the sphincter function of the ducts is reflected

by the presence of circular ridges on the mucosa lining, especially in the papillary region. Along the main duct, numerous accessory ducts may be opened and may have numerous patterns of bifurcation of the first order ducts at the hilar level, which at the intraparenchymal level become second and third order ducts.

Diagnostic and operative sialoendoscopy: equipment and basic technique

The first endoscopic approach to the salivary glands requires specific instruments (sialoendoscopes), which have notably evolved since the first model described by Katz¹. The miniaturised optical fibres can be introduced inside sheaths of varying shape and diameter or be included in so-called "all-in-one" endoscopes. These semi-flexible tools are made from nitinol and guarantee great resistance, manoeuvrability and fine optical resolution. There are two types of "all-in-one" endoscopes: diagnostic and operative. While the diagnostic sialoendoscope has only an irrigation channel, operative sialoendoscopes have also a working channel for the insertion of dedicate tools (baskets, forceps or balloons). The size of the working channel determines the overall diameter of the "all-in-one" sialoendoscope.

Sialoendoscopes are connected to optical devices (cold lighting source, video camera and monitor) and to irrigation systems. Irrigation is mandatory in order to expand the duct, thus avoiding its collapse under periductal pressure. It is usually performed by connecting a 20 ml syringe filled with saline to the irrigation channel of the endoscope.

Many miniaturised tools can be introduced into the working channels: wire baskets are used for removing stones and foreign bodies, mini-grasping forceps can be used to remove debris or smaller stones without a basket and high-pressure balloons are useful for duct stenosis dilation. Laser fibres and microdrills are helpful in stone fragmentation.

The sialoendoscopic procedure could be divided into two phases: salivary duct access (through the papilla or the duct wall) and endoluminal phase⁹. The procedure can be carried out under local or under general anaesthesia. Local anaesthesia is usually performed with topical lidocaine before salivary duct dilation. Local infiltration with anaesthetic and vasoconstrictor can be performed in some cases, to show a difficult papilla or when papillotomy is required. General anaesthesia should be recommended for more complex and lengthy procedures or in non-compliant patients⁹⁻¹⁵.

Several techniques were proposed to access the main salivary duct. The classic technique is achieved by progressively expanding the papilla with salivary probes having progressive diameters in order to expand the duct to reach the endoscope diameter⁹. A conic dilator completes dilation with the probes.

Currently, several techniques have been proposed to simplify the introduction of the endoscope through the papilla. These include the introduction of a guidewire into the papilla and its dilation using sheaths in metal or in plastic materials. Then, without removing the guidewire, the dilator is directly replaced by the endoscope whose operating channel is taken up by the guidewire¹⁰.

The retropapillary technique, first proposed by Nahlieli, is utilised when the papilla of submandibular gland cannot be localised¹¹. An incision is made using preventive infiltration at the level of the oral pelvis parallel to the axis of the duct, searching for it carefully on the medial face of the sublingual gland. Once the duct is detected, a 1 mm cut is performed to allow endoscope insertion.

On the other hand, when the papilla is localised but there is a stenosis of the duct, atraumatic endoscope insertion may be difficult. A mini-papillotomy, a lengthwise cut of the distal part of the papilla, allows solving this problem. The mini-papillotomy should not be longer than 3-4 mm in order to avoid postsurgical papillar stenosis and makes the procedure more technically challenging due to leakage of the irrigation. This technique is reserved for cases where an atraumatic approach is not possible, such as papillary hypertrophy, papillary stenosis or extremely small ductal orifices^{12,13}.

After endoscope insertion, the entire ductal system is explored from the main duct to the peripheral branches. Certain tracts of the gland are more difficult to access and to explore and, consequently, to pass through with the endoscope. These are commonly referred to as the "comma area" of WD, where the duct turns inferiorly at the posterior border of the mylohyoid muscle; in the case of SD, most difficulties are encountered in the area posterior to the duct's curvature (around the masseter muscle) and when the duct passes through the buccinator muscle¹⁴. The presence of an assistant is useful to provide correct visualisation of the surgical field by continuous irrigation and to support the surgeon in managing the operative instruments.

The technique for sialolith removal depends on size, shape, mobility and location of the stone. Stones floating in the duct having regular contours and a major axis parallel to the main duct are usually extracted with wire baskets. The basket is placed behind the stone, opened entrapping it and then gently retracted. Final exploration of all the branches of the salivary duct is mandatory to detect the presence of other residual stones. Sialoliths impacted in the ductal lumen require lithotripsy¹². A combined approach is reserved to those stones that for size and position cannot be fragmented¹²⁻¹⁴.

Management of stenosis often requires endoluminal dilation, which can easily be achieved with high-pressure balloons, microdrills, forceps, or simply with a larger endoscope¹⁵. Defining the exact location and extension of a stenosis is challenging. Placement of an intra-ductal stent

is sometimes necessary. After appropriate exploration of the gland ducts, endoluminal irrigation with steroid solution under endoscopic control may be useful to remove mucous plugs and alleviate ductal inflammation.

Learning curve in sialoendoscopy

There are few reports in the literature regarding the learning curve for sialoendoscopy. This procedure, like all endoscopic techniques, requires specific skills. According to Luers¹⁶, a shorter learning curve can be assumed since otolaryngologists commonly have experience with endoscopic procedures in general and an experienced supervisor can support the process by direct feedback and practical help. However, sialoendoscopy differs from other endoscopic procedures in many ways (smaller endoscopes, newer instruments, endoscopy in a fluid-filled branched system). The actual endpoint of the individual learning curve with performance results, operating times and rate of complications similar to those reported in the literature, can be reached in approximately 50 cases^{16,17}.

As with any new form of technology, there are several barriers in beginning a successful sialoendoscopy program¹⁸. Kroll, in a statistical survey regarding the prevalence of sialoendoscopy in ENT clinics, documented how, in 2009, it was performed in only a minority (24%) of ENT Departments in Germany. Its diffusion was hampered by technical problems, a lack of cost benefits, a lack of adequate instrumentation and a small number of patients¹⁹. The first difficulty encountered when beginning this new technique is the elevated initial costs of the sialoendoscopes and related equipment^{18,19}. Technically, the first problem is related to difficulties in canalising and dilating the duct to allow appropriate endoscopic use, bypassing and dilating strictures¹⁸. Vairel et al. found it impossible to catheterise in 6 cases of the first 101 (5.9%) in their experience¹⁷. When initial identification and dilation of the punctum seems challenging, it may be useful to perform it under magnification with loupes or, as reported by other authors, with a microscope¹⁸.

Sialoendoscopic treatment of salivary stones may improve with increased surgical experience. Modest et al. reported their experience in two consecutive groups of patients presenting sialolithiasis. In the first group of 43 patients, endoscopic removal occurred in 20% of cases and gland resection was required in 34.3% of patients, while in the second group of 39 patients, endoscopic removal increased to 35.9% of patients and gland resection was reduced to 0%²⁰.

Another parameter in the advancement of the learning curve can be defined by the need to perform the sialoendoscopic procedure under general anaesthesia less and less frequently. Operating on the first cases under general anaesthesia may be helpful to avoid patient discomfort due to longer procedure times. According to Vairel et al., with an increase in experience, a higher number of inter-

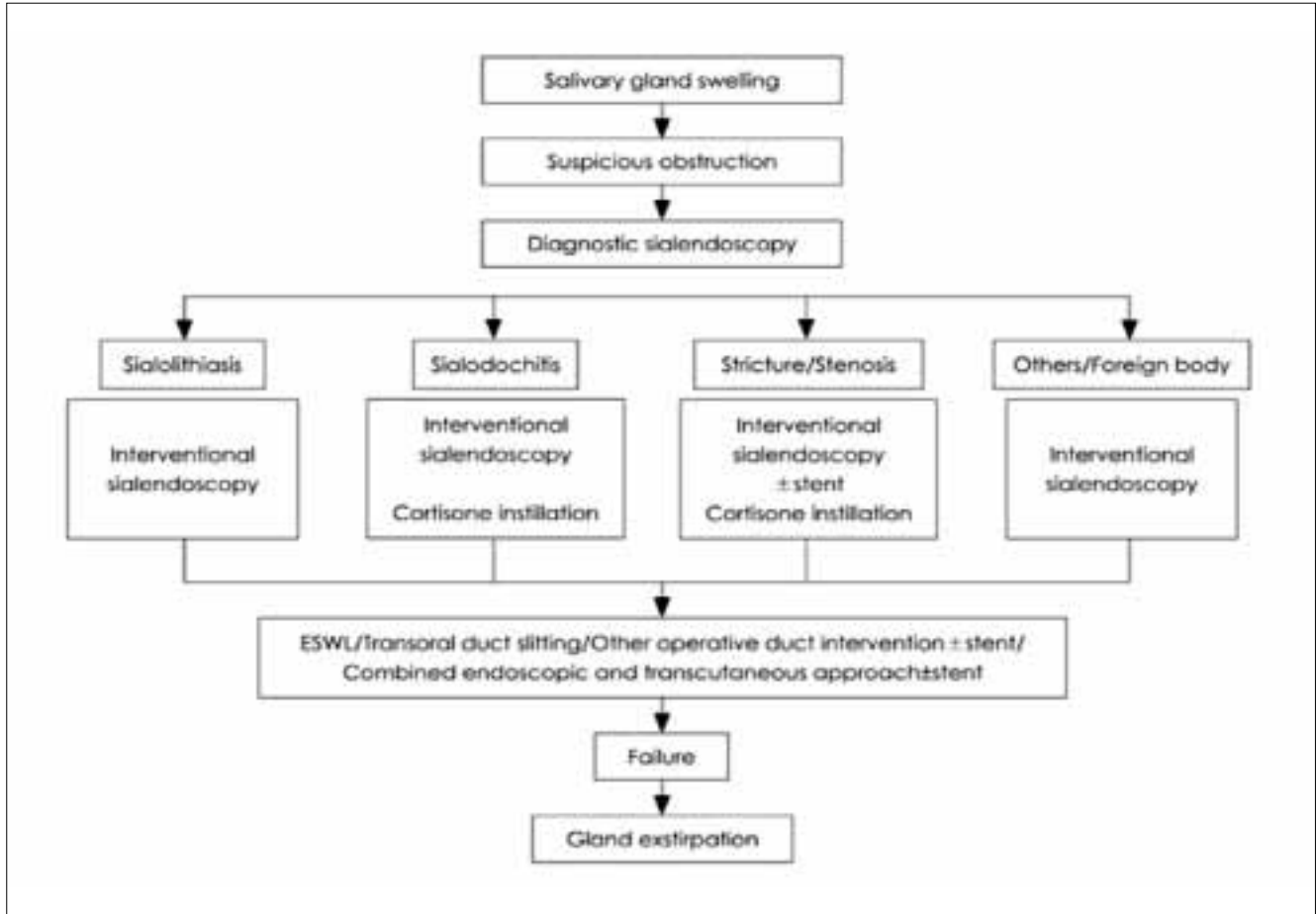


Fig. 1. Treatment plan and therapeutic strategy for obstructive salivary gland diseases according to Koch et al. 2009²⁴, mod.

ventional sialoendoscopies can be performed under local anaesthesia, limiting the use of general anaesthesia to more complex cases¹⁷.

Indications of sialoendoscopy and review of decision-making algorithms

The goal of sialoendoscopy is to resolve the obstructive condition preserving at the same time a physiologically intact gland²¹⁻²³. Over the years, several treatment algorithms for sialolithiasis and obstructive pathologies have been proposed to provide a more accurate selection of cases.

These algorithms have generally shown consensus concerning the size of stones, site of obstruction and technologies available^{21 24 25}.

The current clinico-diagnostic algorithm for any glandular swelling includes ultrasound and the use of diagnostic and therapeutic sialoendoscopy (Fig. 1). The actual indications of sialoendoscopy are sialolithiasis, stenosis, foreign bodies, polyps, recurrent sialoadenitis and sialoadenosis.

In detail, analysing the sialolithiasis: small, mobile stones of 3-4 mm or less can be easily removed via simple basket extraction, while larger, impacted stones with diameters > 7 mm are generally treated with combined endo-

scopic and transoral/transfacial approaches²⁶. For stones between 4 and 7 mm, the best treatment depends on available technology. If stones are too large for simple basket retrieval, they need to be fragmented before endoscopic extraction (Fig. 2).

Concerning parotid sialolithiasis, some authors^{24 26 27} described different approaches based on the size and location of the stones (Fig. 3):

1. Anterior third of SD (distal duct): interventional sialoendoscopy must be the first therapeutic option in case of stones < 7 mm, eventually combined with transoral removal.
2. Middle third, (middle, proximal duct): other options for stones > 3 mm include stone fragmentation by (extracorporeal shock wave lithotripsy, ESWL) or intracorporeal lithotripsy followed by interventional sialoendoscopy combined with transcutaneous or lifting approach^{24 28-33}.
3. In the posterior third of SD (intraparenchymal), sialoendoscopy combined with fragmentation techniques, combined surgery, or ESWL, are the only alternatives to parotidectomy.

In submandibular gland sialoliths, the current algorithm is based on the location of the stones (Fig. 4):

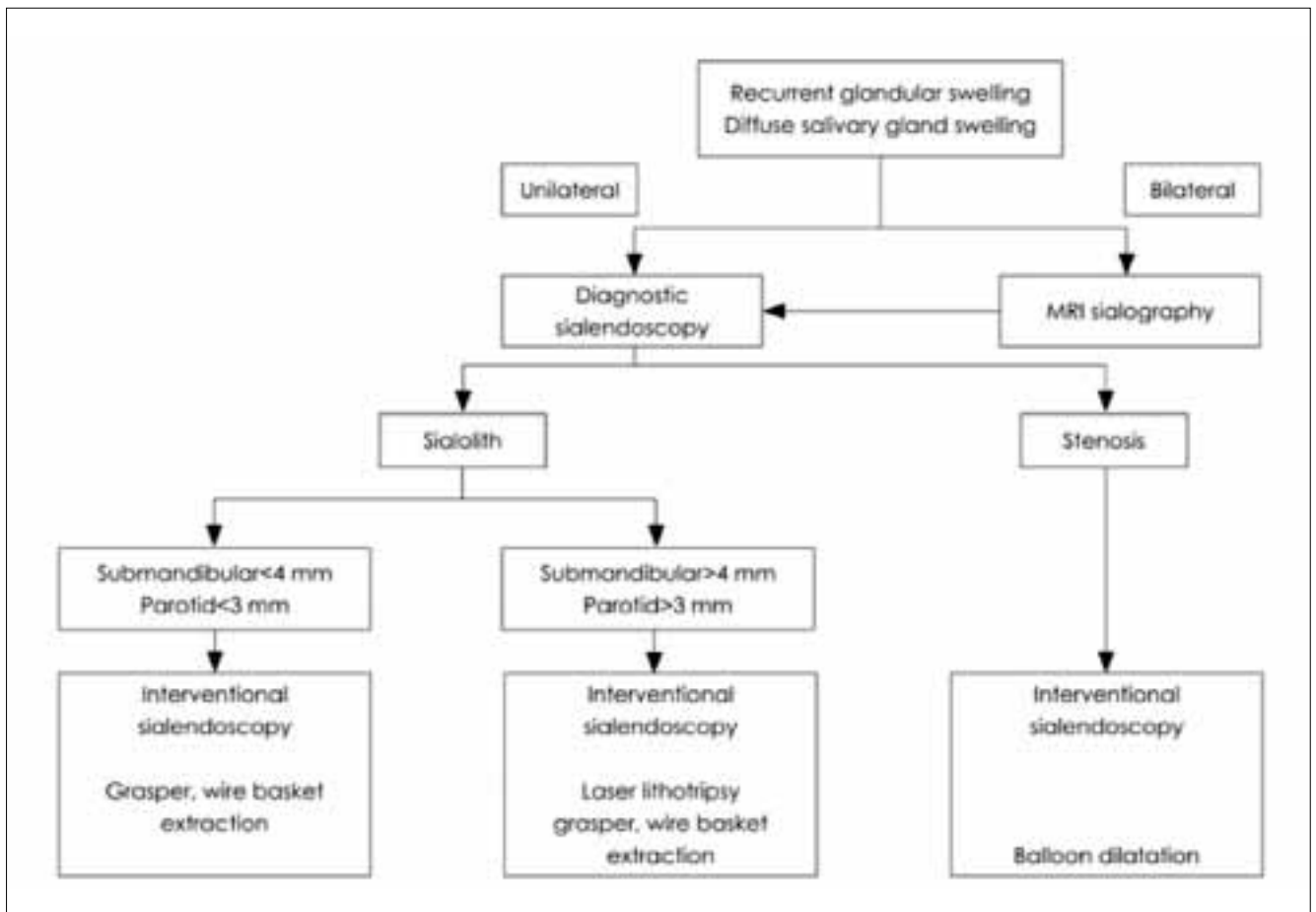


Fig. 2. Decision algorithm for the evaluation and management of sialolithiasis (from Marchal and Dulguerov, 2003²³, mod.).

1. Distal duct/papilla. If there are mobile ductal stones < 5 mm, sialoendoscopy with basket retrieval may be the first attempt, and papillotomy may be necessary; if the stones are impacted, transoral duct slitting is generally performed before interventional sialoendoscopy.
2. Proximal duct/hilum: in case of small, mobile stones < 5 mm attempting to remove the stone with a wire basket or grasping forceps is indicated; if stones are > 7 mm and palpable, a transoral duct incision or combined endoscopic-guided removal can be performed if fragmentation via ESWL or laser lithotripsy are not available.
3. Intraparenchymal: mobile stones < 7 mm can be removed via interventional sialoendoscopy if they are impacted; stones > 7 mm up to 10 mm can be fragmented with laser or ESWL allowing endoscopic removal.

In case of partial success or failure of sialoendoscopy, endoscopically-assisted transoral removal can be performed; however, sialoadenectomy still remains the definitive therapeutic solution even in case of failure as well as intraparenchymal stones not fragmented by ESWL¹⁴. The characteristics of the stenosis may be assessed by ultra-

sound or MRI, but in recent years sialoendoscopy has contributed to the introduction of the LSD (lithiasis, stenosis and dilatations) classification system (2007). LSD classifies the stenosis according to site, extension and number²¹. Sialoendoscopy has the advantage of direct assessment, allowing differentiation between an inflammatory reaction from a fibrous stenosis. The majority of the former may be successfully treated conservatively (irrigation and intraductal steroid instillation), whereas the latter can usually only be managed by endoscopically-controlled instrumental dilatation. Besides papillotomy and distal duct incision, resection of the affected segment and duct repair are generally successful. Stent implantation is important to prevent restenosis and many authors advocate it even if there is still no worldwide consensus on this issue regarding the time and positioning of stenting. In rare cases, ligation of the duct with subsequent parotid atrophy is an option and avoids parotidectomy, but with success rates of only around 50%. As an additional option, repeated intraglandular application of botulinum toxin may also be attempted as an alternative to gland removal. The diagnostic algorithm for stenosis or strictures of the submandibular glands and parotid glands is illustrated in detail in Figures 5 and 6.

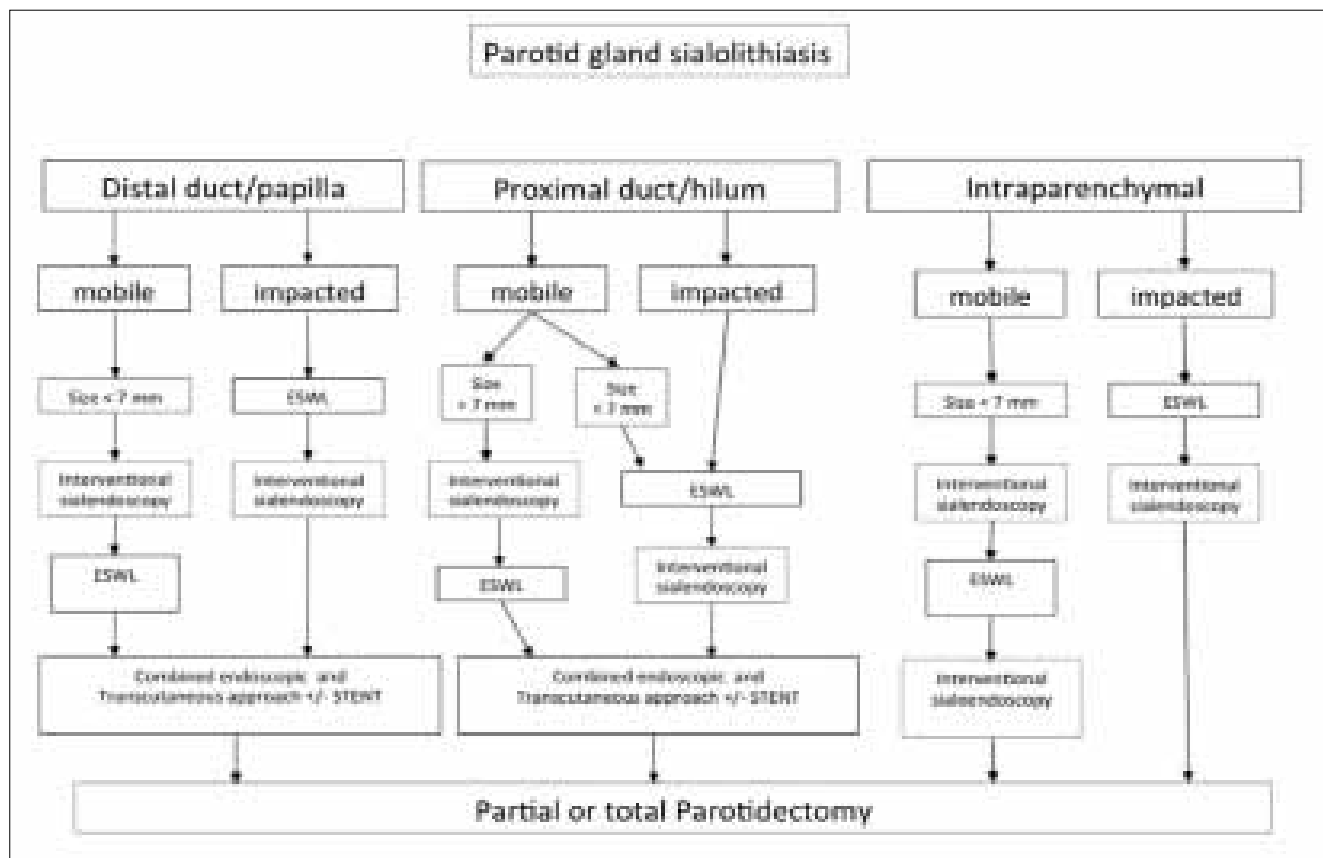


Fig. 3. Management of parotid salivary stones (from Koch et al. 2009²⁴, mod.).

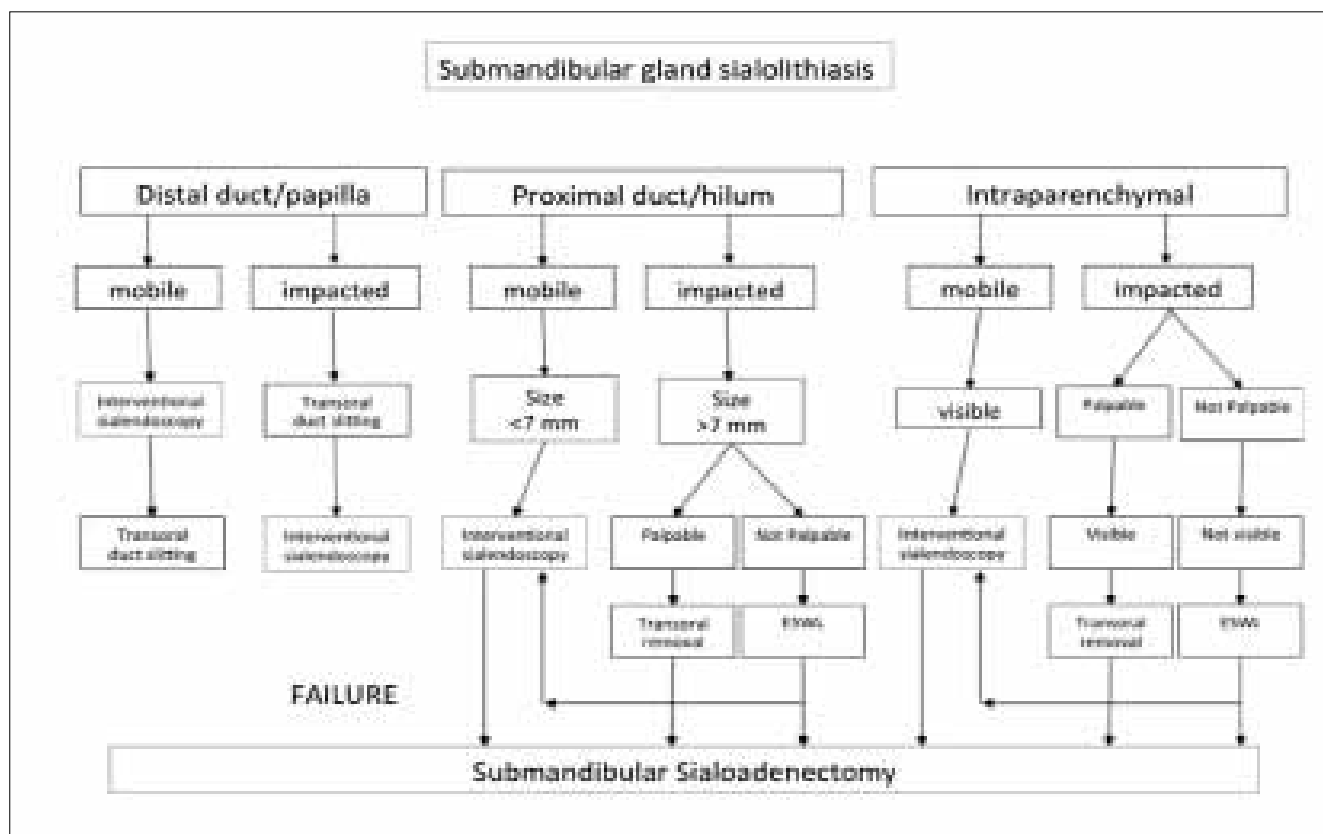


Fig. 4. Management of submandibular gland stones (from Koch et al. 2009²⁴, mod.).

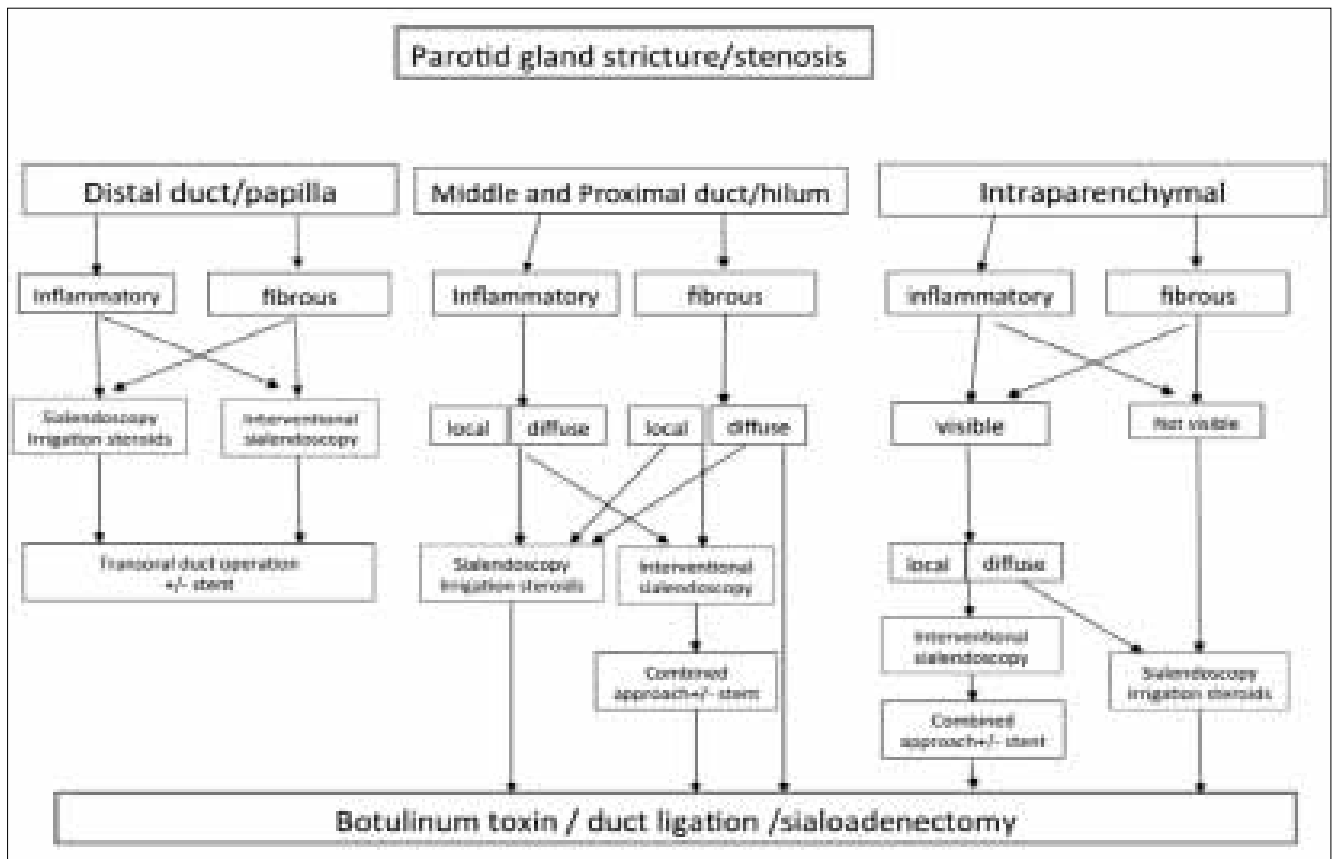


Fig. 5. Algorithm for management of parotid gland stricture/stenosis (from Koch et al., 2009²⁴, mod.).

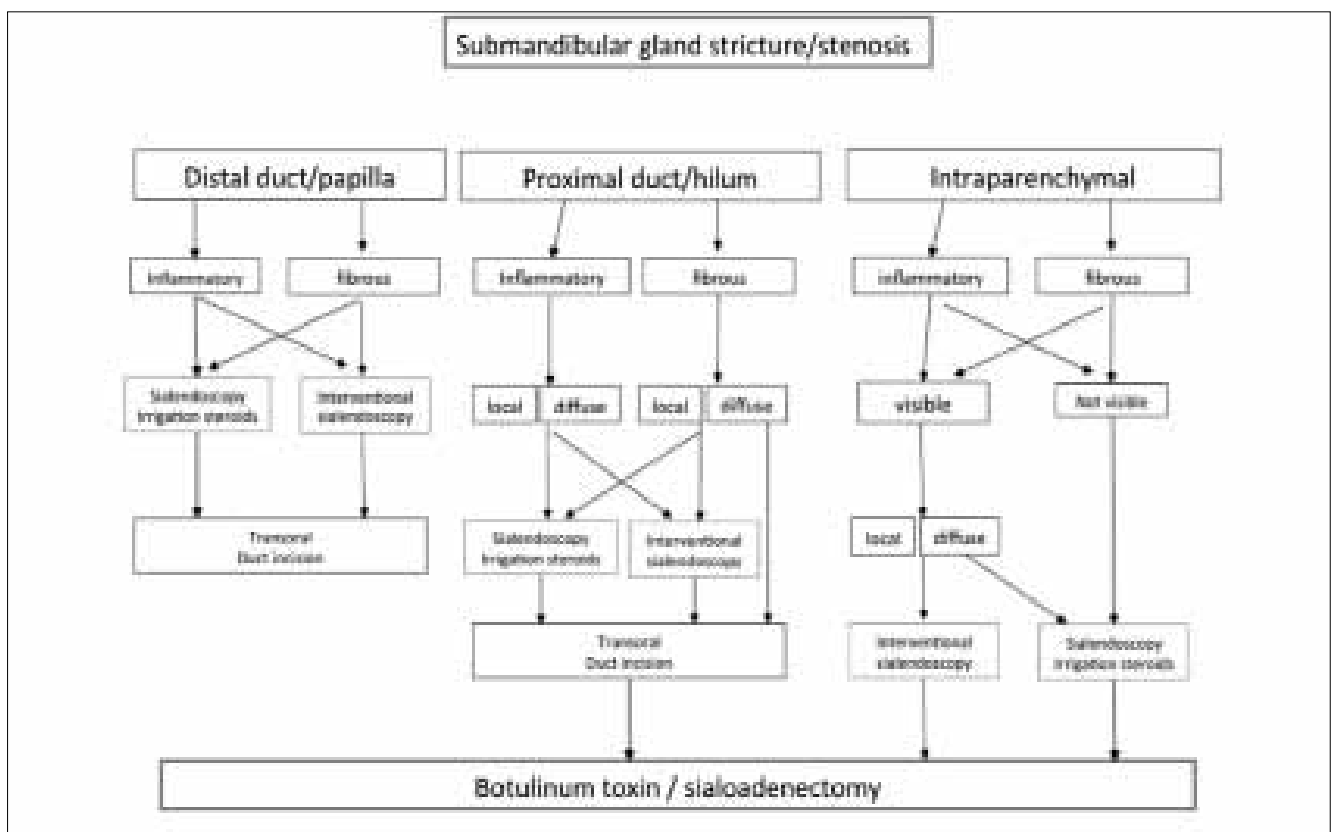


Fig. 6. Algorithm for management of submandibular stricture/stenosis (from Koch et al., 2009²⁴, mod.).

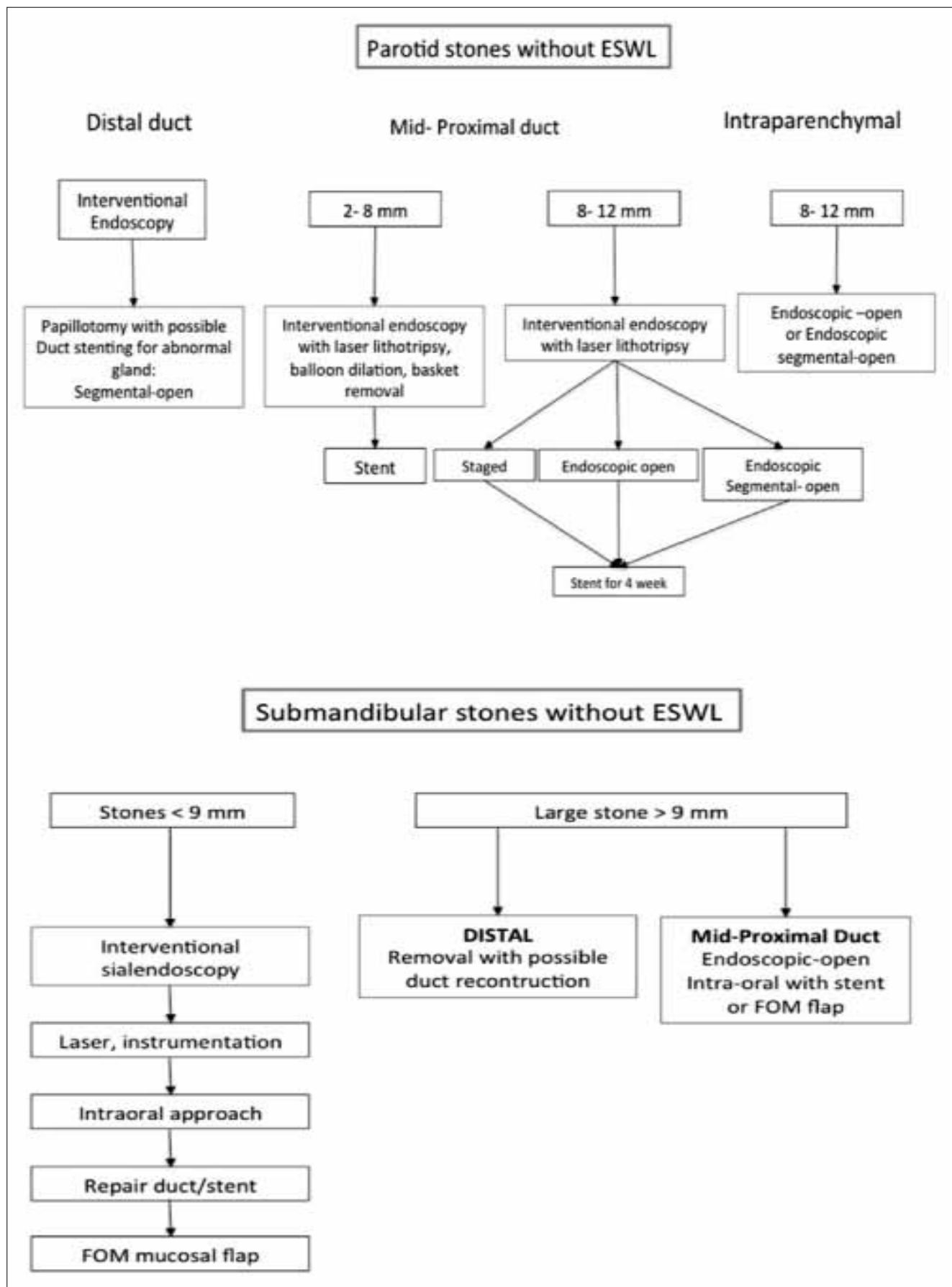


Fig. 7. Algorithm for treatment of salivary glands obstruction without ESWL (from Fritsch 2009²⁵, mod.).

The correct integration with therapeutic options such as laser lithotripsy or ESWL obviously depends on the technologies available. For these reasons, there are differences in stone treatment algorithms used by physicians who have access to ESWL and those who do not²⁵, mainly in terms of stone dimensions (Fig. 7).

Lithiasic pathology

Intracorporeal lithotripsy

Since the mid-1980s, much thought has been given to apply lithotripsy to salivary glands similarly to that used for urinary tract stones. It is well-known, in fact, that salivary gland function can recover after stone removal alone. With the introduction of sialoendoscopy, intracorporeal lithotripsy has been proposed as a promising alternative to ESWL^{35,36}. The limitation of the endoscopic approach without laser lithotripsy is usually considered the size of the stone, which allows removal of stones no more than 4 mm in diameter with a wire basket or grasping forceps, whereas larger stones or stones impacted in the duct require fragmentation^{36,37}.

Endoscopic laser lithotripsy has the potential to treat many stones larger than 4 mm with minimal complications and allows preservation of a functional salivary gland. This technique was introduced in the early 1990s when laser, electrohydraulic probes and pneumatic lithotripsy were tested^{30,31,38}. Due to possible adverse effects, such as facile duct perforation and surrounding tissue damage, it was soon clear that both intracorporeal electrohydraulic and pneumatic lithotripsy were not feasible procedures for salivary stone treatment. Therefore, many authors focused on the use of laser lithotripsy and further case series were published on the clinical use of different lasers^{9,28,32,39-44}. Currently, there is still no consensus as to which laser is the most efficient in performing lithotripsy on salivary stones, although most studies have reported Ho:YAG laser as the first choice.

Ho:YAG laser creates pulsed energy with a wave length of 2080 nm which is near the peak for absorption of water; lithotripsy is achieved by a photomechanic effect with a collision of the particles of the stone and then a photothermic effect on the surface level. This associates the fragmentation effect with vaporisation of the stone's surface. It creates a shockwave when the laser is activated and the tip of the fibre is placed perpendicular to the stone's surface. Lithotripsy is then activated by a cavitation/fragmentation technique until the stone is completely fragmented, and then washed out or retrieved with a basket or grasping forceps without damaging the epithelium of the duct. Extreme care is necessary to avoid pieces that are sharp enough to damage the walls of the duct or remain encased during retrieval and to avoid activating the laser when the tip is in contact with the duct wall. However, there are no reports about side effects due to laser lithotripsy in clinical practice^{18,19,28,32,39-44}.

Regardless of the type of laser used, intracorporeal lithotripsy overcomes the need for combined approaches or open interventions. The advantage of most lasers is that the fibres have small diameters, sometimes as small as 200 µm, allowing application of high-watt intensities for fragmentation of stones even in the proximal duct system or behind stenotic areas. Currently, the real limitations are represented by stones that are only partially visible due to the possible laser action to the ductal wall that may inadvertently cause perforation and by stones that are too large in size (> 15 mm) due to the excessive length of the procedure. Similarly, the hardness of stones can play an important role in fragmentation and, consequently, in the duration of the procedure¹⁹.

Extra-corporeal lithotripsy for salivary stones: indications and limitations

The experience acquired with ESWL techniques have been widely described in the literature^{34,35,45-55}. The shockwaves produced by an extra-corporeal source (electromagnetic or piezoelectric) have the aim of fragmenting stones so that they can be flushed out by physiological saliva flowing out the duct. ESWL is usually performed under US control, which allows stone identification and targeted administration of the shockwave with real-time visualisation of the fragmentation process and avoiding any iatrogenic lesions of surrounding tissue.

The most frequently used ESWL energy source is electromagnetic as it is minimally invasive and can be used on an outpatient basis without anaesthesia. It was introduced in the 1980s for the treatment of renal calculi and gallstones. Electromagnetic and piezoelectric sources exploit the compressive and expansive waves generated by the difference in impedance at the stone-water interface and cause stone cavitation. After encouraging results with multiple animal and in vitro experiments, the first successful ESWL for human sialolithiasis was carried out by Iro et al. in 1989 using a device designed for renal lithotripsy⁴⁸. Since then, dedicated instruments have been designed and the use of ESWL has become increasingly widespread.

Ultrasonography is used to focus the shockwaves on the stone. Stones that can be identified ultrasonographically and have a diameter of at least 2.4 mm (diameter of the focus) are potentially amenable to treatment. Contraindications for ESWL are complete distal duct stenosis, pregnancy, and the presence of a cardiac pacemaker. Relative contraindications include acute sialadenitis or other acute inflammatory processes of the head and neck and treatment should be postponed in these cases. ESWL is considered safe, and only minor and self-limiting undesired effects have generally been reported, including pain of the treated area, glandular swelling, ductal bleeding and cutaneous petechiae.

As for the effectiveness of electromagnetic ESWL of salivary stones, it is quite difficult to compare published

results directly due to differences in criteria used to define outcomes: definition of complete or partial success (< 2 mm and > 2 mm), or symptom status after lithotripsy. On the basis of the published findings, the success rate is higher in parotid stones than in submandibular stones: complete stone clearance has been reported in 39-69% of parotid stones, but only 26-42% of submandibular stones treated electromagnetically, and respectively, 33-81% and 29-40% of those treated piezoelectrically. Moreover, multivariate analysis of one of the previous studies showed that favourable outcomes were significantly associated with a younger age (< 46 years), parotid location (intraductal), stone diameter (< 7 mm) and a lower number of therapeutic sessions^{35,54}. However, despite the availability of specific indications for ESWL, US shows that a significant number of patients still have residual fragments in the affected gland, although most are asymptomatic and do not require additional procedures. It is well known that ultrasound is not accurate in stones with a diameter less than 1.5 mm. Consequently, the undetectable microliths (consequence of ESWL) can act as a nidus for recurrence; this is why, nowadays, ESWL is proposed in combination with interventional sialoendoscopy to verify and obtain cleansing of the salivary duct system⁵⁵.

In conclusion, the main indication of ESWL is for parotid calculi, but it can still be chosen for selected submandibular stones such as impalpable pure intraparenchymal ones as an alternative to sialadenectomy. The main limitations are the need for multiple sessions and the fact that residual stone fragments inside the duct system may require a multimodal approach (together with interventional sialoendoscopy and sialoendoscopy-assisted surgical removal) in some patients.

Combined approach to submandibular and parotid gland for calculi

Clinical experience with ESWL has shown that this technique is successful for most parotid stones. However, submandibular stones, in particular large stones (> 7 mm) and those in the hiloparenchymal region, are not responsive to this type of treatment³⁵. Sialoendoscopy is an adequate procedure for all mobile stones and for small (< 5 mm) stones of the submandibular and parotid duct system^{9,56,57}. About 10% of patients with parotid stones treated with ESWL and sialoendoscopy remain symptomatic and require further treatment⁵⁸. In recent years, an endoscope-assisted surgical approach has been proposed for the management of proximal duct and intraparenchymal stones of the submandibular gland and for large, palpable and fixed stones of the parotid gland^{27,59-67}.

An intraoral approach for submandibular stones, well known since 1968, has emerged as the primary treatment modality in the last 15 years. The results of experience acquired in dedicated centres show that successful stone retrieval may be achieved in the majority of patients if

adequate preoperative assessment delineating the position and size of the stone is performed (manual palpation of the stone in the oral floor and ultrasound). In particular, ultrasonography is able to distinguish the position of the stone in the main duct and the hiloparenchymal region. The sialoendoscopic inspection of the duct system is extremely useful in guiding the surgeon during the search for deep intraparenchymal stones or to check the hilar cavity after the removal of the main stone for any residual sialoliths. The surgical procedure is preferably performed under general anaesthesia. A low rate of complications has been encountered, mainly represented by persistent or transitory lingual nerve damage, hilar stenosis and ranula^{27,59-67}. The few failures are limited to patients with non-palpable intraparenchymal calculi adherent to gland tissue⁶³. A relatively low number of symptomatic recurrence of calculi (16.3%) have been observed, in particular in patients who previously underwent ESWL; in these patients, secondary or tertiary minimally invasive procedures such as ESWL and interventional sialoendoscopy can be proposed to reduce the indication to traditional sialadenectomy⁶³.

A sialoendoscopy-assisted surgical approach for symptomatic parotid calculi has recently been described^{60-62,65}. Indications include large, palpable, fixed, duct and parenchymal stones, calculi not responding to minimally invasive approaches (ESWL or interventional sialoendoscopy) and strictures of SD that can impede stone removal by a minimally invasive approach⁵⁸. Two stone removal options are available: the modified rhynchotomy approach under general anaesthesia and facial nerve monitoring, and the cheek approach through a direct cutaneous incision over the palpable and superficial stone under local anaesthesia. In the former procedure, a parotid sialodrain is usually inserted along the duct after its incision to favour the release of the stone, and the parotid duct is sutured with 6/0 suture while the stent is sutured to the oral mucosa. A retrograde sialoendoscopic check with saline lavage is performed in both procedures to exclude any additional calculi. No facial nerve damage has been described after these surgical approaches, although a low number of sialoceles, stenosis and salivary fistula have been reported. Based on the experience of five major centres, a successful result is achieved in most of patients suggesting that an endoscope-assisted surgical approach to parotid calculi is a viable alternative to traditional parotidectomy.

Non-lithiasic pathologies

Autoimmune disorders of the major salivary glands

Autoimmune disorders of the major salivary glands can be divided in two categories. A first group includes the IgG4-correlated sclerosing disease (MS IgG4), such as Mikulicz Syndrome, Kuttner tumour and chronic sclerosing sialoadenitis, and another group including Sjögren's syndrome.

The aetiology of MS IgG4 is unknown, but it has an auto-immune pathogenesis with connective tissue invasion by T CD4+ lymphocytes, T CD8+ lymphocytes and IgG4-producing plasma cells. The salivary glands involved progressively reduce saliva production thus tending to cause stasis within the ducts due to stenosis and/or extraordinary dilatation induced by surrounding fibrosis. Sialolithiasis formation is frequent. Until recently, sialoendoscopies have not been described in these patients, and systemic steroids represent elective therapy^{68,69}.

In Sjögren's syndrome, 80% of the immune response is represented by CD4+ T lymphocytes; there is also a significant presence of interleukin and antibody production. The disease attacks the ducts of all exocrine glands including the salivary glands⁷⁰. Bilateral gland swelling is often present causing duct obstruction due to lymphocytic inflammatory infiltrates. Swelling is typically recurrent with complete remission intervals. Pain is moderate and increases during chewing. Sometimes gland swelling is absent, and various hypotheses have thus been proposed to explain the xerostomy (which is always present): these include gland damage and neuron degeneration consequent to vasculitis and neuron transmission inhibition by antimuscarinic antibodies⁷¹. Autoantibodies may be present in the blood, although they are not specific for Sjögren's syndrome. At sialoendoscopy, the involved glands express, at the main and secondary duct levels, wall hyperaemia with a marked vascular reticule showing perivascular inflammation and congestion. Later, with progression of the substitute sclerosis of parenchymal tissue, the ducts seem pale and poorly vascularised. Mucous plugs are often present within the duct lumen and eventually obstruct the ducts partially or completely with saliva stasis and inflammation where the obstruction begins, causing temporary gland swelling and pain⁷².

Juvenile recurrent parotitis

Juvenile recurrent parotitis (JRP) is the second most common disease of the parotid gland after mumps in children. It typically occurs between 3 and 6 years of age, more frequently in males and in most cases shows self-restraint at puberty. JRP is a non-specific sialoadenitis characterised by a non-obstructive, non-suppurative inflammatory process with acute episodes of unilateral (less frequently bilateral) parotid swelling and pain, lasting between few days and a couple of weeks, interspersed by varying disease-free periods. The aetiology of JRP remains unclear⁷³. The sialographic demonstration of duct ectasis combined with an accurate clinical and symptomatological evaluation still represents the diagnostic hallmark of JRP. Sialectasis is demonstrated by multiple radio-opaque dye among dilated interlobular ducts, typically detected in both parotids even when swelling is limited to one side, and the severity of which is not correlated with the clinical course of disease. Sialectasies tend to disappear after ado-

lescence. Moreover, sialography may have a therapeutic effect due to the irrigation of ductal system (free-radicals flushing), and the action of antiseptic iodine into the ducts may be helpful in healing⁷⁴.

With the improvement of less-invasive imaging techniques, such as CT, US and MRI, diagnostic approaches different from sialography are available.

The first-line treatments of acute swelling episodes usually consist of the association of analgesics, anti-inflammatory drugs and antibiotics. Sialagogues and gland massages remain useful additional therapy. Corticosteroids are indicated in severe forms.

In the last few years, there are many reports on the striking role of sialoendoscopy in diagnosis and treatment of JRP. Recently, some authors have demonstrated that sialoendoscopic diagnosis is as significant as that made with conventional imaging. Furthermore, sialoendoscopic examination allows detecting characteristics of JRP that might be difficult to observe with US or other imaging techniques, such as the lack of natural vascularisation of the ductal wall⁷⁵⁻⁷⁸. Finally, a recent work of Ardekian et al. evaluating a sample of 50 children affected by JRP showed a statistically significant correlation between sialoendoscopic findings and clinical outcome, also validating the sialoendoscopy as an effective treatment for this condition⁷⁹. Sialoendoscopy, in fact, may break the cycle of ductal inflammation by washing out intraductal debris and dilating the stenosis⁷⁵⁻⁷⁹.

Recurrent parotitis and masticatory disorders

Masseter muscle hypertrophy (MH), also referred to as benign or idiopathic masseter hypertrophy, may play a role in the aetiology of recurrent obstructive parotitis. The aetiology of MH is still unknown, but several authors claim that emotional stress results in chronic overuse of the jaws due to clenching, bruxism, constant chewing, or temporomandibular joint disorder^{80,81}.

A relationship between parotitis and masseter hypertrophy has been recently described. In particular, Reddy et al. showed three cases of chronic parotitis secondary to an acute bend in SD caused by an enlargement of the masseteric space⁸².

The diagnosis of this concomitant condition is made on clinical signs, imaging and sialoendoscopic findings⁸⁰⁻⁸². Patients typically show recurrent unilateral swelling of the face during meals, mastication with unilateral or bilateral tenderness, enlargement of the masseter muscles and dental wear facets consistent with bruxism. CT or cone beam 3D CT can be useful to detect bone abnormalities secondary to MH and to check for temporo-mandibular joints. Conventional MR and MR-sialography can be done to depict the relationship between the involved parotid gland, muscle hypertrophy and ductal dilation secondary to ab estrinsec compression of masseter muscles. Finally, electromyographic evaluation of masticatory

muscles can be done to evaluate muscular activities⁸¹. Diagnostic sialoendoscopy may be helpful to detect typical kinkings or acute angles of SD due to external muscle compression^{9,77}.

The treatment of this condition is usually multimodal and should consider the management of both conditions, namely MH and parotitis. Non-surgical therapy includes reassurance, muscle relaxants, injection of botulinum toxin type A, dental restorations and occlusal adjustments and nightly bite guard use⁸¹. Surgical management includes an intraoral approach with reduction of deep masseter muscle and monocortical and bicortical ostectomy of the angle of the mandible.

Management of recurrent parotitis is based on interventional sialoendoscopy of the parotid glands with dilation and irrigation of the duct system with saline and steroid solution^{9,82}. Concomitant injections of botulinum toxin type A in the masseter muscle and parotid gland have been proposed to obtain functional silencing of the parotid gland and relaxation of masseter muscles⁹.

Diagnosis of recurrent obstructive parotitis secondary to masseteric hypertrophy should be done every time diagnostic sialoendoscopy does not reveal intraluminal causes of obstruction but only duct kinkings, and clinical evaluation of the cheek reveals tenderness and enlargement of masseter muscles. In this case, an orthodontic diagnostic and therapeutic work-up should be planned to facilitate clinical recovery.

Radioiodine sialadenitis

Thyroid gland cancer management with radioactive iodine (¹³¹I) has led to the development of salivary gland injuries specifically related to the harmful effects of the radioisotope. According to the literature, up to 69% of post-radioiodine salivary dysfunction and more than 25% of radioiodine sialadenitis is present at 12 months after treatment⁸³⁻⁸⁵.

Salivary gland tissues express the ability to concentrate iodine due to a sodium/iodide symporter placed in parenchymal and, prevalent mostly, in ductal cells. It has been assessed that the salivary iodine concentration ranges from 20 to 100 times the level detected in plasma and up to 24% of administered ¹³¹I is secreted into the saliva. Therefore, the salivary glands become a potential collateral target of radioactive iodine therapy, and obstructive sialadenitis is usually the first gland effects due to irradiation. Moreover, the vascular endothelium of salivary glands results in increased permeability because of ¹³¹I damage, leading to leakage of plasma proteins and electrolytes.

Since serous glands, and especially the excretory ductal system, are more frequently involved than mucous glands, radioiodine sialadenitis may be mainly defined as a ductal disease of the parotid gland.

As a physiopathological consequence of ¹³¹I exposure, the pivotal processes may be resumed as follows⁸⁶:

- a. Ductal obstruction secondary to periductal inflammation and an inflammatory infiltrate;
- b. Ascending gland infections related to the reduced ability to drain saliva;
- c. Radioisotope diffusion into salivary gland parenchyma and biochemical salivary changes by through increased capillary permeability.

The overall described mechanisms determine salivary flow decrease, stagnation and mucus precipitation with mucous plugs formation. Furthermore, they trigger an inflammatory vicious circle that upgrades ¹³¹I retention. Recurrent inflammatory and/or infectious events may result in chronic gland sclerosis. Pain, swelling, distorted taste perception and subsequent xerostomia are common symptoms. Clinical presentation, essentially obstructive in nature with bilateral predominance, may occur early (within the first 48 hours after irradiation) or late at 3-6 months from the beginning of ¹³¹I treatment^{85,86}.

Historically, treatment of ¹³¹I sialadenitis included sialogogic agents followed by gland massages, heat, steroids, adequate daily fluid intake, mouthwashes, duct probing and antibiotics. According to Kim et al., the benefits perceived from conservative therapies have been estimated in no more than 71% of patients treated with ¹³¹I⁸⁵. Up to now, recalcitrant sialadenitis may only be submitted to adenectomy as the sole option available after failure of medical therapy.

In 2006, Nahlieli et al. published encouraging results concerning a novel employment of salivary gland videoendoscopy in 15 patients with radioiodine sialadenitis⁸⁷. Since then, three other international experiences have reported on the added advantages of sialoendoscopy as a minimally invasive procedure for both diagnostic and therapeutic purposes⁸³⁻⁸⁵.

Results

Sialoendoscopy: analysis of outcomes

Many international experiences have reported on the effectiveness and safety of sialoendoscopy in both adult and paediatric patients^{14,73,77,78}. Herein, sialoendoscopic outcomes will be discussed with particular focus on the main causes of benign salivary duct obstructions.

Salivary stones

Sialolithiasis is undoubtedly the most frequent area of application, used in 60-70% of all sialoendoscopic treatments²⁴. In particular, video-endoscopic findings stress not only the interventional aspects, but also the diagnostic role of sialoendoscopy. Assessment of undiagnosed recurrent obstructive symptoms with sialoendoscopy reinforce that it is an additional tool that can fill the diagnostic gap between clinical suspicion and instrumental investigation⁸⁸. A monocentric retrospective study reviewed the results on 1154 patients submitted to sialoendoscopy after US⁸⁹. Provisional US diagnosis of salivary stones was ex-

cluded by video-endoscopy in 21% of parotid glands and in 7% of submandibular glands. Nahlieli et al. focused on the diagnostic gain produced by sialoendoscopy in 236 cases: stones were revealed only after sialoendoscopy in 63% of parotid glands and in 32% of submandibular glands⁹⁰. These findings have led some authors to reconsider the epidemiology of traditional salivary stones because of the relatively high percentage of US misdiagnosis involving parotid glands³⁶.

The working channel of salivary endoscopes allows both diagnostic and therapeutic operations, and there are many publications that have documented high success rates. A systematic review and meta-analysis searched all articles published since October 2010⁷⁷. Sialoendoscopy alone provided a success rate (symptom-free percentage) of 86% in 1213 patients (19 publications) which increased to 93% in 374 patients when sialoendoscopy was performed with a combined surgical approach (11 publications). Combined external surgical approaches comprised small or large transoral incisions and preauricular skin flaps. Salivary gland adenectomy was required in 0-11% of cases. Despite the meticulous work of the meta-analysis, the Authors considered that the main weakness of their study was due to the large heterogeneity of the articles included. More specifically, the results not only involved treatment of salivary stones, but also other causes of obstruction (e.g. ductal strictures or polyps) mixing both parotid and submandibular glands. Therefore, the pooled percentage of success may be considered susceptible to variation compared with "true outcomes".

A multicentre international observational study lasting 14 years on 4691 patients with sialolithiasis did not meet the selection criteria of the above meta-analysis. In fact, first-line treatments included not only sialoendoscopy, but also extracorporeal shockwave lithotripsy or stones removal under fluoroscopic/radiographic guidance⁵⁵. The overall success rate was 80.5% (complete calculi removal) and 16.7% (partial calculi removal) with an incidence of sialadenectomy of 2.9%. Appropriate patient selection allows high success rates and reduces adverse events: the size, site, shape and orientation of salivary stones strictly correlates with the probability of successful endoscopic stone removal^{23,91,92}.

Salivary duct anomalies

Strictures, polyps, kinks and foreign bodies are considered the second most frequent cause of benign salivary duct obstruction⁹³. Several miniaturised devices coupled with a sialoendoscope may be adopted to address these obstructive disorders such as balloons, grasping forceps and stents. As previously reported, no systematic review has been published on outcomes in salivary duct anomalies other than sialolithiasis. Ardekian et al. retrospectively analysed sialoendoscopic outcomes in 335 glands and found 87 cases of strictures⁹⁴. Sialoendoscopy was successful in 81.7% of the affected parotid glands with

similar results to Nahlieli O. who documented a success rate of 80-81% for strictures and 100% for kinks^{7,94}.

Radioiodine sialadenitis

Three studies (33 patients) were included in the meta-analysis by Strychowsky's^{77,84,87}. The percentage of patients with complete resolution of symptoms ranged from 50-100%, with no major complications reported. One noteworthy finding is the high rate of inability (50% of cases) to cannulate gland ducts reported by Kim et al.⁸⁴ Salivary gland excision was only described by Prendes's experience in 9% of patients⁸³.

Juvenile recurrent parotitis

Updated to August 2013, a recent work overviewed the existing literature concerning sialoendoscopic outcomes in patients suffering from JRP⁷³. Despite the limits of the included studies (level of evidence 4, relatively small population, absence of long-term follow-up), the high success rate achieved (symptom free: 78%, partial regression: 22%) support the positive role of sialoendoscopy in prevention of recurrent attacks. International experiences have also confirmed the diagnostic benefits of sialoendoscopy, since direct endoscopic exploration allows for differential diagnosis among dissimilar causes of obstruction^{79,95}.

Autoimmune sialadenitis

Currently, a limited amount of information is available on salivary gland videoendoscopy in patients with autoimmune sialadenitis, and additional evidence is needed⁷².

Contraindications and management of complications

Sialoendoscopy has few contraindications, and in almost all cases it is possible to perform the endoscopic procedure. From a review of the literature, an exclusive endoscopic procedure is contraindicated in acute sialoadenitis, complete distal duct stenosis, symptomatic intraparenchymal stone and limited mouth opening, even if the latter is a contraindication mainly in a combined endoscopically/external or intraoral approach^{14,22,23,27,37,59,93}.

Complications in an exclusive endoscopic approach are rare, and most are minor: even temporary glandular swelling, routinely present in almost all procedures (88%)^{14,22,23}, is mainly considered a correlated effect rather than a true complication. The most frequent complications in an endoscopic approach are post-operative duct strictures, laceration of the duct (including device blocks or rupture) and infection²³.

Iatrogenic post-operative ductal stricture are not so common: they are less than 2% and in most cases is related to stone removal > 5 mm^{41,42,56}. Laceration of the duct is present in about 5% of cases^{27,44}, but long term salivary fistula is rarely related with laceration¹⁴. Papilla infection is quite common, seen in around 23% of patients, while

glandular infection is relatively infrequent (2.5%)^{14 93}. The breaking and blocking of endoscopic tools inside the duct is another possible complication, which is only rarely reported. It does not appear to be a major concern, as in all reported cases except one endoscopic removal of the instrument was possible. Complications are related to the duration of the procedure: longer procedures are associated with an increase rate in side effects^{14 89 90 96}.

As for a combined or external approach, the most frequent complications are pain of the floor of the mouth (8%)²⁷, temporary lingual nerve paresthesia (4%)⁹⁶, ranula formation (3%)^{65 96} and definitive lingual nerve palsy (< 1%)⁶⁵. Considering the combined approach, the rate of complications such as fistula or duct stenosis/laceration^{14 27} is not significantly higher than in the endoscopic group. The only different complication is temporary or definitive palsy of the lingual nerve^{27 59 96}, for which only medical treatment is required. Other related complications such as swelling of the floor of the mouth and ranulas are seen in less than 1% of cases, and no treatment is required⁶⁵.

Complications after sialoendoscopy usually resolve spontaneously: post-operative gland swelling shows complete recovery usually after few days (1-4)²³, except in rare cases of duct or hilar fistula in which compressive medication or botulinum treatment is needed. Post-operative duct stricture requires medical treatment, after which a second endoscopic approach may be necessary with duct dilatation and/or sialo-stent positioning^{14 22 77}.

In conclusion, sialoendoscopy (both endoscopic and combined approach) has a low rate of complications and side effects, which in most cases are easy to manage. At centres where the salivary endoscopy is performed, sialoadenectomies for obstructive pathologies are needed in less than 10% of all cases.

Conclusions

Is sialadenectomy still indicated in obstructive salivary pathologies?

Sialoadenectomy, while remaining the gold standard for salivary gland neoplasms, has greatly reduced its role in cases of obstructive diseases due to the introduction of interventional sialoendoscopy. Nevertheless, sialoadenectomy continues to have a role in all cases where, due to the size, location and number of stones or due to irreversible pathological conditions of the gland (massive fibrosis, multiple stenoses, chronic sialadenitis), an endoscopic technique may not lead to satisfactory results or does not prevent the appearance of relapses.

A limitation of sialoendoscopy alone, taking into account the size of stones, is the difficulty in removing stones with a diameter > 4 mm¹⁴. This constraint has been overcome through the use of lithotripsy achieved by different types of intracorporeal lasers or by extracorporeal shock waves⁹⁷.

These techniques are time consuming and not readily avail-

able in all centres. Its best success rates up range from 75% for the parotid to 40% for the submandibular gland^{35 46} and seem similar for both external and intraductal lithotripsy⁹⁸. On the other hand, holmium:YAG, and to a lesser degree thulium:YAG¹⁵ laser fibres, may inadvertently cause damage to duct walls²³ while dye laser at 350 nm which are absorbed by the tissues are still expensive⁶².

Marchal, in his cases series of interventional sialoendoscopy with laser fragmentation, reported 20% of failures due to large stones (6 mm or larger) and stenotic ducts, particularly in the parotid gland. In these cases, sialoadenectomy can be used to treat such failures²³.

The introduction by Nahlieli⁶⁵ of a combined technique for removal of stones, which consists in locating the stone endoscopically and extracting it with a minimally invasive technique, has further reduced the number of cases in which sialoadenectomy is necessary.

However, Marchal, in a selected case series of combined procedures, had to remove the submandibular gland shortly afterwards in 28% (8 of 29) of patients for postoperative closure of the mucosa of the floor of the mouth leading to continuous swelling of the submandibular gland after an initial period of remission. In the same series, failures of the combined technique for parotid obstructions were due to polycystic ductal disease and mega SD⁶².

Giant salivary stones (≥ 15 mm) can be treated using a combined technique, although in some cases (from 14% to 43%) they require sialoadenectomy⁹⁹.

Zenk et al. conducted a case series of 1033 patients with sialolithiasis, the largest up to date, using transoral removal or endoscopy alone, respectively, in 92 and 5% of submandibular lithiasis with long-term success rates of $\geq 90\%$. Parotid stones were removed by salivary gland endoscopy (22%), combined endoscopy with an incisional technique (26%), or ESWL (52%), with long-term success rates of 98%, 89% and 79%, respectively. Submandibular or parotid glands had to be removed in 5% of cases⁸⁹. Similar gland excision rates (from 0 to 9%) are reported in recent literature¹⁰⁰.

Taking into account the location of the stones, another limitation of sialoendoscopy alone can be the difficulty in removing stones located in second and third ductal divisions, where combined approaches are not always efficient (in these cases the use of thulium laser lithotripsy may offer better results) or after an acute bend in the main duct⁴⁴.

Lastly, a contraindication for sialoendoscopy, and thus an indication for sialoadenectomy, is complete distal obliteration of the duct that is impenetrable by the endoscope which can occur in patients with a long-standing history of recurrent inflammations that leads to the impaction of the sialolith to the wall of the efferent duct^{14 100}.

In conclusion, sialoadenectomy should be considered in cases of failures of transoral removal of hilar stones > 7 mm or failures after an extra-corporeal shock-wave lithotripsy for an intraparenchymal stone in the submandibular gland¹⁴.

Sialoendoscopy is a relatively new procedure, but in the last few years it has rapidly spread worldwide. Although it was first described as an alternative procedure for salivary stone removal, it is now considered as the treatment of choice for obstructive pathologies of the salivary ductal system. Its popularity is continuously growing because it represents a relatively simple procedure and since the last decade most otolaryngologists have become experienced in different areas of endoscopic surgery. Moreover, the basic equipment, although fragile, does not represent an excessively expensive tool in the era of minimally invasive surgery.

Sialoendoscopic procedures, in addition to combined minimally invasive external or transoral approaches, have now drastically reduced the indication for salivary gland removal.

Even in the field of research, sialoendoscopy seems to offer a new perspective in the medical treatment of some emerging neurologic and autoimmune diseases usually presenting quantitative and/or qualitative alterations of saliva such as sialorrhoea and xerostomia. The increasing number of studies on sialoendoscopy emerging from analysis of the literature in this review confirm the rising interest of otolaryngologists in this new field of research and treatment modality.

References

- 1 Katz P. *Endoscopy of the salivary glands*. Ann Radiol 1991;34:110-3.
- 2 Horsburgh A, Massoud TF. *The role of salivary duct morphology in the aetiology of sialadenitis: statistical analysis of sialographic features*. Int J Oral Maxillofac Surg 2013;42:124-8.
- 3 Zenk J, Hosemann WG, Iro H. *Diameters of the main excretory ducts of the adult human submandibular and parotid gland: a histologic study*. Oral Surg Oral Med Oral Pathol Oral Radiol Endod 1998;85:576-80.
- 4 Kang HC, Kwak HH, Hu KS, et al. *An anatomical study of the buccinator muscle fibres that extend to the terminal portion of the parotid duct, and their functional roles in salivary secretion*. J Anat 2006;208:601-7.
- 5 Amano K, Moriyama H, Shimada K, et al. *Study of human adult parotid duct in the area of penetration through buccinator muscle and their functional relationship as a sphincter*. Ital J Anat Embryol 2013;118:6-18.
- 6 Drage NA, Wilson RF, McGurk M. *The genu of the submandibular duct: is the angle significant in salivary gland disease?* Dentomaxillofac Radiol 2002;31:15-8.
- 7 Nahlieli O, Shacham R, Yoffe B, et al. *Diagnosis and treatment of strictures and kinks in salivary gland ducts*. J Oral Maxillofac Surg 2001;59:484-90.
- 8 Zhang L, Xu H, Cai ZG, et al. *Clinical and anatomic study on the ducts of the submandibular and sublingual glands*. J Oral Maxillofac Surg 2010;68:606-10.
- 9 Marchal F, Becker M, Dulguerov, et al. *Interventional sialoendoscopy*. Laryngoscope 2000;110:318-20.
- 10 Chossegros C, Guyot L, Richard O, et al. *A technical improvement in sialoendoscopy to enter the salivary ducts*. Laryngoscope 2006;116:842-4.
- 11 Nahlieli O, Shacham R, Bar T, et al. *Endoscopic mechanical retrieval of sialoliths*. Oral Surg Oral Med Oral Pathol Oral Radiol Endod 2003;95:396-402.
- 12 Lari N, Chossegros C, Thierry G, et al. *Sialoendoscopy of the salivary glands*. Rev Stomatol Chir Maxillofac 2008;109:167-71.
- 13 Nahlieli O, Baruchin AM. *Sialoendoscopy: three years' experience as a diagnostic and treatment modality*. J Oral Maxillofac Surg 1997;55:912-8.
- 14 Capaccio P, Torretta S, Ottaviani F, et al. *Modern management of obstructive salivary diseases*. Acta Otorhinolaryngol Ital 2007;27:161-72.
- 15 Faure F, Boem A, Taffin C, et al. *Diagnostic and interventional sialoendoscopy*. Rev Stomatol Chir Maxillofac 2005;106:250-2.
- 16 Luers JC, Damm M, Klussmann JP, et al. *The learning curve of sialoendoscopy with modular sialoscopes: a single surgeon's experience*. Arch Otolaryngol Head Neck Surg 2010;136:762-5.
- 17 Vairel B, De Bonnecaze G, Al Shehri S, et al. *Courbe d'apprentissage en sialoendoscopie: nos 101 premières procédures*. Rev Laryngol Otol Rhinol 2012;133:177-81.
- 18 Maresh A, Kutler DI, Kacker A. *Sialoendoscopy in the diagnosis and management of obstructive sialadenitis*. Laryngoscope 2011;121:495-500.
- 19 Kroll T, Finkensieper M, Hauk H, et al. *Sialoendoscopy-learning curve and nation-wide survey in German ENT-departments*. Laryngorhinootologie 2012;91:561-5.
- 20 Modest MC, Galinat L, Rabinowitz MR, et al. *Learning progression in the use of sialoendoscopy for sialolithiasis: effect on gland preservation*. Otolaryngol Head Neck Surg 2014;151:240-5.
- 21 Marchal F, Chossegros C, Faure F, et al. *Salivary stones and stenosis. A comprehensive classification*. Rev Stomatol Chir Maxillofac 2008;109:223-6.
- 22 McGurk M, Escudier MP, Brown JE. *Modern management of salivary calculi*. Br J Surg 2005;92:107-12.
- 23 Marchal F, Dulguerov P. *Sialolithiasis management: the state of the art*. Arch Otolaryngol Head Neck Surg 2003;129:951-6.
- 24 Koch M, Zenk J, Iro H. *Algorithms for treatment of salivary gland obstructions*. Otolaryngol Clin North Am 2009;42:1173-92.
- 25 Fritsch MH. *Algorithms for treatment of salivary gland obstructions without access to extracorporeal lithotripsy*. Otolaryngol Clin North Am 2009;42:1193-7.
- 26 Foletti JM, Chossegros C, Salles F, et al. *Transoral approach for Stensen's duct lithiasis*. Laryngoscope 2011;121:1893-5.
- 27 Capaccio P, Bottero A, Pompilio M, et al. *Conservative transoral removal of hilar submandibular salivary calculi*. Laryngoscope 2005;115:750-2.
- 28 Ito H, Baba S. *Pulsed dye laser lithotripsy of submandibular gland salivary calculus*. J laryngol Otol 1996;110:218-21.
- 29 Konigsberger R, Freyh J, Goetz A, et al. *Endoscopically-controlled electrohydraulic intracorporeal shock wave lithotripsy (EISL) of salivary stones*. J Otolaryngol 1993;22:12-3.

- ³⁰ Iro H, Zenk J, Hosemann WG, et al. *Electrohydraulic intracorporeal lithotripsy of salivary calculi. In vitro and in animal experimented studies.* HNO 1993;41:389-95.
- ³¹ Iro H, Benzel W, Gode U, et al. *Pneumatic intracorporeal lithotripsy of salivary calculi. In vitro and in animal experimented studies.* HNO 1995;43:172-6.
- ³² Arzoz E, Santiago A, Esnal F, et al. *Endoscopic intracorporeal lithotripsy for sialolithiasis.* J Oral Maxillofac surg 1996;54:847-50.
- ³³ Ottaviani F, Capaccio P, Rivolta R, et al. *Salivary gland stones: US evaluation in shock wave lithotripsy.* Radiology 1997;204:437-41.
- ³⁴ Iro H, Zenk J, Waldfahrer F, et al. *Extracorporeal shock wave lithotripsy of parotid stones. Results of a prospective clinical trial.* Ann Otol Rhinol Laryngol 1998;107:860-4.
- ³⁵ Capaccio P, Ottaviani F, Manzo R, et al. *Extracorporeal lithotripsy for salivary calculi: a long-term clinical experience.* Laryngoscope 2004;114:1069-73.
- ³⁶ Nahlieli O, Baruchin AM. *Endoscopic technique for the diagnosis and treatment of obstructive salivary gland diseases.* J Oral Maxillofac Surg 1999;57:1394-402.
- ³⁷ Marchal F, Dulguerov P, Becker M, et al. *Specificity of parotid sialoendoscopy.* Laryngoscope 2001;111:264-71.
- ³⁸ Gundlach P, Scherer H, Hopf J, et al. *Endoscopic-controlled laser lithotripsy of salivary calculi: in vitro studies and initial clinical use.* HNO 1990;38:247-50.
- ³⁹ Iro H, Zenk J, Benzel W. *Laser lithotripsy of salivary duct stones.* Adv Otorhinolaryngol 1995;49:148-52.
- ⁴⁰ Kerr PD, Krahn H, Brodovsky D. *Endoscopic laser lithotripsy of a proximal parotid duct calculus.* J Otolaryngol 2001;30:129-30.
- ⁴¹ Martellucci S, Pagliuca G, de Vincentiis M, et al. *Ho:Yag laser for sialolithiasis of Wharton's duct.* Otolaryngol Head Neck Surg 2013;148:775-7.
- ⁴² Sionis S, Caria RA, Trucas M, et al. *Sialoendoscopy with and without holmium:YAG laser-assisted lithotripsy in the management of obstructive sialadenitis of major salivary glands.* Br J Oral Maxillofac Surg 2014;52:58-62.
- ⁴³ Raif J, Vardi M, Nahlieli O, et al. *An Er:YAG laser endoscopic fiber delivery system for lithotripsy of salivary stones.* Lasers Surg Med 2006;38:580-7.
- ⁴⁴ Durbec M, Dinkel E, Vigier S, et al. *Thulium-YAG laser sialoendoscopy for parotid and submandibular sialolithiasis.* Lasers Surg Med 2012;44:783-6.
- ⁴⁵ Iro H, Schneider T, Nitsche N, et al. *Extracorporeal piezoelectric lithotripsy of salivary calculi: initial clinical experiences.* HNO 1990;38:251-5.
- ⁴⁶ Ottaviani F, Capaccio P, Campi M, et al. *Extracorporeal electromagnetic shock-wave lithotripsy for salivary gland stones.* Laryngoscope 1996;106:761-4.
- ⁴⁷ Escudier MP, Brown JE, Drage NA, et al. *Extracorporeal shockwave lithotripsy in the management of salivary calculi.* Br J Surg 2003;90:482-5.
- ⁴⁸ Iro H, Nitsche N, Schneider HT. *Extracorporeal shockwave lithotripsy of salivary gland stones.* Lancet 1989;2:115.
- ⁴⁹ Schmitz S, Zengel P, Alvir I. *Long-term evaluation of extracorporeal shock wave lithotripsy in the treatment of salivary stones.* J Laryngol Otol 2008;122:65-71.
- ⁵⁰ Zenk J, Bozzato A, Winter M, et al. *Extracorporeal shock wave lithotripsy of submandibular stones: evaluation after 10 years.* Ann Otol Rhinol Laryngol 2004;113:378-83.
- ⁵¹ Escudier MP, Brown JE, Putcha V, et al. *Factors influencing the outcome of extracorporeal shock wave lithotripsy in the management of salivary calculi.* Laryngoscope 2010;120:1545-9.
- ⁵² Zenk J, Koch M, Mantsopoulos K, et al. *The significance of extracorporeal shock wave lithotripsy in sialolithiasis therapy.* HNO 2013;61:306-11.
- ⁵³ Nahlieli O, Shacham R, Zaguri A. *Combined external lithotripsy and endoscopic techniques for advanced sialolithiasis cases.* J Oral Maxillofac Surg 2010;68:347-53.
- ⁵⁴ Capaccio P, Torretta S, Pignataro L. *Extracorporeal lithotripsy techniques for salivary stones.* Otolaryngol Clin North Am 2009;42:1139-59.
- ⁵⁵ Iro H, Zenk J, Escudier MP, et al. *Outcome of minimally invasive management of salivary calculi in 4,691 patients.* Laryngoscope 2009;119:263-8.
- ⁵⁶ Chang J, Eisele DW. *Limited distal sialodochotomy to facilitate sialoendoscopy of the submandibular duct.* Laryngoscope 2013;123:1163-7.
- ⁵⁷ Rahmati R, Gillespie MB, Eisele DW. *Is sialoendoscopy an effective treatment for obstructive salivary gland disease?* Laryngoscope 2013;123:1828-9.
- ⁵⁸ Overton A, Combes J, McGurk M. *Outcome after endoscopically assisted surgical retrieval of symptomatic parotid stones.* Int J Oral Maxillofac Surg 2012;41:248-51.
- ⁵⁹ Makdissi J, Escudier MP, Brown JE, et al. *Glandular function after intra-oral removal of salivary calculi from the hilum of the submandibular gland.* Br J Oral Maxillofac Surg 2004;42:538-41.
- ⁶⁰ Combes J, Karavidas K, McGurk M. *Intraoral removal of proximal submandibular stones-an alternative to sialadenectomy?* Int J Oral Maxillofac Surg 2009;38:813-6.
- ⁶¹ Koch M, Bozzato A, Iro H, et al. *Combined endoscopic and transcutaneous approach for parotid gland sialolithiasis: indications, technique, and results.* Otolaryngol Head Neck Surg 2010;142:98-103.
- ⁶² Marchal F. *A combined endoscopic and external approach for extraction of large stones with preservation of parotid and submandibular glands.* Laryngoscope 2007;117:373-7.
- ⁶³ Capaccio P, Clemente IA, McGurk M, et al. *Transoral removal of hiloparenchymal submandibular calculi: a long-term clinical experience.* Eur Arch Otorhinolaryngol 2011;268:1081-6.
- ⁶⁴ Pagliuca G, Martellucci S, de Vincentiis M, et al. *Wharton's duct repair after combined sialolithectomy: is ductoplasty necessary?* Otolaryngol Head Neck Surg 2013;148:775-7.
- ⁶⁵ Nahlieli O, London D, Zagury A, et al. *Combined approach to impacted parotid stones.* Oral Maxillofac Surg 2002;60:1418-23.
- ⁶⁶ Zhang L, Escudier M, Brown J, et al. *Long-term outcome after intraoral removal of large submandibular gland calculi.* Laryngoscope 2010;120:964-6.
- ⁶⁷ Walvekar RR, Bomeli SR, Carrau RL, et al. *Combined approach technique for the management of large salivary stones.* Laryngoscope 2009;119:1125-9.

- 68 Geyer JT, Ferry JA, Harris NL, et al. *Chronic sclerosing sialadenitis (Küttner tumor) is an IgG4-associated disease*. Am J Surg Pathol 2010;34:202-10.
- 69 Ohta N, Makihara S, Okano M, et al. *Roles of IL-17, Th1, and Tc1 cells in patients with IgG4-related sclerosing sialadenitis*. Laryngoscope 2012;122:2169-74.
- 70 MH, Guobis Z. *Advances in the aetiopathogenesis of Sjögren's Syndrome: a literature review*. J Oral Maxillofac Res 2012;3:e2.
- 71 Passafaro D, S. Reina S, Sterin-Borda L, et al. *Cholinergic autoantibodies from primary Sjogren's syndrome modulate submandibular gland Na+/K+-ATPase activity via prostaglandin E2 and cyclic AMP*. Eur J Oral Sciences 2010;118:131-8.
- 72 Shacham R, Puterman MB, Ohana N, et al. *Endoscopic treatment of salivary glands affected by autoimmune diseases*. J Oral Maxillofac Surg 2011;69:476-81.
- 73 Canzi P, Occhini A, Pagella F, et al. *Sialoendoscopy in juvenile recurrent parotitis: a review of literature*. Acta Otorhinolaryngol Ital 2013;33:367-73.
- 74 Galili D, Marmary Y. *Juvenile recurrent parotitis: Clinicoradiologic follow-up study and the beneficial effect of sialography*. Oral Surg Oral Med Oral Pathol 1986;61:550-6.
- 75 Capaccio P, Sigismund PE, Luca N, et al. *Modern management of juvenile recurrent parotitis*. J Laryngol Otol 2012;126:1254-60.
- 76 Konstantinidis I, Chatziavramidis A, Tsakiropoulou E, et al. *Pediatric sialoendoscopy under local anesthesia: limitations and potentials*. Int J Pediatr Otorhinolaryngol 2011;75:245-9.
- 77 Strychowsky JE, Sommer DD, Gupta MK, et al. *Sialoendoscopy for the management of obstructive salivary gland disease: a systematic review and meta-analysis*. Arch Otolaryngol Head Neck Surg 2012;138:541-7.
- 78 McGurk M. *Salivary gland disease. First International accord on modern management-Paris, July 4-5 2008*. Acta Otorhinolaryngol Ital 2008;28:269-72.
- 79 Ardekian L, Klein H, Al Abri R, et al. *Sialoendoscopy for the diagnosis and treatment of juvenile recurrent parotitis*. Rev Stomatol Chir Maxillofac Chir Orale 2014;115:17-21.
- 80 Harbison JM, Liess BD, Templer JW, et al. *Chronic parotitis: a challenge disease entity*. Ear Nose Throat J 2011;90:E13-6.
- 81 Özkan BT, Tabrizi R, Cigerim L. *Management of bilateral masseter muscle hypertrophy*. J Craniofac Surg 2012;23:e14-6.
- 82 Reddy R, White DR, Gillespie MB. *Obstructive parotitis secondary to an acute masseteric bend*. ORL J Otorhinolaryngol Relat Spec 2012;74:12-5.
- 83 Prendes BL, Orloff LA, Eisele DW. *Therapeutic sialoendoscopy for the management of radioiodine sialadenitis*. Arch Otolaryngol Head Neck Surg 2012;138:15-9.
- 84 Bomeli SR, Schaitkin B, Carrau RL, et al. *Interventional sialoendoscopy for treatment of radioiodine-induced sialadenitis*. Laryngoscope 2009;119:864-7.
- 85 Kim JW, Han GS, Lee SH, et al. *Sialoendoscopic treatment for radioiodine induced sialadenitis*. Laryngoscope 2007;117:133-6.
- 86 Mandel SJ, Mandel L. *Radioactive iodine and the salivary glands*. Thyroid 2003;13:265-71.
- 87 Nahlieli O, Nazarian Y. *Sialadenitis following radioiodine therapy - a new diagnostic and treatment modality*. Oral Dis 2006;12:476-9.
- 88 Koch M, Zenk J, Bozzato A, et al. *Sialoscopy in cases of unclear swelling of the major salivary glands*. Otolaryngol Head Neck Surg 2005;133:863-8.
- 89 Zenk J, Koch M, Klintworth N, et al. *Sialoendoscopy in the diagnosis and treatment of sialolithiasis: a study on more than 1000 patients*. Otolaryngol Head Neck Surg 2012;147:858-63.
- 90 Nahlieli O, Baruchin AM. *Long-term experience with endoscopic diagnosis and treatment of salivary gland inflammatory diseases*. Laryngoscope 2000;110:988-93.
- 91 Luers JC, Grosheva M, Stenner M, et al. *Sialoendoscopy: prognostic factors for endoscopic removal of salivary stones*. Arch Otolaryngol Head Neck Surg 2011;137:325-9.
- 92 Walvekar RR, Carrau RL, Schaitkin B. *Endoscopic sialolith removal: orientation and shape as predictors of success*. Am J Otolaryngol 2009;30:153-6.
- 93 Nahlieli O, Bar T, Shacham R, et al. *Management of chronic recurrent parotitis: current therapy*. J Oral Maxillofac Surg 2004;62:1150-5.
- 94 Ardekian L, Shamir D, Trabelsi M, et al. *Chronic obstructive parotitis due to strictures of Stensen's duct--our treatment experience with sialoendoscopy*. J Oral Maxillofac Surg 2010;68:83-7.
- 95 Martins-Carvalho C, Plouin-Gaudon I, Quenin S, et al. *Pediatric sialoendoscopy: a 5-year experience at a single institution*. Arch Otolaryngol Head Neck Surg 2010;136:33-6.
- 96 McGurk M, Makdissi J, Brown JE. *Intra-oral removal of stones from the hilum of the submandibular gland: report of technique and morbidity*. Int J Oral Maxillofac Surg 2004;33:683-6.
- 97 Witt RL, Iro H, Koch M, et al. *Minimally invasive options for salivary calculi*. Laryngoscope 2012;122:1306-11.
- 98 Gutmann R, Ziegler G, Leunig A, et al. *Endoscopic and extracorporeal shock wave lithotripsy of salivary calculi*. Laryngorhinootologie 1995;74:249-53.
- 99 Wallace E, Tauzin M, Hagan J, et al. *Management of giant sialoliths: review of the literature and preliminary experience with interventional sialoendoscopy*. Laryngoscope 2010;120:1974-8.
- 100 Felton M, Mamais C, Kumar BN, et al. *Medico-legal aspects of introducing sialoendoscopy: a minimally invasive treatment for salivary gland obstruction*. Clin Otolaryngol 2012;37:213-20.

Received: May 13, 2015 - Accepted: June 18, 2015

Address for correspondence: Andrea Gallo, via Adolfo Venturi 19, 00162 Rome, Italy. Tel. +39 06 86205513. Fax +39 06 49976804. E-mail: andrea.gallo@uniroma1.it

HEAD AND NECK

Clinicopathologic characteristics of familial versus sporadic papillary thyroid carcinoma

Caratteristiche clinicopatologiche del carcinoma tiroideo papillare familiare a confronto con il carcinoma tiroideo papillare sporadico

L. JIWANG¹, L. ZHENDONG¹, L. SHUCHUN¹, H. BO², L. YANGUO¹¹ Department of Head and Neck Surgery, Liaoning Cancer Hospital & Institute, Shenyang, People's Republic of China; ² Department of Pathology, Liaoning Cancer Hospital & Institute, Shenyang, People's Republic of China

SUMMARY

It is unclear whether familial non-medullary thyroid carcinoma (FNMTC) is more aggressive than sporadic carcinoma, and its prevalence is still under debate. In this study, we investigated the clinicopathologic features of familial papillary thyroid carcinoma (PTC) compared with its sporadic counterpart. We used data from our hospital between 2008 and 2014 to compare the features of 24 familial PTC with 80 sporadic PTC. The prevalence of familial PTC was 1.5%; 25% of familial PTC exhibited a parent-offspring relationship, and 75% exhibited a sibling relationship. There were significant differences in terms of Hashimoto's thyroiditis, nodular goiter, multicentricity, bilaterality, histologic variant, T stage and N stage between the familial and sporadic PTC groups (all $p < 0.05$). When we compared sporadic PTC with parent-offspring or sibling familial PTC separately, parent-offspring familial PTC was more Hashimoto's thyroiditis and central LNM, while sibling familial PTC was more prevalent in multifocality and bilaterality than sporadic PTC. The recurrence rate was not significantly higher than that of sporadic PTC in familial PTC. The second generation in parent-offspring familial PTC patients exhibited an earlier age at diagnosis, greater multifocality and a higher metastasis rate than the first generation. Based on our results, we conclude that familial PTC is a clinically distinct entity with an aggressive nature. Because of the frequent presence of benign nodules, multifocality, bilaterality and high rate of recurrence, total or near-total thyroidectomy with neck dissection in these patients might be recommended. To date, the optimal clinical treatment is yet to be established, but improved awareness and screening will permit earlier detection, more timely intervention and improved outcomes for patients and their families.

KEY WORDS: Thyroid carcinoma • Papillary carcinoma • Familial • Clinicopathologic characteristics

RIASSUNTO

Non è chiaro se il carcinoma tiroideo non midollare familiare sia più aggressivo del carcinoma sporadico, ed è ancora dibattuta la prevalenza. In questo studio, abbiamo indagato le caratteristiche clinico-patologiche del carcinoma papillare tiroideo (PTC) a confronto con la sua controparte sporadica. Abbiamo utilizzato i dati ottenuti dal nostro ospedale tra il 2008 ed il 2014 per comparare le caratteristiche di 24 PTC familiari con 80 PTC sporadici. La prevalenza del PTC familiare è stata 1,5%; il 25% dei PTC familiare vedeva un interessamento combinato genitore-figlio, e il 75% vedeva interessati dei fratelli. Ci sono state differenze significative tra i gruppi di PTC familiari e sporadici in termini di tiroidite di Hashimoto, gozzo nodulare, multicentricità, bilateralità, variante istologica, stadio T, e stadio N (tutti $p < 0,05$). Quando abbiamo confrontato il PTC sporadico con il PTC familiare rispettivamente con interessamento genitore-figlio e di fratelli, il PTC familiare con interessamento genitore-figlio presentava una maggiore associazione con la tiroidite di Hashimoto e LNM centrale, mentre il PTC familiare con interessamento di fratelli presentava una maggiore prevalenza di multi focalità e bilateralità rispetto al PTC sporadico. Il tasso di recidiva nel PTC familiare non è stato significativamente più alto rispetto al PTC sporadico. La seconda generazione dei pazienti con PTC familiare con interessamento genitore-figlio presentava un'età inferiore alla diagnosi, maggiore multi focalità ed un tasso di metastasi più alto rispetto alla prima generazione. Sulla base dei nostri risultati, possiamo concludere che il PTC familiare è un'entità clinicamente distinta con una natura aggressiva. A causa della frequente presenza di noduli benigni, multi focalità, bilateralità, e alto tasso di recidiva, nella totalità o quasi totalità dei casi in questi pazienti potrebbe essere consigliata la tiroidectomia con svuotamento laterocervicale. Ad oggi, il trattamento clinico ottimale è ancora da stabilire, ma una migliore consapevolezza e lo screening permetteranno una diagnosi precoce, un intervento più tempestivo, ed un miglioramento dei risultati per i pazienti e le loro famiglie.

PAROLE CHIAVE: Carcinoma della tiroide • Carcinoma papillare • Familiarità • Caratteristiche clinico-patologiche

Acta Otorhinolaryngol Ital 2015;35:234-242

Introduction

Thyroid cancer is the most common form of neoplasia of the endocrine system, accounting for about 1-3% of

all cancers, and in the USA the yearly incidence has increased from 3.6 per 100,000 in 1973 to 8.7 per 100,000 in 2002¹. The incidence of thyroid carcinoma is rapidly

increasing, with one of the fastest rates of increase among common human cancers². Currently, non-medullary thyroid carcinoma (NMTC) is the seventh most common tumour in women³. Thus, it is important to identify patients at high risk for thyroid cancer.

Differentiated thyroid carcinoma, which includes papillary cancer, comprises the majority of all thyroid cancers⁴. Differentiated thyroid carcinoma is usually sporadic except for some rare inherited diseases such as familial adenomatous polyposis, Gerdner syndrome and Cowden's disease. However, in 1955, Robinson and Orr first reported NMTC in monozygotic twins⁵, while increased risk of thyroid cancer in individuals with a first-degree relative with thyroid cancer has been reported by population studies⁶⁻⁹. Because some susceptibility genes have not been clearly identified¹⁰, the entity of familial non-medullary thyroid carcinoma (FNMTTC) is established as a diagnosis in patients with one or more affected persons among their first-degree relatives. The estimated frequency of FNMTTC ranges from 2.5 to 11.3% among all thyroid cancer patients, although the precise prevalence is unknown^{7,11}. Based on previous studies from various countries, the aggressiveness of FNMTTC remains a topic of debate, and it remains controversial whether the biological characteristics including prognosis in patients with FNMTTC differ from those with sporadic carcinoma¹²⁻¹⁷. Thus, we undertook a retrospective study to investigate the difference in clinicopathological features and prognoses between FNMTTC and sporadic NMTC.

Materials and methods

Patients

Between January 2008 and July 2014, 2,402 patients underwent surgical treatment for thyroid cancer at the Department of Head and Neck Surgery in Liaoning Cancer Hospital & Institute. Exclusion criteria included prior exposure to radiation, non-curative surgery, anaplastic thyroid carcinoma, medullary carcinoma, malignant lymphoma, metastatic carcinoma from other organs and other inherited familial cancer syndromes; thus 815 patients were excluded from the study. Among the remaining 1,587 patients, 24 from 9 families were classified as having FNMTTC as they had one or more first-degree relatives with thyroid cancer. First-degree relatives included parents, offspring and siblings. Because 24 FNMTTC patients were all papillary thyroid carcinoma (PTC): 12 belonged to families having two affected members and the remaining 12 belonged to those having three or more affected members, we randomly selected 80 patients with sporadic PTC in the same study period as the control group. Clinicopathologic features were then analysed statistically in the two groups. Clinicopathologic parameters included age, gender, tumour diameter, multifocality, bilaterality, extrathyroidal invasion, method of surgery, preoperative

thyroid stimulating hormone (TSH), combined chronic thyroiditis, presence of benign nodules, histologic subtype, lymph node metastasis (LNM), TNM stage and recurrence status. Patients were staged according to the seventh edition of the UICC/AJCC TNM staging system¹⁸. All subjects gave their informed consent for the study, and the protocol was approved by our institutional review board.

Preoperative diagnostic protocol

Diagnosis and preoperative evaluation of each patient in our hospital were performed according to a strategy that was not changed during the study period. In our department, all patients underwent a careful history and thorough physical examination. Ultrasonography, fine needle aspiration biopsy (FNAB) and ultrasonography-guided FNAB were used. In this study, all patients underwent ultrasonography examination and qualitative evaluation of the nodules was performed according to these criteria. Diagnosis of papillary cancer was confirmed by FNAB guided either by palpation or ultrasonography. Furthermore, when a small nodule was present in the contralateral lobe, we sometimes used additional FNAB for the nodule to decide the extent of thyroidectomy. Metastases to the lung and mediastinal lymph nodes were evaluated by preoperative imaging studies, such as CT.

Follow-up

Patient progress was followed by clinical examination, ultrasonography and laboratory tests (i.e., TSH, free thyroxine, and thyroglobulin) to examine for signs of local recurrence. Moreover, we also performed FNAB on suspected masses or lymph nodes, and cytopathologic diagnosis was obtained. All patients were closely followed after surgery until August 2014. The median follow-up duration of patients was 59.7 months (range, 0.3-79.9 months).

Statistical analyses

Continuous data are presented as mean \pm standard deviation (SD). A chi-square test was used for comparison of categorical variables. Continuous variables were compared using Student's t-test. All analyses were performed using SPSS 16.0 statistical packages (SPSS, Inc., Chicago, IL, USA). A value of $p < 0.05$ was considered statistically significant.

Results

Surgical designs and clinical outcomes of PTC patients

The extent of surgery was decided based on preoperative findings and intraoperative pathological results. In the familial PTC group, 14 (58.3%) patients underwent total or near-total thyroidectomy and 10 (41.7%) patients underwent lobectomy or isthmusectomy or partial lobectomy. In the sporadic PTC group, 34 (42.5%) patients under-

went total or near-total thyroidectomy, 8 (10.0%) patients underwent subtotal thyroidectomy and 38 (47.5%) patients underwent lobectomy or isthmusectomy or partial lobectomy. We carried out neck lymph node dissection (LND) in 73 patients (70.2%). Twenty (83.3%) in the familial PTC and 52 (65.0%) in the sporadic PTC underwent a central LND. In 44 of these patients, an additional therapeutic unilateral LND was performed, mostly due to enlarged and suspicious nodes detected with preoperative ultrasound. Fifty-three of these 73 patients (72.6%) with LND had histological evidence of lymph node involvement. During lymphadenectomy, one to 23 lymph nodes were removed. The number of involved lymph nodes varied between 0 and 18.

To date, 26 patients developed recurrence: 3 had thyroid recurrence, and 4 had lymph node recurrence in the familial PTC; 9 had thyroid recurrence, and 10 had lymph node

recurrence in sporadic PTC. These patients underwent re-operation, and they remain alive with no symptoms of further recurrence after second surgery. One patient with familial PTC had lung metastasis, and died of the disease 24 months after initial surgery.

Profiles of familial PTC patients and treatment

Of the 1,587 enrolled patients, 24 (1.5%) from 9 different families were diagnosed as having FNMTC. Table I summarises the backgrounds and clinicopathological features of these patients. Histology of carcinoma of 24 patients was all PTC, and the rate of histological variants was 50.0%, 37.5%, 4.2%, and 8.3% in classic, follicular, mixed, and tall cell, respectively. There were 9 males and 15 females (1:1.7) with an average age of 44 years (18-61 years). The average tumour size was 2.5 cm (0.3-5.0 cm). Twenty patients were stage I, and 4 patients were stage IV.

Table I. Backgrounds and clinicopathological features of 24 patients with familial PTC.

Patient No.	Family No.	Gender	Age (years)	Tumour size (cm)	Combined thyroid disease	Histological variants	Bilaterality	Multifocality	Extrathyroidal invasion	LNM	pTNM classification
1	1	Male	61	5.0	Absent	Follicular	Present	Positive, 4	Positive	Positive	T3N1bM0
2	1	Female	32	1.0	Absent	Follicular	Absent	Negative	Negative	Positive	T1aN1bM0
3	2	Male	34	2.5	Absent	Classic	Present	Positive, 2	Negative	Positive	T2N1aM0
4	2	Female	32	0.5	Hashimoto's thyroiditis	Classic	Present	Positive, 3	Negative	Negative	T1aNOM0
5	2	Female	36	1.8	Absent	Follicular	Present	Positive, 2	Negative	Positive	T1bN1aM0
6	2	Female	56	2.5	Nodular Goiter	Follicular	Present	Positive, 3	Negative	Positive	T2N1bM0
7	3	Female	36	2.0	Absent	Classic	Absent	Positive, 2	Negative	Positive	T1bN1bM0
8	3	Male	40	1.5	Absent	Classic	Present	Positive, 2	Negative	Negative	T1aNOM0
9	3	Male	37	0.3	Nodular Goiter	Classic	Present	Negative	Negative	Positive	T1aN1bM0
10	4	Male	61	5.0	Cystadenoma	Classic	Present	Negative	Negative	Positive	T3N1bM0
11	4	Male	40	3.0	Absent	Classic	Absent	Positive, 3	Positive	Positive	T3N1aM0
12	5	Male	40	3.0	Absent	Classic	Absent	Negative	Negative	Positive	T3N1aM0
13	5	Female	18	3.0	Nodular Goiter	Tall cell	Present	Positive, 3	Positive	Negative	T2NOM0
14	6	Female	32	3.0	Nodular Goiter	Tall cell	Present	Negative	Negative	Positive	T3N1bM0
15	6	Female	37	1.5	Hashimoto's thyroiditis	Follicular	Present	Positive, 3	Negative	Positive	T1bN1bM0
16	7	Female	40	2.5	Absent	Follicular	Present	Positive, 2	Negative	Positive	T2N1bM0
17	7	Female	35	3.0	Hashimoto's thyroiditis	Follicular	Absent	Negative	Negative	Positive	T2N1bM0
18	7	Female	37	2.0	Hashimoto's thyroiditis	Mixed	Absent	Positive, 3	Positive	Positive	T1bN1aM0
19	7	Male	32	4.5	Absent	Follicular	Present	Positive, 3	Negative	Positive	T3N1aM0
20	7	Female	42	1.5	Hashimoto's thyroiditis	Follicular	Present	Positive, 2	Negative	Negative	T1bNOM0
21	8	Female	43	3.0	Absent	Classic	Absent	Negative	Negative	Positive	T2N1bM0
22	8	Female	58	0.3	Nodular goiter, adenoma	Classic	Present	Negative	Negative	Negative	T1aNOM0
23	9	Male	47	5	Absent	Classic	Absent	Negative	Negative	Positive	T3N1bM0
24	9	Female	45	4	Absent	Classic	Present	Positive, 2	Negative	Negative	T3NOM0

LNM: lymph node metastasis; Sibling relationship: family 2, 3, 6, 7, 8, 9; Parent-offspring relationship: 1, 4, 5.

The incidence of bilaterality and multifocality was 54.2% and 62.5%, respectively. Extrathyroidal invasion and LNM were found in 4 and 18 patients, respectively. There were 6 patients with a parent-child relationship and 18 with a sibling relationship. Thyroid disease other than microcarcinomas occurred in 11 patients: Hashimoto's thyroiditis in 5, nodular goiter in 4, cystadenoma in 1 and nodular goiter with adenoma in 1 patient.

Comparison of clinicopathological differences between sibling and parent-offspring familial PTC

We evaluated whether there were any differences in the clinicopathological characteristics of patients with sibling and parent-offspring familial PTC (Table II). Preoperative TSH was higher in sibling group than in parent-offspring group (2.78 ± 2.04 vs 1.28 ± 1.18, p = 0.34). Hashimoto's thyroiditis (100% vs 27.8%, p < 0.01) and extrathyroidal invasion (50% vs 5.6%, p = 0.04) were more frequent in the parent-offspring group than in the sibling group. Women more commonly exhibited sibling PTC (72.2% vs 33.3%), and the rate of patients who were < 55 years was higher in the sibling PTC group (88.9% vs 66.7%); however, these differences were not significant (all p > 0.05). No significant differences between the two groups were seen considering other parameters.

Comparison of clinicopathological characteristics of familial and sporadic PTC

We next compared clinicopathological features between patients with familial and sporadic PTC (Table III). Hashimoto's thyroiditis (45.8% vs 16.2%, p < 0.01), multifocality (62.5% vs 25.0%, p < 0.01) and bilaterality (54.2% vs 15.0%, p < 0.01) were more frequent in the familial PTC group than the sporadic PTC group. The incidence of central LNM was higher in the familial PTC group (70.8% vs 53.8%, p = 0.16). There was a significant difference in terms of histological subtype between the two groups (p < 0.01). There were no significant differences between the two groups considering other parameters, except for T stage, N stage and nodular goiter. Comparing the clinicopathologic parameters between sporadic PTC and parent-offspring or sibling PTC separately, we found that sibling PTC was associated with more multifocality (66.7% vs 25.0%, p < 0.01) and bilaterality (55.6% vs 15.0%, p < 0.01) than sporadic PTC. There were significant differences between the two groups in terms of T stage (p < 0.01) and N stage (p = 0.04). We also found that parent-offspring PTC was more prevalent in T3-4 stage patients (66.7% vs 13.7%, p < 0.01) and presented a higher rate of Hashimoto's thyroiditis (p < 0.01) and central LNM (p = 0.04).

Discussion

The reported prevalence of FNMTC is ~5% of cases,

Table II. Clinicopathological features of sibling and parent-offspring familial PTC.

	Sibling (n = 18)	Parent-offspring (n = 6)	P value
Gender			0.15
Male	5 (27.8%)	4 (66.7%)	
Female	13 (72.2%)	2 (33.3%)	
Age (years)			0.25
< 55	16 (88.9%)	4 (66.7%)	
≥ 55	2 (11.1%)	2 (33.3%)	
Tumour size (cm)	3.08 ± 1.38	3.17 ± 1.60	0.13
Preoperative TSH	2.78 ± 2.04	1.28 ± 1.18	0.34
Hashimoto's thyroiditis			< 0.01
Present	5 (27.8%)	6 (100.0%)	
Absent	13 (72.2%)	0	
Nodular goiter			1.00
Present	4 (22.2%)	1 (16.7%)	
Absent	14 (77.8%)	5 (83.3%)	
Multifocality			0.64
Positive	12 (66.7%)	3 (50.0%)	
Negative	6 (33.3%)	3 (50.0%)	
Bilaterality			0.17
Positive	10 (55.6%)	1 (16.7%)	
Negative	8 (44.4%)	5 (83.3%)	
Extrathyroidal invasion			0.04
Positive	1 (5.6%)	3 (50.0%)	
Negative	17 (94.4%)	3 (50.0%)	
T stage			0.13
T1	9 (50.0%)	1 (16.7%)	
T2	5 (27.8%)	1 (16.7%)	
T3	4 (22.2%)	4 (66.7%)	
T4	0	0	
N stage			0.80
N0	5 (27.8%)	1 (16.7%)	
N1a	4 (22.2%)	2 (33.3%)	
N1b	9 (50.0%)	3 (50.0%)	
pTNM classification^{1a}			0.25
I + II	16 (88.9%)	4 (66.7%)	
III + IV	2 (11.1%)	2 (33.3%)	
Central LNM			0.13
Positive	11 (61.1%)	6 (100.0%)	
Negative	7 (38.9%)	0	
Lateral LNM			1.00
Positive	10 (55.6%)	3 (50.0%)	
Negative	8 (44.4%)	3 (50.0%)	
Recurrence			0.28
Positive	5 (27.8%)	0	
Negative	13 (72.2%)	6 (100.0%)	

LNM: lymph node metastasis; TSH: thyroid stimulating hormone.

varying from 2.5% to 11.3%. Due to the high prevalence of thyroid cancer, clustering of sporadic thyroid cancer in

Table III. Clinicopathological features of familial and sporadic PTC.

	Familial PTC (n = 24)	Sporadic PTC (n = 80)	P value
Gender			0.09
Male	9 (37.5%)	15 (18.8%)	
Female	15 (62.5%)	65 (81.2%)	
Age (years)			0.74
< 55	20 (83.3%)	69 (86.3%)	
≥ 55	4 (16.7%)	11 (13.7%)	
Tumour size (cm)	2.52 ± 1.49	2.31 ± 1.48	0.65
Preoperative TSH	2.41 ± 1.95	2.18 ± 1.61	0.82
Hashimoto's thyroiditis			< 0.01
Present	11 (45.8%)	13 (16.2%)	
Absent	13 (54.2%)	67 (83.8%)	
Nodular goiter			0.02
Present	5 (20.8%)	39 (48.8%)	
Absent	19 (79.2%)	41 (51.2%)	
Multifocality			< 0.01
Positive	15 (62.5%)	20 (25.0%)	
Negative	9 (37.5%)	60 (75.0%)	
Bilaterality			< 0.01
Positive	13 (54.2%)	12 (15.0%)	
Negative	11 (45.8%)	68 (85.0%)	
Extrathyroidal invasion			1.00
Positive	4 (16.7%)	16 (20.0%)	
Negative	20 (83.3%)	64 (80.0%)	
Histological variants			< 0.01
Classic	12 (50.0%)	72 (90.0%)	
Follicular	9 (37.5%)	8 (10.0%)	
Mixed	1 (4.2%)	0	
Tall cell	2 (8.3%)	0	
T stage			0.04
T1	10 (41.7%)	46 (57.5%)	
T2	6 (25.0%)	23 (28.8%)	
T3	8 (33.3%)	8 (10.0%)	
T4	0	3 (3.7%)	
N stage			0.03
NO	6 (25.0%)	14 (17.5%)	
N1a	6 (25.0%)	44 (55.0%)	
N1b	12 (50.0%)	22 (27.5%)	
pTNM classification			0.17
I	20 (83.3%)	57 (71.3%)	
II	0	9 (11.3%)	
III	0	5 (6.3%)	
IV	4 (16.7%)	9 (11.1%)	
Central LNM			0.16
Positive	17 (70.8%)	43 (53.8%)	
Negative	7 (29.2%)	37 (46.2%)	
Lateral LNM			0.10
Positive	13 (54.2%)	28 (35.0%)	
Negative	11 (45.8%)	52 (65.0%)	
Recurrence			0.56
Positive	5 (20.8%)	13 (16.3%)	
Negative	19 (79.2%)	67 (83.7%)	

LNM: lymph node metastasis; TSH: thyroid stimulating hormone.

one family may not be rare¹⁹. A vast majority of patients with FNMTc present PTC, although benign thyroid lesions, such as multinodular goiter, are commonly found in members of these families²⁰⁻²². Our results revealed 9 families including 24 individuals affected with PTC, and thus the incidence was 1.5% in our series of 1,587 consecutive patients. Currently, the frequency of familial PTC is difficult to establish and only a few isolated case reports exist in the literature. Ozaki et al. reported 23 cases among 11 families, but did not give the frequency in comparison with sporadic PTC²³. Stoffer et al. in their study reported a 6.2% familial PTC rate among 226 consecutive patients²⁴. Thus, further study including a large number of patients with familial PTC is necessary to elucidate this issue.

Whether FNMTc is more aggressive than sporadic disease remains controversial. This aggressiveness in many studies is characterised by multicentricity, bilaterality, LNM, larger tumour, extrathyroid invasion, increased incidence of benign thyroid nodules and recurrent disease^{13 15 16 25 26}. One study found that FNMTc patients with tumour size < 1 cm had significantly higher frequencies of multicentricity, bilaterality and LNM than sporadic NMTC¹². Uchino et al. did not find a significant increase in local invasion or LNM, but reported a significantly higher rate of recurrence and multicentricity in FNMTc¹⁶. Moreover, some authors have indicated that FNMTc often presents with more advanced UICC stages¹³. On the other hand, many investigations also have claimed that there are no differences between the two entities^{12 26 27}. These studies have proposed that the therapeutic strategy for FNMTc might depend on the same conventional prognostic factors as those for sporadic NMTC, and not on whether the cancer was familial or sporadic. With regards to aggressiveness, we found that the familial PTC group had a significant higher rate of multicentricity, bilaterality and T3-4 stage. Although there were no significant differences between the two groups, the rates of central and lateral LNM, and recurrence in the familial group were higher than in the sporadic group. In addition, our result also showed that the rate of classic variant type in the sporadic group is significantly higher than the familial group (90.0% vs 50.0%), but the follicular type rate was less frequent than the familial group (10.0% vs 37.5%). On the basis of these results, we conclude that familial PTC might have more aggressive behaviour than sporadic PTC.

When we subdivided familial PTC into parent-offspring and sibling groups and compared each with sporadic PTC, only the sibling group exhibited a significantly higher rate of multifocality, bilaterality and T3-4 stage compared with sporadic PTC. In parent-offspring group, the tumour size was larger, coexisting Hashimoto's thyroiditis was more prevalent, and the rates of male, T3-T4 stage and central LNM were higher than sporadic PTC. Until now, there are few studies comparing parent-offspring or sibling FN-

Table IV. Clinicopathological features of sibling and parent-offspring familial PTC and sporadic PTC.

	Sporadic PTC (n = 80)	Sibling (n = 18)	P value	Parent-offspring (n = 6)	P value
Gender			0.52		0.02
Male	15 (18.8%)	5 (27.8%)		4 (66.7%)	
Female	65 (81.2%)	13 (72.2%)		2 (33.3%)	
Age (years)			1.00		0.22
< 55	69 (86.3%)	16 (88.9%)		4 (66.7%)	
≥ 55	11 (13.7%)	2 (11.1%)		2 (33.3%)	
Tumour size (cm)	2.31 ± 1.48	3.08 ± 1.38	0.75	3.17 ± 1.60	0.08
Hashimoto's thyroiditis			0.31		< 0.01
Present	13 (16.2%)	5 (27.8%)		6 (100.0%)	
Absent	67 (83.8%)	13 (72.2%)		0	
Nodular goiter			0.06		0.21
Present	39 (48.8%)	4 (22.2%)		1 (16.7%)	
Absent	41 (51.2%)	14 (77.8%)		5 (83.3%)	
Multifocality			< 0.01		0.34
Positive	20 (25.0%)	12 (66.7%)		3 (50.0%)	
Negative	60 (75.0%)	6 (33.3%)		3 (50.0%)	
Bilaterality			< 0.01		1.00
Positive	12 (15.0%)	10 (55.6%)		1 (16.7%)	
Negative	68 (85.0%)	8 (44.4%)		5 (83.3%)	
Extrathyroidal invasion			0.19		0.12
Positive	16 (20.0%)	1 (5.6%)		3 (50.0%)	
Negative	64 (80.0%)	17 (94.4%)		3 (50.0%)	
Histological variants			< 0.01		< 0.01
Classic	72 (90.0%)	9 (50.0%)		3 (50.0%)	
Follicular	8 (10.0%)	7 (38.9%)		2 (33.3%)	
Mixed	0	1 (5.6%)		1 (16.7%)	
Tall cell	0	1 (5.6%)		0	
T stage			< 0.01		< 0.01
T1	46 (57.5%)	9 (50.0%)		1 (16.7%)	
T2	23 (28.8%)	5 (27.8%)		1 (16.7%)	
T3	8 (10.0%)	4 (22.2%)		4 (66.7%)	
T4	3 (3.7%)	0		0	
N stage			0.04		0.48
N0	14 (17.5%)	5 (27.8%)		1 (16.7%)	
N1a	44 (55.0%)	4 (22.2%)		2 (33.3%)	
N1b	22 (27.5%)	9 (50.0%)		3 (50.0%)	
pTNM classification			0.73		1.00
I + II	66 (82.6%)	16 (88.9%)		4 (66.7%)	
III ± IV	14 (17.4%)	2 (11.1%)		2 (33.3%)	
Central LNM			0.61		0.04
Positive	43 (53.8%)	11 (61.1%)		6 (100.0%)	
Negative	37 (46.2%)	7 (38.9%)		0	
Lateral LNM			0.12		0.66
Positive	28 (35.0%)	10 (55.6%)		3 (50.0%)	
Negative	52 (65.0%)	8 (44.4%)		3 (50.0%)	
Recurrence			0.31		0.59
Positive	13 (16.3%)	5 (27.8%)		0	
Negative	67 (83.7%)	13 (72.2%)		6 (100.0%)	

LNM: lymph node metastasis.

MTC with sporadic NMTC. In the study by Park et al., it was reported that parent-offspring FNMTC was more multifocal, while sibling FNMTC was more prevalent in female patients and presented with smaller tumours than sporadic disease²⁸. Gao et al. reported that compared with sporadic NMTC and sibling FNMTC presented a higher rate of central LNM, while parent-offspring FNMTC showed frequent tumour bilaterality and a higher rate of recurrence²⁹. When we compared the sibling group with the parent-offspring group, there were significant differences in extrathyroidal invasion and Hashimoto's thyroiditis. These findings suggested that the clinical characteristics of sibling and parent-offspring might be different in familial PTC. In recent investigations, the second generation in parent-offspring FNMTC was associated with an earlier age at diagnosis, greater multifocality and a higher metastasis rate^{15 21 30}. In accordance with previous results, we found that the second generation was diagnosed at a younger age (26.7 years), supporting the presence of "genetic anticipation", a phenomenon defined as the occurrence of a genetic disease at progressively earlier ages and with increased severity in successive generations in FNMTC^{15 30}. Simultaneously, the second generation also had more extrathyroidal invasion and multifocality than the first generation, which suggested that FNMTC diagnosed in the second generation might need more aggressive treatment than sporadic NMTC.

In some studies, FNMTC patients had several characteristics associated with poor prognosis. One study reported that patient's survival of FNMTC was significantly shorter than that of sporadic disease, and prognosis was poorer among FNMTC patients with 3 or more affected members¹⁶. However, Maxwell et al. in their case-control study found no significant difference in prognosis between familial and sporadic PTC groups¹². In our study, there were no deaths in the sporadic PTC group during follow-up, in contrast to familial PTC which showed a higher, although not significant, incidence of disease mortality (5.0%). These relatively surprising findings might be explained by the fact that all patients in this study are PTC.

There are no clinical trials to demonstrate the best management strategy for FNMTC at present. Due to a higher rate of LNM even with small tumours, several studies have recommended that individuals with familial disease should be treated more aggressively^{16 21 22 27}. Such approach includes near-total or total thyroidectomy and regional lymphadenectomy as the initial surgery in view of the high incidence of multifocal and bilateral disease, and postoperative radioiodine ablation in surgically-cured patients to reduce the rate of recurrence and to facilitate follow-up monitoring with serum thyroglobulin levels. Because of the high incidence of LNM in FNMTC patients, some authors recommend performing prophylactic central LND^{15 21 22}. If there are any clinically positive lateral nodes, a modified LND should also be performed^{15 16}.

Patients with morphologically suspicious lesions demonstrated by ultrasonography or with cold nodules shown by scintigraphy might immediately performed FNAB; if the cytology is benign, reexamination after six months is recommended. FNMTC relatives with benign, stationary thyroid nodules may be examined once a year. Simultaneously, all patients with thyroid carcinoma should also have a comprehensive history to identify potential familial forms of papillary or follicular thyroid carcinomas. Since benign thyroid disorders such as Hashimoto's thyroiditis and multinodular goiter are often observed in patients with FNMTC, families with affection of a first-degree relative with thyroid carcinoma and an accumulation of benign thyroid disease should be screened yearly with ultrasound⁷. Because FNMTC patients are frequently younger in the second generation compared to first generation, screening might start at the age of 18 years.

Genetic analyses of large FNMTC patients not only support the hypothesis that there exists an inherited genetic predisposition to FNMTC, but that it also represents the first steps in identification of the putative susceptibility genes by positional cloning methods³¹. Several linkage studies have identified loci within specific families, but none appear to account for a significant number of cases. The loci that have been identified to date include: MNG1, TCO1, fPTC/PRN and NMCT1²¹. The following loci, some of which have been implicated in sporadic carcinoma, have been excluded as the susceptibility gene in FNMTC: RET/PTC, PTEN, TSHR and TRKA³²⁻³⁴. As the genetic causes of FNMTC remain unknown, widespread genetic testing is not available. Large studies among kindreds are still required to identify the genes that may play a role in the development of FNMTC.

We acknowledge that there are several limitations in this study. First, all the FNMTC patients included were PTC. Although the majority of FNMTC is papillary carcinoma, this might be a bias for clearly evaluating the recurrence and metastasis. Secondly, we were not able to perform more detailed assess for prognostic outcome, because the follow-up period in this study was relatively short and the number of patients with familial PTC was small. In addition, it is very difficult for us to perform survival analysis, because the patients who died from thyroid carcinoma were very rare.

In summary, the prevalence of familial PTC in our study was 1.5%, which is lower than that reported in other studies. Familial PTC might be considered as a separate clinical entity with a higher frequency of multicentricity, bilaterality and T3-4 stage, as well as a higher rate of Hashimoto's thyroiditis than its sporadic counterpart. Familial PTC with a parent-offspring relationship exhibited a higher rate of Hashimoto's thyroiditis and central LNM than sporadic PTC, while a sibling relationship exhibited a higher rate of multicentricity and bilaterality. The second generation in parent-offspring familial PTC

was diagnosed at an earlier age and had a higher rate of extrathyroidal invasion and multifocality. Familial PTC might be treated aggressively, and patients need to be followed closely. Simultaneously, it should take into account careful familial histories of thyroid cancer patients and make decisions about diagnostic and treatment modalities after considering family incidence in NMTC patients with thyroid cancer or nodules. The rarity of FNMTTC and the retrospective method of our study implies that our findings need to be confirmed through larger, and possibly, multicentre series.

References

- 1 Davies L, Welch HG. *Increasing incidence of thyroid cancer in the United States, 1973-2002*. JAMA 2006;295:2164-7.
- 2 Nosé V. *Familial non-medullary thyroid carcinoma: an update*. Endocr Pathol 2008;19:226-40.
- 3 Ries LAG, Melbert D, Krapcho M, et al. *2007 SEER Cancer Statistics Review, 1975-2004*. Bethesda, MD: National Cancer Institute. http://seer.cancer.gov/csr/1975_2004/, based on November 2006 SEER data submission, posted to the SEER web site.
- 4 Proia G, Bianciardi Valassina MF, Palmieri G, et al. *Papillary carcinoma on a thyroglossal duct cyst: diagnostic problems and therapeutic dilemma. A case report*. Acta Otorhinolaryngol Ital 2014;34:215-7.
- 5 Robinson D, Orr T. *Carcinoma of the thyroid and other diseases of the thyroid in identical twins*. Auch Surg 1995;70:923-8.
- 6 Ron E, Kleinerman RA, LiVolsi VA, et al. *Familial nonmedullary thyroid cancer*. Oncology 1991;48:309-11.
- 7 Pal T, Vogl FD, Chappuis PO, et al. *Increased risk for non-medullary thyroid cancer in the first degree relatives of prevalent cases of nonmedullary thyroid cancer: a hospital-based study*. J Clin Endocrinol Metab 2001;86:5307-12.
- 8 Hemminki K, Eng C, Chen B. *Familial risks for nonmedullary thyroid cancer*. J Clin Endocrinol Metab 2005;90:5747-53.
- 9 Goldgar DE, Easton DF, Cannon-Albright LA, et al. *Systematic population – based assessment of cancer risk in the first – degree relatives of cancer probands*. J Natl Cancer Inst 1994;86:1600-8.
- 10 Khan A, Smellie J, Nutting C, et al. *Familial nonmedullary thyroid cancer: a review of the genetics*. Thyroid 2010;20:795-801.
- 11 Hemminki K, Dong C. *Familial relationships in thyroid cancer by histo-pathological type*. Int J Cancer 2000;85:201-5.
- 12 Maxwell EL, Hall FT, Freeman JL. *Familial non-medullary thyroid cancer: a matched-case control study*. Laryngoscope 2004;114:2182-6.
- 13 Alsanea O, Wada N, Ain K, et al. *Is familial non-medullary thyroid carcinoma more aggressive than sporadic thyroid cancer? A multi-center series*. Surgery 2000;128:1043-50.
- 14 Mazeh H, Benavidez AL, Poehls J, et al. *In patients with thyroid cancer of follicular cell origin, a family history of non-medullary thyroid cancer in one first-degree relative is associated with more aggressive disease*. Thyroid 2012;22:3-8.
- 15 Hillenbrand A, Varhaug JE, Brauckhoff M, et al. *Familial nonmedullary thyroid carcinoma – clinical relevance and prognosis. A European multicenter study. ESES Vienna presentation*. Langenbecks Arch Surg 2010;395:851-8.
- 16 Uchino S, Noguchi S, Kawamoto H, et al. *Familial nonmedullary thyroid carcinoma characterized by multifocality and a high recurrence rate in a large study population*. World J Surg 2002;26:897-902.
- 17 Lupoli G, Vitale G, Caraglia M, et al. *Familial papillary thyroid microcarcinoma: a new clinical entity*. Lancet 1999;353:637-9.
- 18 Edge SB, Byrd DR, Compton CC, et al. *AJCC cancer staging manual*. 7th ed. New York: Springer; 2010.
- 19 Charkes ND. *On the prevalence of familial non-medullary thyroid cancer in multiply affected kindreds*. Thyroid 2006;16:181-6.
- 20 Bonora E, Tallini G, Romeo G. *Genetic predisposition to familial nonmedullary thyroid cancer: an update of molecular findings and stage-of-the-art studies*. J Oncol 2010;2010:385206.
- 21 Sippel RS, Caron NR, Clark OH. *An evidence-based approach to familial nonmedullary thyroid cancer: screening, clinical management, and follow-up*. World J Surg 2007;31:924-33.
- 22 Musholt TJ, Musholt PB, Petrich T, et al. *Familial papillary thyroid carcinoma: genetics, criteria for diagnosis, clinical features, and surgical treatment*. World J Surg 2000;24:1409-17.
- 23 Ozaki O, Ito K, Kobayashi K, et al. *Familial occurrence of differentiated, nonmedullary thyroid carcinoma*. World J Surg 1998;12:565-71.
- 24 Stoffer SS, Van Dyke DL, Vaden Bach J, et al. *Familial papillary carcinoma of the thyroid*. Am J Med Genet 1986;25:775-82.
- 25 Triponez F, Wong M, Sturgeon C, et al. *Does familial non-medullary thyroid cancer adversely affect survival? World J Surg 2006;30:787-93*.
- 26 Ito Y, Fukushima M, Yabuta T, et al. *Prevalence and prognosis of familial follicular thyroid carcinoma*. Endocrine J 2008;55:847-52.
- 27 Loh KC. *Familial nonmedullary thyroid carcinoma: a meta-review of case series*. Thyroid 1997;7:107-13.
- 28 Park YJ, Ahn HY, Choi HS, et al. *The long-term outcomes of the second generation of familial nonmedullary thyroid carcinoma are more aggressive than sporadic cases*. Thyroid 2012;22:356-62.
- 29 Gao J, Yu Y, Li X, et al. *Clinical and biological features of familial nonmedullary thyroid carcinoma*. Zhonghua Zhong Liu Za Zhi 2014;36:202-6.
- 30 Capezzone M, Marchisotta S, Cantara S, et al. *Familial non-medullary thyroid carcinoma displays the features of clinical anticipation suggestive of a distinct biological entity*. Endocr Relat Cancer 2008;15:1075-81.
- 31 Malchoff CD, Malchoff DM. *Familial nonmedullary thyroid carcinoma*. Cancer Control 2006;13:106-10.
- 32 Learoyd DL, Messina M, Zedenius J, et al. *Molecular genetics of thyroid tumors and surgical decision-making*. World J Surg 2000;24:923-33.

- ³³ Malchoff CD, Sarfarazi M, Tendler B, et al. *Papillary thyroid carcinoma associated with papillary renal neoplasia: genetic linkage analysis of a distinct heritable tumor syndrome.* J Clin Endocrinol Metab 2000;85:1758-64.
- ³⁴ Lesueur F, Stark M, Tocco T, et al. *Genetic heterogeneity in familial nonmedullary thyroid carcinoma: exclusion of linkage to RET, MNG1, and TCO in 56 families.* NMTC Consortium. J Clin Endocrinol Metab 1999;84:2157-62.

Received: January 13, 2015 - Accepted: April 30, 2015

Address for correspondence: Zhen-Dong Li, Department of Head and Neck Surgery, Liaoning Cancer Hospital & Institute, 44 Xiaoheyuan Road, Dadong District, Shenyang, 110042, People's Republic of China. Tel. 86 24 31916252. Fax 86 24 24315679. E-mail: 1349946150@qq.com

HEAD AND NECK

Analysis of risk factors for pharyngocutaneous fistula after total laryngectomy with particular focus on nutritional status

Fistola faringocutanea dopo laringectomia totale: analisi dei fattori di rischio con particolare attenzione allo stato nutrizionale

F. MATTIOLI¹, M. BETTINI¹, G. MOLTENI¹, A. PICCININI¹, F. VALORIANI², S. GABRIELE², L. PRESUTTI¹

¹Head and Neck Department, University Hospital of Modena, Italy; ²Nutritionist, University Hospital of Modena, Italy

SUMMARY

Pharyngocutaneous fistula (PCF) is the most common complication following total laryngectomy and the most difficult to manage. It often causes increased morbidity, delays starting adjuvant therapy, prolongs hospitalisation, increases treatment costs and reduces the quality of life (QoL). The objective of this study is to analyse the predisposing factors and the most important nutritional parameters related to the development of PCF in patients undergoing total laryngectomy and to suggest medical alternatives that might improve results. We performed a retrospective study of 69 patients who underwent either primary or salvage total laryngectomy in our department between January 2008 and January 2012. Risk factors for fistula formation were analysed including tumour characteristics (histology, grading, AJCC stage), treatment (primary or salvage surgery, extent of resection, flap reconstruction, preoperative radiotherapy), comorbidity and nutritional status (preoperative haemoglobin, albumin and prealbumin levels and their changes during hospitalisation). Twenty-four patients developed a PCF (overall incidence 34.8%). Fistula formation was significantly higher in patients with diabetes, preoperative malnutrition (identified from low preoperative albumin and prealbumin levels). After specific nutritional evaluation and support, no patient developed a PCF. Risk factors for PCF formation are extensively treated in the literature but identification of high-risk patients is still controversial. Our study demonstrates that nutritional status of the patient, assessed by preoperative albumin, is also an important risk factor for PCF formation in addition to classical factors. Maintenance of a normal preoperative nutritional status can be helpful to avoid this complication.

KEY WORDS: Laryngectomy • Pharyngocutaneous fistula • Malnutrition

RIASSUNTO

La formazione di fistole faringocutanee è una delle complicanze più frequenti dopo laringectomia totale e la più difficile da gestire. La comparsa di una fistola faringocutanea determina spesso aumento della morbilità, ritardo nell'inizio delle terapie adiuvanti, prolungata ospedalizzazione, aumento dei costi di trattamento e riduzione della qualità di vita. L'obiettivo di questo studio è analizzare i principali fattori di rischio e i parametri nutrizionali correlati allo sviluppo di fistole faringocutanee nei pazienti sottoposti a laringectomia totale e valutare i possibili interventi terapeutici finalizzati a ridurre l'incidenza di tale complicanza. Abbiamo effettuato uno studio retrospettivo su 69 pazienti sottoposti presso il nostro istituto a laringectomia totale, come trattamento primitivo o di salvataggio, fra gennaio 2008 e gennaio 2012. I fattori di rischio per la formazione di fistole faringocutanee analizzati sono stati: caratteristiche del tumore (istologia, grading, stadio, ecc.), trattamento (chirurgia primitiva o di salvataggio, estensione della resezione, ricostruzione con lembo, radioterapia preoperatoria, ecc.), comorbilità e stato nutrizionale (valori e trend di emoglobina preoperatoria, albumina e prealbumina). Dopo valutazione e supporto nutrizionale mirato nessun paziente ha sviluppato fistole faringocutanee. L'identificazione dei pazienti ad alto rischio di fistola faringocutanea dopo laringectomia totale è argomento ancora dibattuto in letteratura. Il nostro studio ha dimostrato che lo stato nutrizionale del paziente, valutato attraverso i valori di albumina preoperatoria, è anch'esso un fattore di rischio per lo sviluppo di fistole faringocutanee. Quindi il mantenimento di un stato nutrizionale adeguato può essere utile per evitare tale complicanza.

PAROLE CHIAVE: *Laringectomia • Fistola faringocutanea • Malnutrizione*

Acta Otorhinolaryngol Ital 2015;35:243-248

Introduction

Pharyngocutaneous fistula (PCF) consists of a communication between the digestive tract and the cervical skin that causes the appearance of saliva on the skin surface after swallowing. PCF are classified by Zbar and Funk¹

as either a pharyngocutaneous fistula (an anomalous path connecting the pharynx and the skin) or a pharyngostoma (a direct opening of the pharynx to the skin, often accompanied by skin loss).

PCF is the most common complication after total laryngectomy and the most difficult to manage. The rate for

development of a PCF varies from 8% to 22% of patients undergoing total laryngectomy²⁻⁶. It is the major cause of increased morbidity, delays starting of adjuvant therapy, prolongs hospitalisation, increases treatment costs and reduces the quality of life (QoL). In 1998, Parikh et al. estimated a cost of \$400,000 per annum to treat fistulae after laryngectomy at their reference care centre in Toronto⁷.

The predisposing factors can be divided into patient-related factors (sex, age, smoking, alcohol consumption, diabetes, heart disease⁸, gastro-oesophageal reflux disease⁹, decreased preoperative haemoglobin⁸, albumin¹⁰ and calcium levels, previous surgical treatment, previous radiotherapy¹¹⁻¹³ or chemoradiotherapy, tumour recurrence¹⁴), disease-related factors (stage¹³⁻¹⁵, lymph nodes and pharynx involvement¹⁶⁻¹⁷) and treatment-related factors (marginal status¹¹⁻¹²⁻¹⁸, type and technique of closure, experience of the surgeon, preoperative tracheostomy and wound infection).

Risk factors are extensively investigated in the literature, but how to identify high-risk patients is still controversial¹¹⁻¹⁸. Regarding patient-related factors, it is well known that patients with head and neck cancer are at particular risk for malnutrition for several reasons. Poor dietary habits together with excessive smoking and alcohol consumption are frequently observed among these patients and predispose them to malnutrition¹⁹.

Moreover, the location and stage of the tumour can lead to dysphagia, odynophagia, dysgeusia, or trismus, and result in reduced energy levels and protein intake²⁰⁻²¹. Regardless of the underlying mechanisms, cancer-related weight loss and cancer-related malnutrition are multi-dimensional manifestations that reduce patient well-being²², tolerance to and prognosis after antineoplastic therapy²³⁻²⁴, decrease immunological responses to tumour cells²⁴⁻²⁵ and resistance to infection²⁴⁻²⁶, and increase susceptibility to postoperative complications²⁴⁻²⁷, disability and overall cost of care²⁴. For these reasons, malnutrition can contribute to the development of PCF.

Malnutrition has been reported in 30% to 50% of patients with head and neck malignancies²⁰⁻²¹⁻²⁸, particularly squamous cell carcinomas of the oropharyngeal and hypopharyngeal regions. The apparent nutritional depletion in these patients reduces their tolerance to treatment²⁴⁻²⁸.

In 70 to 80% of cases, the fistulae close spontaneously with local care and tube or parenteral feeding, and further intervention is required in only a minority of cases: the most widely reported technique in use is pectoralis major myofascial flap reinforcement.

In this study, we analyse the predisposing factors and most important nutritional parameters related to the development of PCF in patients undergoing either primary or salvage laryngectomy and suggest medical options to improve the outcomes.

Materials and methods

A retrospective analysis of patients who underwent total laryngectomy at the ENT Department of University Hospital of Modena between January 2008 and January 2012 was carried out. Patients who underwent either primary or salvage total laryngectomy were included.

Surgery

Surgery was performed with curative intent consisting of total laryngectomy as a single procedure or combined with dissection of the neck, thyroidectomy and reconstruction with pectoralis major flap.

Surgical technique and postoperative care were generally standardised.

Pharyngeal reconstruction was performed in three layers: mucosal, fascia and muscular. In all patients, nasogastric feeding was initiated on the first postoperative day and oral feeding was started after a swallowing study on day 7-10.

Risk factors

The primary endpoint was to identify risk factors predisposing patients to fistula formation. A retrospective chart review was conducted. A database was built including data with regard to tumour characteristics (histology, grading, T stage, N stage, AJCC stage), treatment (eventual flap reconstruction, presence of preoperative tracheostomy, primary or salvage surgery, preoperative radiotherapy), comorbidities (history of diabetes or vascular disease), blood values assessing nutritional status (preoperative serum haemoglobin, albumin and prealbumin and their changes during hospitalisation). In fact, preoperative serum albumin was not available for all patients. Since albumin is a blood protein with a lifespan of about 30 days, the value of the first postoperative serum albumin (measured 1 week after surgical intervention) can be considered to be equal to the preoperative value.

Statistical analysis

Pearson's χ^2 test was used to evaluate the correlation between the incidence of fistula formation and potential predisposing factors. A p value < 0.05 was considered statistically significant.

Results

Sixty-nine patients were included in the study. Patient and tumour characteristics are detailed in Table I. Median age was 71 years (range 37-88 years). Fistula formation was noted in 24 patients (34.8%). The time of fistula formation is summarised in Table II. Laryngectomy was performed as primary treatment in 51 patients (73.9%). Ten patients underwent pretreatment radiotherapy (14.5%). Preopera-

Table I. Patient characteristics (n = 69).

	N (%)
Histology	
SCC	65 (94.2%)
Basaloid SCC	1 (1.4%)
Papillary thyroid tumour	2 (2.9%)
Undifferentiated	1 (1.4%)
Gender	
Male	59 (85.5%)
Female	10 (14.5%)
Grading	
G1	2.9%
G2	39.1%
G3	49.3%
GX	8.7%
T Stage	
T1	7.2%
T2	8.7%
T3	23.2%
T4	60.9%
N Stage	
N0	58%
N1	15.9%
N2a	0
N2b	13%
N2c	7.3%
N3	5.8%
AJCC Stage	
I	4 (5.8%)
II	5 (7.2%)
III	17 (23.2%)
IVa	40 (58%)
IVb	1 (1.4%)
IVc	2 (2.9%)

SCC: squamous cell carcinoma.

Table II. Time of fistula formation.

Postoperative day	N (%)
0-11	14 (20.3%)
12-23	7 (10.1%)
24-33	2 (2.9%)
> 33	1 (1.4%)

tive tracheostomy was performed in 15 patients (22.1%). Lateral neck dissection was performed bilaterally in 29 patients (42%) and unilaterally in 22 (31.9%). In the majority of cases, histology was squamous cell carcinoma (94.2%) with different grades of differentiation. Two patients were affected by papillary thyroid carcinoma with larynx extension, and two patients by an undifferentiated carcinoma.

Table III summarises the results of univariate analysis on the impact of the potential predisposing factors on fistula formation. From the analysis, p values ≤ 0.05 were present for the correlation of fistula formation with diabetes (p = 0.004), and low preoperative albumin and prealbumin levels (p = 0.005).

Discussion

From January 2008 to January 2012, our data show an incidence of PCF that is higher than that reported in other studies (34.8% vs 8-22%)²⁻⁶. The retrospective analysis of our results and review of the literature were used to identify the most important risk factors of PCF and to improve perioperative management to avoid this complication. The most comprehensive study on PCF risk factors is a multivariate analysis study by Onal and colleagues²⁹: a significant relationship was found between development of PCF and previous radiotherapy, positive ipsilateral and contralateral lymph nodes, accompanying systemic disease, pre- and postoperative haemoglobin < 12.2 g/dl and postoperative albumin level < 3.5 g/dl.

In their meta-analysis of postlaryngectomy PCF, Paydarfar and Birkmeyer³⁰ considered 10 separate variables and established that preoperative radiotherapy, postoperative haemoglobin < 12.5 g/dl, prior tracheotomy and concurrent neck dissection were all significant risk factors for formation of PCF. Similar results were obtained by Galli and De Corso³¹: systemic diseases, previous radiotherapy, supraglottic origin of tumour and concurrent radical neck dissection were significantly associated with PCF.

Cavalot et al.³² demonstrated that diabetes mellitus influenced the development of PCF. However, using the 'Cumulative Illness Rating Scale', Dedivitis et al.³³ found no correlation between systemic disease and development of PCF.

Preoperative radiotherapy, lymph node involvement, positive surgical margins and low pre- and postoperative haemoglobin have been considered relevant risk factors in other studies^{11 12 29 34-36}. In particular, radiotherapy can increase the incidence of PCF because of the decreased healing capacity secondary to fibrosis and hypovascularisation.

In a recent study, Dirven et al.³⁷ demonstrated a correlation between risk of PCF and interval between radiotherapy and surgery: patients undergoing salvage surgery within 12 months after radiotherapy had a higher risk of developing PCF compared to those undergoing salvage surgery more than 12 months after radiotherapy (p = 0.014).

In our analysis, a significant correlation was detected between diabetes and the development of PCF, whereas other risk factors such as preoperative radiotherapy and haemoglobin levels were not.

All our patients underwent total laryngectomy with manual closure of the pharynx. Many surgeons prefer to close the pharynx using a stapler. In a prospective study, Dedivitis³⁸ found no significant difference in the incidence of PCF between the mechanical closure group and the manual suture group. Morton et al.³⁹ showed that preoperative low serum albumin levels were significantly associated with development of PCF. Our results also showed how poor nutritional status in terms of albumin levels plays a

Table III. Univariate analysis of the impact of predisposing factors on fistula formation.

Risk factor	% patients with fistula	% patients without fistula	p value
G1	50	50	0.18
G2	22.2	78.8	
G3	48.5	51.5	
Gx	16.7	83.3	
T1	66.7	33.3	0.51
T2	34.3	65.7	
T3	25	75	
T4	38.1	61.9	
N+	75	25	0.41
N-	30	70	
R1	31.2	68.8	0.7
R0	36.5	63.5	
AJCC stage I	50	50	0.42
AJCC stage II	40	60	
AJCC stage III	18.8	81.2	
AJCC stage IV	42.5	57.5	
Previous RT	40	60	0.72
No previous RT	34.5	65.5	
Primary surgery	41.2	58.8	0.06
Savage surgery	16.7	83.3	
Previous tracheostomy	40	60	0.56
No neck dissection	22.2	77.8	0.26
Monolateral neck dissection	31.8	68.2	
Co-morbidity			
Diabetes	77.8	22.2	0.004
No diabetes	28.3	71.7	
Vasculopathy	42.9	57.1	0.41
No vasculopathy	31.3	68.7	
Preop Hb < 12.2 g/dl	45	55	0.14
Preop Hb > 12.2 g/dl	30.6	69.4	
Preop albumin < 3.5 g/dl or prealbumin < 20 mg/dl	53.6	46.6	0.005
Preop albumin > 3.5 g/dl or prealbumin > 20 mg/dl	120	180	
Albumin during hospitalisation			0.4
Decrease	80	20	
Increase	35.3	64.7	
Unchanged	50	50	
Hb during hospitalisation			0.34
Decrease	34.6	65.4	
Increase	44.4	55.6	

Hb: haemoglobin; RT: radiotherapy.

crucial role in PCF development. In fact, low preoperative albumin is an important index of malnutrition.

Only few studies have been carried out on the relationship between nutritional parameters and the incidence of major postoperative complications^{19 21 23 24}. Unintentional weight loss, and a lesser degree albumin, were predictive for postoperative complications. Weight loss seems to be the most important parameter for predicting major postoperative complications; patients with > 10% weight loss during the 6 months before surgery are at greater risk for the occurrence of major postoperative complications^{19 40}.

The European Society for Parenteral and Enteral Nutrition (ESPEN) guidelines on enteral nutrition⁴¹ recommend the use of nutritional support for 10-14 days be-

fore major surgery in patients with severe nutritional risk (weight loss > 10–15% within 6 months before surgery, BMI < 18.5%, serum albumin < 3 g/dl).

We are presently carrying out a prospective multicentre study to evaluate if the correction of malnutrition can reduce the incidence of PCF in patients with head and neck cancer.

The nutritional status of these patients was defined preoperatively. Thus, in the presence of malnutrition nutritional support is offered before surgery. If there is good preoperative nutritional status, the onset of postoperative malnutrition is thus avoided. Tube feeding for patients starts within 24-48 h after surgery and takes from 2 to 3 days to reach nutritional targets. Energy requirement will be

assess by Herreris-Benedict equation and each patient will receive 1.2-1.4 g/kg/day of proteins.

We have initiated a standardised enteral nutritional plan tailored on patients requirements in according with current recommendations for enteral feeding.

This prospective study is still on-going. Fifteen patients underwent total laryngectomies in the last year in our hospital. Two patients had preoperative prealbumin < 20 mg/dl and preoperative albumin < 3.5 g/dl, and can be considered malnourished. No patient developed a PCF.

The present study tried to emphasise that nutritional evaluation should always be performed preoperatively. Malnutrition has to be corrected to avoid a complication such as PCF. Our prospective analysis confirms this, although a small case series bias can be present. Moreover, good nutritional status is known to increase the rates of therapy completion, oncologic survival and post-treatment QoL during all types of therapy for head and neck cancer.

Conclusions

It is important to identify the risk factors associated with formation of PCF to improve perioperative management and avoid this complication. In addition to the classical risk factors for PCF highlighted in many studies^{29 30 34}, we must also consider the poor nutritional status of the patient as a risk factor, as assessed by preoperative albumin. Preoperative and periodic postoperative evaluations are mandatory in patients with head and neck cancer. Moreover, for the maintenance of normal haematologic values, frequent biochemical analyses and adequate nutritional support are necessary to prevent PCF following total laryngectomy. A multicentre prospective study is ongoing with the aim of evaluating if the correction of malnutrition can reduce the incidence of PCF in patients with head and neck cancer.

References

- Zbar RIS, Funk GF. *Pharyngocutaneous fistula*. In: *Current therapy in otolaryngology - head and neck surgery*. 6th Edition. Mosby, New York; 1998. p. 314-9.
- Fradis M, Podoshin L, Ben David J. *Post-laryngectomy pharyngocutaneous fistula – a still unresolved problem*. J Laryngol Otol 1995;109:221-4.
- Herranz J, Sarandeses A, Fernández MF, et al. *Complications after total laryngectomy in nonradiated laryngeal and hypopharyngeal carcinomas*. Otolaryngol Head Neck Surg 2000;122:892-8.
- Hier M, Black MJ, Lafond G. *Pharyngo-cutaneous fistulas after total laryngectomy: incidence, etiology and outcome analysis*. J Otolaryngol 1993;22:164-6.
- Ikiz AO, Uça M, Güneri EA, et al. *Pharyngocutaneous fistula and total laryngectomy: possible predisposing factors, with emphasis on pharyngeal myotomy*. J Laryngol Otol 2000;114:768-71.
- Papazoglou G, Doundoulakis G, Terzakis G, et al. *Pharyngocutaneous fistula after total laryngectomy: incidence, cause, and treatment*. Ann Otol Rhinol Laryngol 1994;103:801-5.
- Parikh SR, Irish JC, Curran AJ, et al. *Pharyngocutaneous fistulae in laryngectomy patients: the Toronto Hospital experience*. J Otolaryngol 1998;27:136-40.
- Redaelli de Zinis LO, Ferrari L, Tomenzoli D, et al. *Postlaryngectomy pharyngocutaneous fistula: incidence, predisposing factors, and therapy*. Head Neck 1999;21:131-8.
- Seikaly H, Park P. *Gastroesophageal reflux prophylaxis decreases the incidence of pharyngocutaneous fistula after total laryngectomy*. Laryngoscope 1995;105:1220-2.
- Tsou YA, Hua CH, Lin MH, et al. *Comparison of pharyngocutaneous fistula between patients followed by primary laryngopharyngectomy and salvage laryngopharyngectomy for advanced hypopharyngeal cancer*. Head Neck 201;32:1494-500.
- Saki N, Nikakhlagh S, Kazemi M. *Pharyngocutaneous fistula after laryngectomy: incidence, predisposing factors, and outcome*. Arch Iran Med 2008;11:314-7.
- Lundgren J, Olofsson J. *Pharyngocutaneous fistulae following total laryngectomy*. Clin Otolaryngol Allied Sci 1979;4:13-23.
- Krouse JH, Metson R. *Barium swallow is a predictor of salivary fistula following laryngectomy*. Otolaryngol Head Neck Surg 1992;106:254-7.
- Andrades P, Pehler SF, Baranano CF, et al. *Fistula analysis after radial forearm free flap reconstruction of hypopharyngeal defects*. Laryngoscope 2008;118:1157-63.
- Soylu L, Kiroglu M, Aydogan B, et al. *Pharyngocutaneous fistula following laryngectomy*. Head Neck 1998;20:22-5.
- Virtaniemi JA, Kumpulainen EJ, Hirvikoski PP, et al. *The incidence and etiology of postlaryngectomy pharyngocutaneous fistulae*. Head Neck 2001;23:29-33.
- Palomar-Asenjo V, Sarroca Capell E, Tobías Gómez S, et al. *[Pharyngocutaneous fistula following total laryngectomy. A case-control study of risk factors implicated in its onset]*. Acta Otorrinolaringol Esp 2008;59:480-4.
- Markou KD, Vlachtsis KC, Nikolaou AC, et al. *Incidence and predisposing factors of pharyngocutaneous fistula formation after total laryngectomy. Is there a relationship with tumor recurrence?* Eur Arch Otorhinolaryngol 2004;261:61-7.
- Van der Schueren MA, van Leeuwen PA, Sauerwein HP, et al. *Assessment of malnutrition parameters in head and neck cancer patients and their relation to postoperative complications*. Head Neck 1997;19:419-25.
- Jager-Wittenaar H, Dijkstra PU, Vissink A, et al. *Critical weight loss in head and neck cancer – prevalence and risk factors at diagnosis: an explorative study*. Support Care Cancer 2007;15:1045-50.
- Ravasco P, Monteiro-Grillo I, Vidal PM, et al. *Nutritional deterioration in cancer: the role of disease and diet*. Clin Oncol 2003;15:443-50.
- Matthews TW, Lampe HB, Dragosz KD. *Nutritional status in head and neck cancer patients*. J Otolaryngol 1995;24:87-91.
- De Wys WD, Begg CTLP, Band PR, et al. *Prognostic effect of weight loss prior to chemotherapy in cancer patients*. Am J Med 1980;69:491-7.

- ²⁴ Kristina N, Pichard C, Lochs H. *Prognostic impact of disease-related malnutrition*. Clin Nutr 2008;27:5-15.
- ²⁵ Chiara B, Ciorba A, Stomeo F, et al. *Immunonutrition in head and neck cancer: have a look before surgery!* Eur Arch Otorhinolaryngol 2012;269:5-8.
- ²⁶ Van der Schueren MAEB, von Blomberg A, van der Flier BME, et al. *Differences in immune status between well-nourished and malnourished head and neck cancer patients*. Clin Nutr 1998;17:107-11.
- ²⁷ van der Schueren MAEB, van Leeuwen PAM, Kuik DJ, et al. *The impact of nutritional status on the prognoses of patients with advanced head and neck cancer*. Cancer 1999;86:519-27.
- ²⁸ Brookes GB. *Nutritional status – a prognostic indicator in head and neck cancer*. Otolaryngol Head Neck Surg 1985;93:69-74.
- ²⁹ Erdag MA, Arslanoglu S, Onal K, et al. *Pharyngocutaneous fistula following total laryngectomy: multivariate analysis of risk factors*. Eur Arch Otorhinolaryngol 2013;270:173-9.
- ³⁰ Paydarfar JA, Birkmeyer NJ. *Complications in head and neck surgery: a meta-analysis of postlaryngectomy pharyngocutaneous fistula*. Arch Otolaryngol Head Neck Surg 2006;132:67-72.
- ³¹ Galli J, De Corso E. *Postlaryngectomy pharyngocutaneous fistula: incidence, predisposing factors, and therapy*. Otolaryngol Head Neck Surg. 2005;133:689-94.
- ³² Cavalot AL, Gervasio CF, Nazionale G et al. *Pharyngocutaneous fistula as a complication of total laryngectomy: review of the literature and analysis of case records*. Otolaryngol Head Neck Surg 2000;123:587-92.
- ³³ Dedivitis RA, Ribeiro KC, Castro MA, et al. *Pharyngocutaneous fistula following total laryngectomy*. Acta Otorhinolaryngol Ital 2007;27:2-5.
- ³⁴ Markou KD, Vlachtsis KC, Nikolaou AC, et al. *Incidence and predisposing factors of pharyngocutaneous fistula formation after total laryngectomy. Is there a relationship with tumor recurrence?* Eur Arch Otorhinolaryngol 2004;261:61-7.
- ³⁵ Hanasono MM, Lin D, Wax MK, et al. *Closure of laryngectomy defects in the age of chemoradiation therapy*. Head Neck 2012;34:580-8.
- ³⁶ Fung K, Teknos TN, Vandenberg CD, et al. *Prevention of wound complications following salvage laryngectomy using free vascularized tissue*. Head Neck 2007;29:425-30.
- ³⁷ Dirven R, Swinson BD, Gao K, et al. *The assessment of pharyngocutaneous fistula rate in patients treated primarily with definitive radiotherapy followed by salvage surgery of the larynx and hypopharynx*. Laryngoscope 2009;119:1691-5.
- ³⁸ Dedivitis RA, Aires FT. *Stapler suture of the pharynx after total laryngectomy*. Acta Otorhinolaryngol Ital 2014;34:94-8.
- ³⁹ Morton RP, Fielder CP, Dorman EB. *Prediction and prevention of fistulae after major head and neck surgery: a preliminary report*. Aust N Z J Surg 1988;58:951-3.
- ⁴⁰ Head and Neck Guideline Steering Committee. *Evidence based practice guidelines for the nutritional management of patients with head and neck cancer*. Sydney: Cancer Council Australia. Available from: [http://wiki.cancer.org.au/australia/COSA:Head and neck cancer nutrition guidelines](http://wiki.cancer.org.au/australia/COSA:Head_and_neck_cancer_nutrition_guidelines).
- ⁴¹ Weimann A, Braga M, Harsanyi L, et al. *ESPEN Guidelines on Enteral Nutrition: Surgery including organ transplantation*. 2006;Clin Nutr 25:224-44.

Received: January 10, 2015 - Accepted: April 30, 2015

Address for correspondence: Margherita Bettini, University Hospital of Modena, Department Head and Neck Surgery, Institute of Otorhinolaryngology, via del Pozzo 71, 41124 Modena, Italy. Tel. +39 059 4222402. Fax +39 059 4222454. E-mail: bettini.margherita@libero.it

OTOLOGY

Musical training software for children with cochlear implants

Software di training musicale per bambini con impianto cocleare

W. DI NARDO, L. SCHINAIA, R. ANZIVINO, E. DE CORSO, A. CIACCIARELLI, G. PALUDETTI

Institute of Otorhinolaryngology, Catholic University of the Sacred Heart, "A. Gemelli" University Hospital, Rome, Italy

SUMMARY

Although the voice in a free field has an excellent recruitment by a cochlear implant (CI), the situation is different for music because it is a much more complex process, where perceiving the pitch discrimination becomes important to appreciate it. The aim of this study is to determine the music perception abilities among children with CIs and to verify the benefit of a training period for specific musical frequency discrimination. Our main goals were to prepare a computer tool for pitch discrimination training and to assess musical improvements. Ten children, aged between 5 and 12 years, with optimal phoneme recognition in quiet and with no disabilities associated with deafness, were selected to join the training. Each patient received, before training period, two types of exams: a pitch discrimination test, consisting of discovering if two notes were different or not; and a music test consisting of two identification tasks (melodic and full version) of one music-item among 5 popular childhood songs. After assessment, a music training software was designed and utilised individually at home for a period of six months. The results following complete training showed significantly higher performance in the task of frequency discrimination. After a proper musical training identification, frequency discrimination performance was significantly higher ($p < 0.001$). The same considerations can be made in the identification of the songs presented in their melodic ($p = 0.0151$) and full songs version ($p = 0.0071$). Cases where children did not reach the most difficult level may be due to insufficient time devoted to training (ideal time estimated at 2-3 hours per week). In conclusion, this study shows that it is possible to assess musical enhancement and to achieve improvements in frequency discrimination, following pitch discrimination training.

KEY WORDS: Cochlear implants • Music perception • Speech perception • Children • Music Test battery

RIASSUNTO

Gli attuali impianti cocleari forniscono buoni segnali temporali e grossolane indicazioni spettrali. In generale queste proprietà sono sufficienti per la percezione di un discorso in condizioni di quiete e per l'acquisizione del linguaggio nei bambini piccoli. Tuttavia esse risultano essere inadeguate per la trasmissione della moltitudine di pitch della musica. Lo studio si propone come obiettivi la determinazione delle abilità di percezione della musica nei bambini portatori di impianto cocleare e la verifica dei benefici di un periodo di training musicale specifico per la discriminazione frequenziale. In particolare abbiamo proposto un allenamento alla discriminazione delle note musicali, secondo un metodo da noi sviluppato attraverso un supporto computerizzato. Sono stati inclusi nello studio 10 bambini portatori di impianto cocleare di età compresa tra i 5 e i 12 anni senza disabilità associate alla sordità. Tutti i soggetti avevano un'ottima comprensione dei fonemi in ambiente silenzioso. Ogni paziente nel periodo precedente al Training è stato sottoposto a due tipi di esame: un test di discriminazione del pitch, che consiste nel riuscire ad identificare come differenti due note musicali pur in condizioni di crescente difficoltà (da 1 ottava ad 1 semitono), e un Music Test costituito da due prove di identificazione, Melodica e Strumentale completa. Il materiale del Music Test era costituito dai 5 canzoni popolari per l'infanzia, sintetizzate con il software Finale 2008™ (Makemusic Inc. Eden Prairie, MN). I brani, ciascuno della durata di 30 secondi, erano simili per il ritmo e venivano presentati in due modalità differenti: una versione melodica suonata al pianoforte senza accompagnamento orchestrale e parole cantate, ed una versione completa della canzone, che include l'accompagnamento dell'orchestra e le parole cantate. Il Training consisteva in un allenamento guidato da un programma che veniva fornito su supporto informatico ad ogni paziente, della durata di 6 mesi con allenamento almeno bisettimanale. I risultati ottenuti evidenziano che tutti i bambini sono migliorati nel training di discriminazione frequenziale ($p < 0,0001$). Per eliminare la possibilità che questo progresso potesse essere dovuto al caso o ad altri fattori si è applicata un'analisi statistica t-Student ad una coda per dati appaiati per verificarne la significatività. Le prestazioni al test di identificazione di item musicali sia nella versione melodica che in quella completa sono risultate significativamente superiori al livello casuale con un $p < 0,05$. I risultati ottenuti mostrano performance significativamente superiori nel compito di discriminazione frequenziale successivamente all'esecuzione del Training. Infatti prima del training 2 bambini si posizionavano al 1° livello (discriminazione frequenziale di 12 semitoni), 3 bambini al 2° livello (discriminazione frequenziale di 10 semitoni), 4 bambini al 3° livello (discriminazione frequenziale di 8 semitoni) e 1 bambino al 5° livello (discriminazione frequenziale di 4 semitoni), mentre dopo il training, 2 bambini si collocavano uno al 4° e uno al 5° livello, 5 bambini al 6° livello e i restanti 3 bambini al 7° ed ultimo livello. Dal nostro studio emerge quindi come sia possibile, in seguito ad un allenamento specifico con materiale dedicato, ottenere dei significativi miglioramenti nella discriminazione frequenziale permettendo anche ai soggetti impiantati di apprezzare meglio il mondo della musica.

PAROLE CHIAVE: Impianto cocleare • Percezione linguistica • Ascolto della musica • Bambini • Test musicale

Introduction

In recent years, advancements in cochlear implant (CI) technology has allowed the device to achieve its primary goal, that is to restore a near-normal speech understanding in profoundly deaf subjects, at least in favourable listening conditions^{1,2}. New signal processing strategies have brought benefits for CI users in terms of perception. Technological innovations in CI systems, enabled functional hearing, oral speech and language achievements in many children with pre-lingual severe-to-profound hearing impairment. Nonetheless, CIs still provide poorer auditory information than those conveyed through an intact natural cochlea.

One of the main weaknesses of the latest generation CIs appears to be the limited number of active channels, too low to allow an appropriate encoding of detailed spectral information, which is crucial to give perceptual accuracy of melody pitch patterns³ (Fig. 1a, b). Moreover, most of the current processing strategies remove fine temporal structure information from stimulus waveforms, therefore limiting the users' ability to extract pitch cues from temporal components of the signal⁴. In fact, CI encoding signal algorithms generally fail in reproducing higher order harmonics. Preservation of tonotopicity is crucial in CI-mediated music understanding, mainly because it

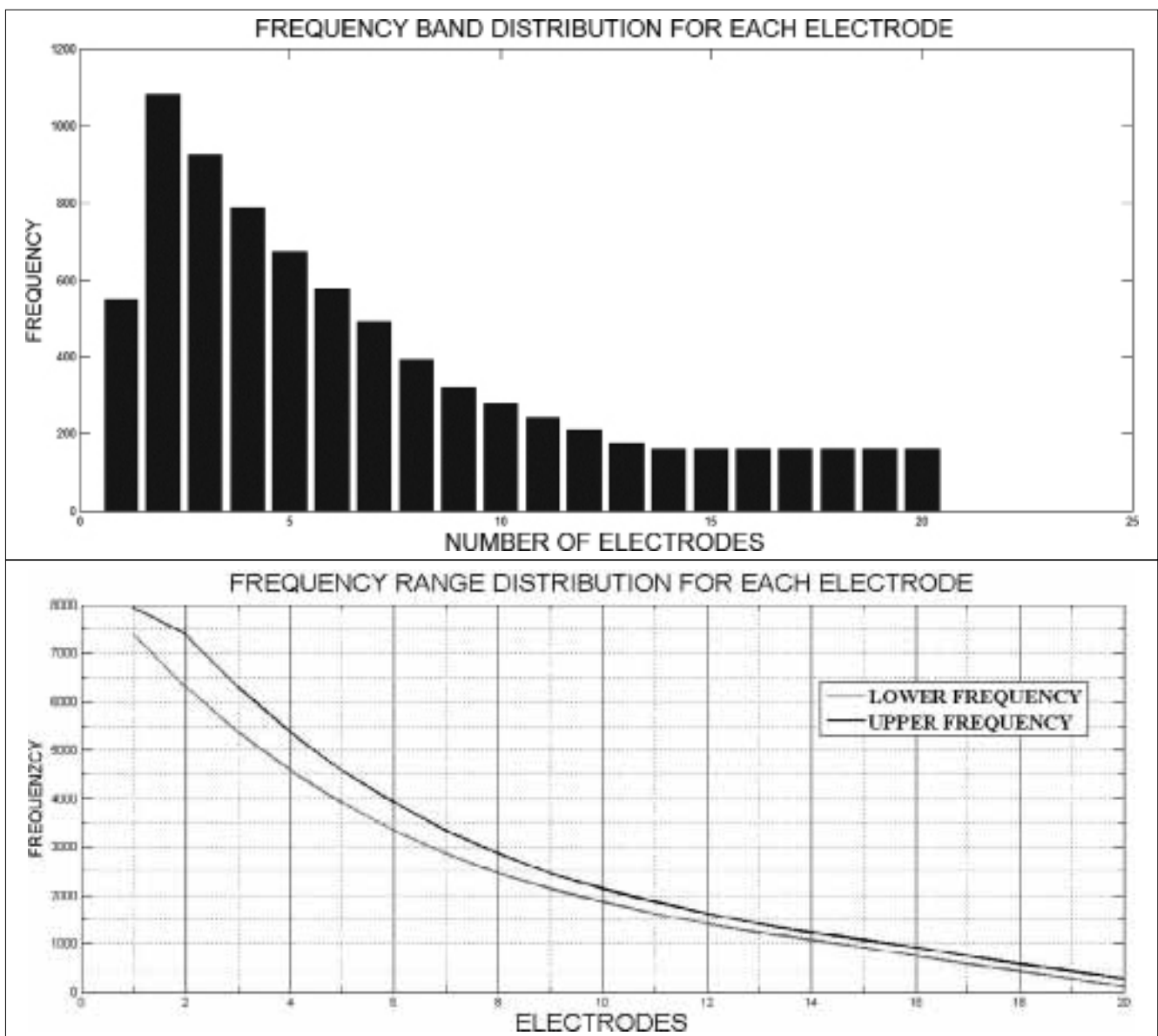


Fig. 1a-b. Distribution of frequency bands of the strategy encodes. Histogram shows the distribution of frequency bandwidths on each electrode, which is in proportion to the cochlear tonotopicity following the placement of the electrodes. The second curve represents the frequency range transduced by the implant according to the distribution of the bands set in the histogram. Data were extrapolated from the stimulation of the mapping software of the processor for each patient. In this case, it shows the frequency distribution of patient C1.

demands an absolute fidelity of signal transduction, while there is mounting evidence that the tonotopic representation of frequencies through the CI is often distorted due to a poor correspondence between the frequency bands allocated to the electrodes, according to the conventional frequency maps, and the pitch elicited by stimulation of the same electrodes. Thus, fundamental frequencies – and consequently harmonics – cannot be efficiently extracted and properly decoded, due to the mismatch between electrode-assigned frequencies and pitch⁵⁻⁷.

It is widely accepted that music and speech are the most complex sound features produced by the human species. These two processes have similar properties and central processing, albeit analysed in different human brain areas. The inter-hemispheric domains of music and speech allow psychosocial and cognitive skills development in communication⁸. The “musician effect” persists under degraded pitch condition of CI simulation and may offer advantages in pitch processing⁹. Studies with normal-hearing people showed that musical training can improve pitch recognition: musician children detect pitch variations in both music and language much more accurately¹⁰⁻¹² and rapidly¹³ than non-musician peers¹⁴. Although the voice in a free field has an excellent recruitment by the CI, the situation is different concerning musical sounds because it is a much more complex process, where perceiving the higher order harmonics becomes important to appreciate it. Many studies have shown that some CI recipients are quite able to perceive features such as tempo and rhythm¹⁵, but the extent of this perception is variable^{16,17}. Other papers have focused on pitch processing skills due to their immediate relevance to music perception¹⁸⁻²². In some of these studies, familiar melodies have been recognised from a closed set^{19,23}, whereas in others simple melodic contours have been discriminated²⁴. The results indicate that melody perception is generally poor in CI users, again considering a large inter-individual variability. Several studies have examined the accuracy of different devices and coding strategies on melody and speech in noise perception,

concluding that there are statistically significant correlations between pitch ranking and familiar melody recognition²⁵. Children with CIs have greater difficulties in recognising familiar songs when these melodies are without words²⁶. Recent research demonstrated that there is a correlation between music perception and phonological and reading process skills; the same authors hypothesised that some music characteristics (such as rhythm and pitch) are associated with some speech perception parameters²⁷. However, standardised methods for assessing music perception in patients with CI are lacking²⁸. Yucel et al.²⁹ found that musical training is an effective rehabilitation tool for auditory perception improvement. In particular, one of the most relevant points of this work is the ability to subject children to this training without requiring them any additional efforts, thanks to the possibility to perform the exercises at patient’s home, by themselves or with the help of a family member if the subjects were too young. The authors stated that submitting children to musical exercises – such as pitch discrimination test between two notes – leads to improvements in spoken language perception. Dastgheib proposed a new music training program based on language development to optimise speech and language skills³⁰. These findings show that the CI alone does not satisfy all patients’ needs, and that speech therapy and specific training may be proper and necessary in order to maximise CI benefits.

The purpose of the present investigation is to determine whether children with CIs can benefit from training on pitch and music perception in terms of pitch discrimination; moreover, if pitch perception can be trained, it could also lead to improvements in speech perception and in music enjoyment.

Materials and methods

Subjects

Ten children (6 boys and 4 girls), monaurally Nucleus™ CI users (Table I), who periodically came to our ENT

Table I. Background information of the study group. Age, age of deafness onset, and duration of CI usage variables are all expressed in the unit of “years”.

Subject	Background information					
	Age	Aetiology	Onset age	Duration of CI	Deafness	Side of CI
C 1	12	Idiopathic	4	8	Pre-verbal	Right
C 2	6	Idiopathic	2	4	Pre-verbal	Right
C 3	11	Waardenburg Syndrome	2	9	Pre-verbal	Left
C 4	8	Homozygous for connexin 26 mutation	3	5	Pre-verbal	Right
C 5	12	Idiopathic	3	9	Pre-verbal	Right
C 6	12	Idiopathic	4	8	Pre-verbal	Right
C 7	12	Idiopathic	6	6	Post-verbal	Right
C 8	11	Idiopathic	4	7	Pre-verbal	Right
C 9	5	Heterozygous for connexin 26 mutation	2	3	Pre-verbal	Right
C 10	6	Idiopathic	2	4	Pre-verbal	Right

Table II. Main features of speech processor settings.

Subject	Processor	Implant	Device- features				
			Maxima	Channel stimulation rate	Strategy	Pulse width	Total frequency
C 1	Freedom SP	CI24R (CS)	8	900	ACE	25	7200
C 2	Freedom SP	CI24RE (CA)	10	2400	ACE (RE)	12	24000
C 3	Freedom SP	CI24R (CS)	8	250	SPEAK	25	2000
C 4	Freedom SP	CI24RE(CA)	8	900	ACE	25	7200
C 5	Freedom SP	CI24R (CS)	8	900	ACE	25	7200
C 6	ESPrIt 3G	CI24R (CS)	8	900	ACE	25	7200
C 7	Freedom SP	CI24RE (CA)	10	2400	ACE (RE)	12	24000
C 8	ESPrIt 3G	CI24R (CS)	8	900	ACE	25	7200
C 9	Freedom SP	CI24RE (CA)	8	900	ACE	25	7200
C 10	Freedom SP	CI24RE (CA)	10	2400	ACE (RE)	12	7200

clinic to perform speech processor fitting, were recruited. Children were aged between 5 and 12 years and had no disability associated with deafness. Mean chronological age was 117 ± 36 months, while mean hearing age (i.e. months of CI use) was 77 ± 26 months. These subjects had bilateral hearing loss and regularly used conventional hearing aids until CI implantation. All these patients had been using a Nucleus™ CI device for at least 6 months: 5 had a perimodiolar electrode (CI24RE-CA) and 5 had a straight, non-perimodiolar electrode (CI24R-S). At the time the study took place, 8 of the 10 Nucleus™ CI recipients were using a Freedom™ speech processor and 2 were fitted with an ESPrIt 3G™ speech processor. Six had been using an ACE™ strategy with a 900 pps stimulation rate and 25 μ s pulse width, 3 patients had been using an ACE™ (RE) strategy with a 2400 pps stimulation rate and 12 μ s pulse width and the last one using SPEAK strategy with a 250 pps and 25 μ s (Table II). During the month preceding the test session, all speech processors were fitted so that all patients could receive comfortable stimulation. Impedance measurement and neural response telemetry (NRT™ for Nucleus™ recipients) were performed for all electrodes in each subject. As soon as it was possible, all subjects were enrolled in the auditory-musical training program of the Catholic University of Sacred Heart in Rome. None of the patients had been attending music classes at school, nor they had been taking part in any formal music training activity, so that they belonged to musical experience level “1” according to Looi³¹. Before introducing our test battery to CI subjects, we checked its validity on 10 normal hearing patients, all of them scoring between 95 and 100% in the Music Training Program based on Musical Pitch Discrimination (MPD) test.

Music test battery

A music test battery was designed in order to assess CI-mediated perception of music. It included a *Music Training Software* based on MPD, and a *Music Test*. In the pitch

discrimination test, stimuli consisted in pairs of notes played by a piano and distanced by at least one semitone (approximately 6% F0 difference), being the semitone the smallest interval size in traditional Western music. The notes were distributed within the three central octaves (C4, C5, C6, each matching with the following frequency bands: 262 Hz-523 Hz, 523 Hz-1046 Hz and 1046 Hz-1976 Hz), used for most of the songs, for a total of 36 notes. After listening to each pair of notes, the patient was asked to indicate which one was higher in pitch.

- *Music training software.* This software is designed to reproduce the melodic exercises of musical pitch discrimination: patients can perform exercises at home as shown in the present study. The Home-Learning Program is composed of several interfaces and levels of increasing difficulty. According to the test, subjects listen to 2 musical notes, and then say if the pair is made of the same or different sounds. The notes were played by a piano and, as in the previous test, lay between the 4th and 6th octave. Each pair was then recorded (sampling at 40 KHz), reproduced from the Home-Learning Program and delivered to the listener, sitting one meter away from a loudspeaker, sending a stimulus at 70 dB nHL. The software Home-Learning Program was installed on an IBM™ computer, which was routinely used to fit patients' maps in routine fitting sessions. The levels were 7, with increasing difficulty, determined by reducing the distance between notes: the 1st level comprised pairs of notes 12-semitones apart (easiest task), while the 7th level included notes one semitone apart (most difficult task; Table III). The test aimed to assess children's frequency discrimination in the frequency domain 262-1976 Hz. For each level, one pair of musical notes was administered: children had to say if the two tones were different or the same. Each level is further divided into two tests:
 - TEST A: composed of two parts (each of 10 questions) in which the subject had to choose between 2 notes belonging to the 5th and 6th musical octave (523-1976 Hz).

Table III. The levels are divided into 7 categories of increasing difficulty. The difficulty is determined by the distance in frequency between notes played.

Level	Degree of difficulty
Level 1	12 semitones
Level 2	10 semitones
Level 3	8 semitones
Level 4	6 semitones
Level 5	4 semitones
Level 6	2 semitones
Level 7	1 semitone

- **TEST B:** consists of two parts (each of 10 questions) in which the subject had to choose between 2 notes belonging to the 4th and 5th musical octave (262- 988 Hz). In the last 2 levels (6th and 7th level) there are 20 more questions test that investigate discrimination on mid-range (linked to the 5th octave). The software was programmed to go to the next, harder level once 8 correct answers of 10 were obtained. The threshold of 8 correct answers was planned conforming to the Theorem Bernoulli Trials. The Home-Learning Program was given to study members' families; they were asked to set aside time (at least 2 hours weekly) to practice at home for a 6-month period. Parents had to teach children how to use the software.
- **Music Test.** The music test aims to assess children's identification skills in a closed set of music items. It is composed of 5 childhood songs in digital recording, synthesised with Finale™ 2008 (MakeMusic Inc., Eden Prairie, MN). The tunes were presented at 70 dB-nHL, coming from two frontal loudspeakers one metre apart from the CI recipient. Prior to test execution, subjects were conditioned to look at a specific cartoon movie linked to each song from an IBM laptop® (IBM, Armonk, USA). Each song is presented twice, for a total of 10 items. During testing, children sat in front of a screen showing the most representative characters for each of the previously seen cartoons. The music test is divided in two sessions: in session 1, full version songs (instrumental plus vocal), as those presented in the preliminary training, were played twice randomly, for a total of 10 items. Children had to indicate the distinctive character on the screen for each song. In session 2, children were exposed to the melodic version songs, presented twice in a random order for a total of 10 musical items. An overall score was calculated on the basis of the items correctly identified.

All children carried out an initial test to define the baseline music performances (musical pitch discrimination + music test). They then followed the specific musical training program, and eventually performed a final test with the same initial workup to evaluate possible improvement due to training.

Statistical analysis

We used a Kolmogorov-Smirnov test (K-S test) to compare a sample with a reference probability distribution, a paired t-Student statistic test to determine whether there were differences between two means or between a target value and a calculated mean, and used the Mann-Whitney U test, a non-parametric statistical test, when the distribution of samples did not respect of K-S test condition. A linear regression model according to Spearman's rank and Pearson's coefficient was used for correlations. Significance was set at $p < 0.05$.

Results

Training is based on a frequency discrimination task. Results were obtained comparing performances on MPD and music tests before and after the 6-month training period.

MPD results

Scores achieved after musical training showed significantly higher performance in frequency discrimination tasks than before training. At the baseline assessment, 2 children reached level 1 (frequency discrimination threshold of 12 semitones), 3 children reached level 2 (frequency discrimination threshold of 10 semitones), 4 children level 3 (frequency discrimination threshold of 8 semitones) and 1 child got to level 5 (frequency discrimination threshold of 4 semitones). Conversely, at the final assessment, 1 children came up to level 4, 1 to level 5, 5 children to level 6 (frequency discrimination threshold of 2 semitones) and the remaining 3 children got to the 7th and final level (frequency discrimination threshold of 1 semitone). Patients who reached last and hardest discrimination level (P3, P5 and P6) showed a proportional improvement in melody test scores (Figure 2): this suggests that these patients have higher frequency resolution than other CI children, but not comparable to that of normal hearing peers. In fact, children in the control group performed the MPD test without committing any error. The results showed that all children improved after training, each having reached more advanced level (almost up to the highest level). Statistical analysis was performed to rule out bias such as chance level; the Box-Plot and histogram show the significant difference in performances ($p < 0.0001$) obtained before and after training (Figs. 3, 4).

Music test results

There was an improvement in performances in both the melodic (Fig. 5a-b) and full (Fig. 6a-b) versions of the test comparing pre- and post-training assessments. In both cases, we found a significant difference between pre- and post-training scores $p = 0.0151$ for the melodic version and $p = 0.0071$ for the full song version).

On the other hand, there was no significant correlation between melodic and full version identification skill improve-

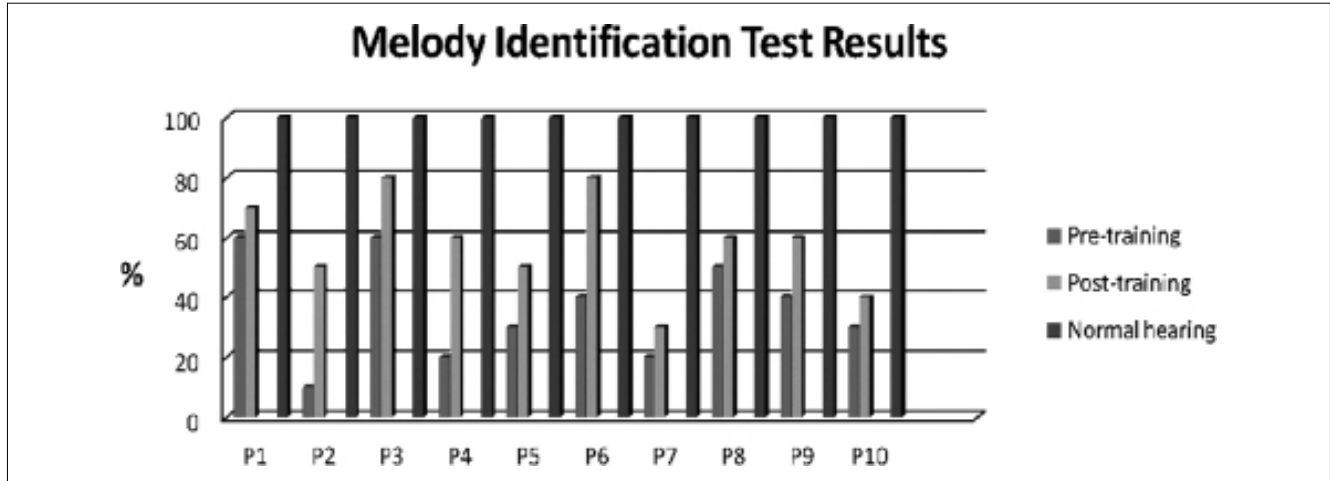


Fig. 2. Comparison between overall scores before and after musical training in the music test. We checked the validity of the melody and full version test, on 10 normal hearing patients, all of whom scored between 95 and 100%.

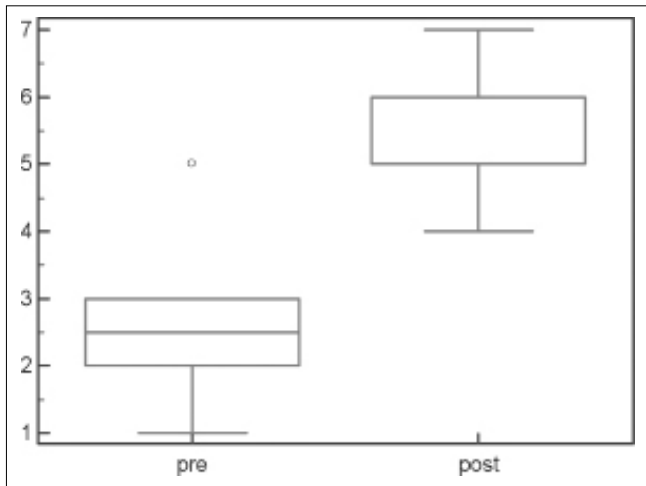


Fig. 3. Box plot of results: The box-plot represents the distribution of levels, of the MPD test, achieved by patient, before and after musical training ($p < 0.0001$).

ments and stimulation strategy parameters, such as pulse width ($r^2 = 0.33$, $p = 0.102$) and maxima ($r^2 = 0.36$, $p = 0.10$).

Discussion

Music is a challenging task that is generally more difficult than conventional speech. Music is also a powerful tool in auditory training in children with CIs because it is an integral part of human natural environment. Music perception by CI recipients is hard because most common signal-processing strategies fail in transmitting effective pitch information³². The underlying causes may be several: current CI processing strategies, which are more operative in preserving envelope cues but do not convey fine structure cues associated with good pitch perception; neural damage, that can limit the discrimination rate in some CI recipients; the limited electrode number; the abnormal frequency-coding

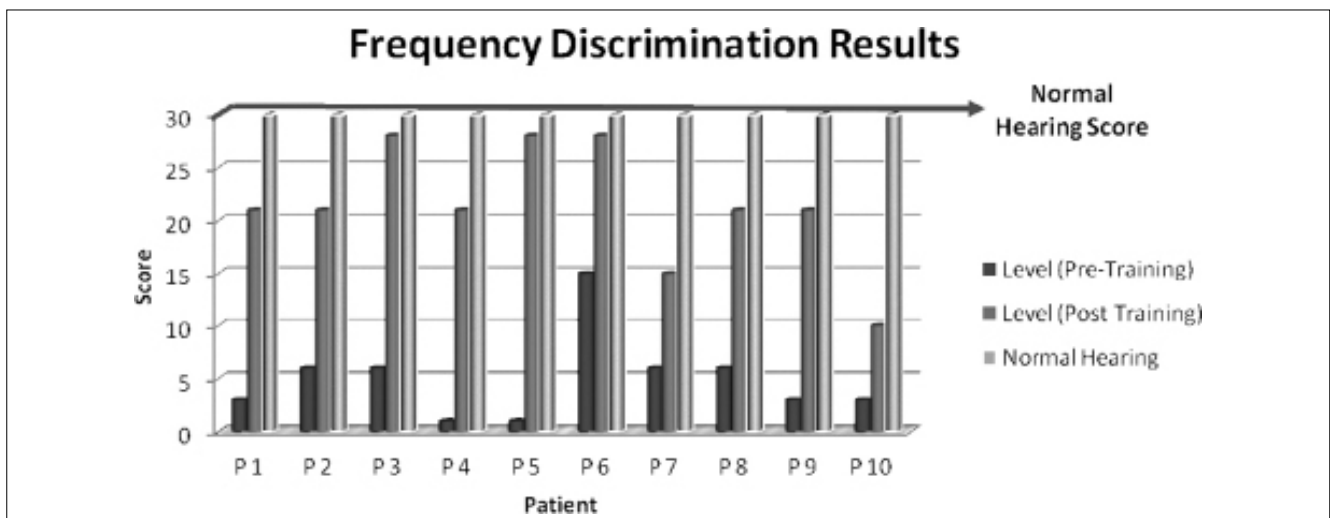


Fig. 4. Comparison between scores before and after musical training in the MPD test. We checked the validity of music training program, based on the MPD test, on 10 normal hearing patients, all of whom achieved the 7th level without any problem.

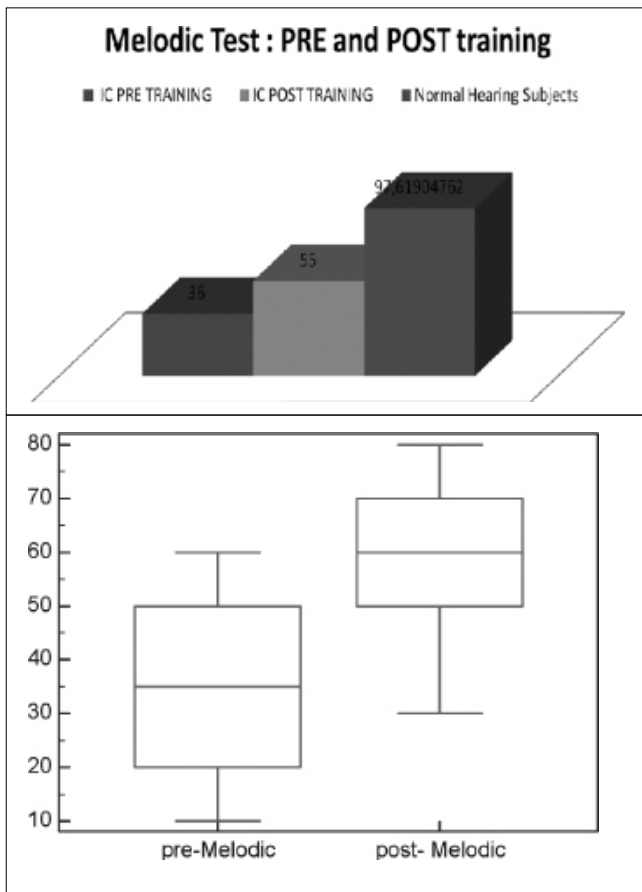


Fig. 5a-b. Music Test – Melodic version: representation of pre- and post-training score mean, in comparison with normal hearing subjects. The box-plot shows the distribution of score ($p = 0.0151$).

resolution resulting from the tonotopicity destructuring in the auditory cortices of prelingually deafened children; another is due mismatch, or rather, misalignment between the conventional frequency band allocation to the electrodes of the array (frequency-place function) and the distribution of pitch percepts generated by electrode stimulation along the array (electrode-pitch function)³²⁻³⁴.

We provided the children with a compact disc (CD) containing frequency discrimination exercises divided into increasing difficulty levels and assessed their performances before and after training.

Melody Identification Test. Comparison between normal hearing and implanted children revealed a significantly lower performance of the latter. These findings are consistent with known CI users' pitch perception problems due to:

- A limited number of intracochlear electrodes, which seem to be enough to convey speech information, but inadequate to distinguish two notes one semitone apart. Theoretically, 88 different electrodes would be required to provide a complete representation of the entire piano keyboard; currently, this is not possible because of physical limitations imposed by electrical interferences

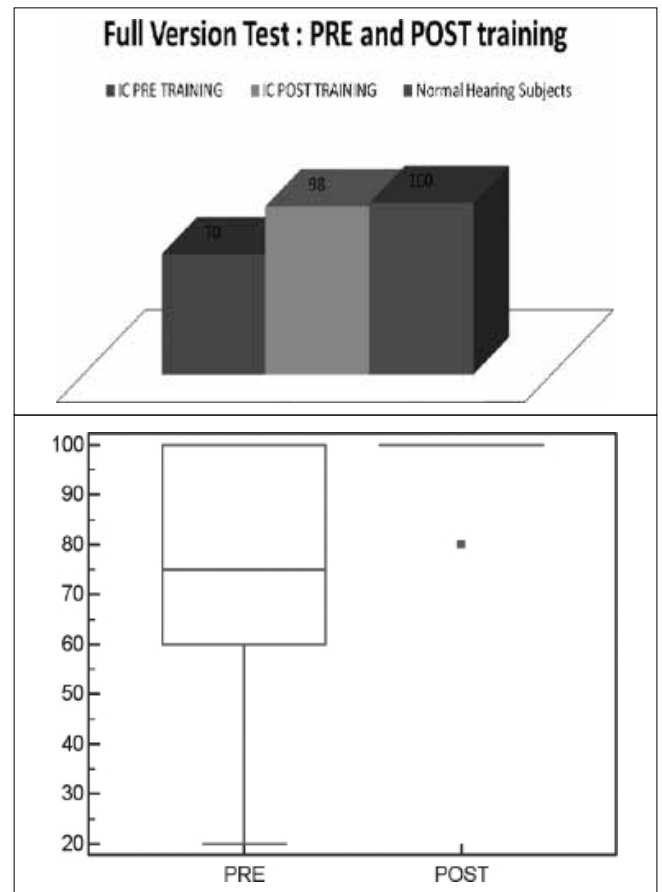


Fig. 6a-b. Music Test – Full songs version: representation of pre- and post-training score mean, in comparison with normal hearing subjects. The box-plot shows the distribution of score. ($p = 0.0071$).

among electrodes. This problem could be partly overcome by “virtual electrodes” that create intermediate pitch sensations³⁵; of course they should be made active, not all randomly, but only the virtual channels can determine pitch sensation effective and distinct from other, in order to avoid interference and confusion in listening.

- Misalignment phenomena between the conventional frequency bands located on the array and the perceived pitch³⁶. A recent study³³ showed that the mismatch correction can lead to improvement in melodic identification skills in adult CI patients.

After specific musical training, the identification abilities of CI patients became higher even if not comparable to those of normal hearing children. This is consistent with the work of Gantz et al.³⁷ where they demonstrated that musical abilities in children with CIs can improve after perception training.

Full songs Identification Test. The results suggest the same considerations made for melody identification. In this case, children performed better during the baseline assessment. This seems to be consistent with previous papers reporting best musical skills through the use of lyr-

ics: in fact, in the complete songs identification test, the CI group performed quite similar to the control group. Frequency Discrimination. The strength of this study was to give the chance to perform the MPD test directly at the patients' home. From this experience, we highlight several important issues:

- objective improvement of music perception in CI children (melodic and full songs identification test);
- subjective improvement (parents referred to clinicians that their children were more comfortable listening to music than in the past);
- the possibility of self-training (which allows the child to perform the training in a comfortable environment and to correct his mistakes by himself);
- the chance to train with family and to be assisted in performing the test where needed.

Higher scores in pitch perception test positively correlated with a longer duration of musical training in implanted children. Our finding is consistent with a previous study, in which structured training was suggested to obtain positive correlation with recognition and appraisal of musical pitch discrimination by postlingually deafened cochlear implant recipients³³. After six months of training, our CI recipients showed significant improvements in pitch recognition and appraisal compared to the control group. Some mechanisms underlying the enhanced performance of pitch perception after musical training in the prelingually deafened CI children may be proposed. One explanation is the modification of disorganised tonotopy through the effect of auditory plasticity in the central auditory pathway of our subjects. The reinstatement of afferent input via cochlear implantation could consequently launch a cascade of plastic changes in the auditory system. Such reorganisation, probably coupled with essential changes in neurotransmission or neuromodulation, might lead to reduction of further deterioration in the central nervous system resulting from the interruption of electrical and nutritional input due to cochlear damages^{38,39}. This might reverse the disrupted tonotopic maps toward a relatively normal organisation⁴⁰. In normal hearing children, improved music perception via music education has been demonstrated by increased auditory evoked fields, possibly due to a greater number and/or synchronous activity of neurons⁴¹. With the intervention of musical training, it seems likely that the modified tonotopy organisation of our prelingually deafened children could be further optimised for a more precise resolution of frequency spectrum, as is indexed by a better performance of pitch perception.

Conclusions

At present, however, no one can truly know how CI users with preverbal deafness perceive the musical melody. There is no doubt that as long as we do not find an effective solution to the lack of frequency discrimination and mismatch, these patients may not appreciate the beauty of

music, even if they are able to recognise different songs. Nowadays, no codified procedure for a standardised music assessment nor specific musical training is available, especially for hearing impaired children.

In this paper, we present a completely new tool to train CI children in pitch discrimination and melody identification tasks. We found a significant difference between pre- and post-training scores in the full version test ($p = 0.0071$), melodic test ($p = 0.0151$) and frequency discrimination test (0.0001). In the light of our findings, we can conclude that it is possible to achieve improvements in frequency discrimination and song recognition following specific perceptual training in prelingually deafened CI children.

References

- ¹ Berrettini S, Baggiani A, Bruschini L, et al. *Systematic review of the literature on the clinical effectiveness of the cochlear implant procedure in adult patients*. Acta Otorhinolaryngol Ital 2011;31:299-310.
- ² Forli F, Arslan E, Bellelli S, et al. *Systematic review of the literature on the clinical effectiveness of the cochlear implant procedure in paediatric patients*. Acta Otorhinolaryngol Ital 2011;31:281-98.
- ³ Kong YY, Cruz R, Jones JA, et al. *Music perception with temporal cues in acoustic and electric hearing*. Ear Hear 2004;25:173-85.
- ⁴ McKay CM, Henshall KR, Hull AE. *The effect of rate stimulation on perception of spectral shape by cochlear implantees*. J. Acoust. Soc Am 2005;118:386-92.
- ⁵ Di Nardo W, Scorpecci A, Giannantonio S, et al. *Cochlear implant patients' speech understanding in background noise: effect of mismatch between electrode assigned frequencies and perceived pitch*. J. Laryngol. Otol 2010;124:828-34.
- ⁶ Di Nardo W, Cantore I, Marchese MR, et al. *Electric to acoustic pitch matching: a possible way to improve individual cochlear implant fitting*. Eur Arch Otorhinolaryngol 2008;265:1321-8.
- ⁷ Boex C, Baud L, Cosendai G, et al. *Acoustic to electric pitch comparisons in cochlea implant subjects with residual hearing*. J Assoc Res Otolaryngol 2006;7:110-24.
- ⁸ Oxenham AJ, Bernstein JG, Penagos H. *Correct tonotopic representation is necessary for complex pitch perception*. Proc Natl Acad Sci U S A 2004;101:1421-5.
- ⁹ Fuller CD, Galvin JJ, Bertmaat, et al. *The musician effect: does it persist underdegraded pitch conditions of cochlear implant simulations?* Frontiers in Neuroscience 2014;8;(Article 179):1-16.
- ¹⁰ Besson M, Schon D, Moreno S, et al. *Influence of musical expertise and musical training on pitch processing in music and language* 2007;25:399-410.
- ¹¹ Magne C, Schon D, Besson M. *Musician children detect pitch violations in both music and language better than non-music children: behavioral and electrophysiological approaches*. J Cogn Neurosci 2008;18:199-211.
- ¹² Musacchia G, Sams M, Skoe E, et al. *Musicians have enhanced subcortical auditory and audiovisual processing of speech and music*. Proc Natl Acad Sci U S A 2007;104:15894-8.

- ¹³ Tervaniemi M, Castaneda A, Knoll M, et al. *Sound processing in amateur musicians and nonmusicians: event-related potential and behavioral indices*. *Neuroreport* 2006;31;17:1225-8.
- ¹⁴ Gaab N, Tallal P, Kim H, et al. *Neural correlates of rapid spectrotemporal processing in musicians versus non-musicians*. *Ann NY Acad Sci* 2005;10060:82-8.
- ¹⁵ Gfeller K, Lansing CR. *Melodic, rhythmic, and timbral reception of adult cochlea implant users*. *J Speech Hear Res* 2005;34:916-20.
- ¹⁶ Galvin JJ II, Fu OJ, Nogaki G. *Melodic contour identification by cochlear implant listeners*. *Ear Hear* 2007;28:302-19.
- ¹⁷ Cooper WB, Tobey E, Loizou PC. *Music perception by cochlear implant and normal hearing listeners measured by the Montreal battery for evaluation of amusia*. *Ear Hear* 2008;29:618-26.
- ¹⁸ Kong YY, Cruz R, Jones JA, et al. *Music perception with temporal cues in acoustic and electric hearing*. *Ear Hear* 2004;25:173-85.
- ¹⁹ Zeng FG, Tang Q, Lu T. *Abnormal pitch perception produced by cochlear implant stimulation*. *Plos One* February 2014;9:e88662.
- ²⁰ Looi V, McDermott H, McKay C, et al. *Music perception of cochlear implant users compared with that of hearing aid users*. *Ear. Hear* 2008;29:421-34.
- ²¹ Pressnitzer D, Bestel J, Fraysse B. *Music to electric ears: pitch and timbre perception by cochlear implant patients*. *Ann NY Acad Sci* 2005;1060:343-5.
- ²² Singh S, Kong YY, Zeng FG. *Cochlear implant melody recognition as a function of melody frequency range, harmonicity, and number of electrodes*. *Ear Hear* 2009;30:160-8.
- ²³ Fujita S, Ito J. *Ability of nucleus cochlear implantees to recognize music*. *Ann Otol Rhinol Laryngol* 1991;108:634-40.
- ²⁴ Sucher CM, Mc Dermott HJ. *Pitch ranking of complex tones by normally hearing subjects and cochlear implant users*. *Hear Res* 2007;230:80-7.
- ²⁵ Gfeller K, Turner C, Oleson J, et al. *Accuracy of cochlear implant recipients on pitch perception, melody recognition, and speech perception in noise*. *Ear Hear* 2007;28:412-23.
- ²⁶ Stordahl J. *Song recognition and appraisal: a comparison of children who use cochlear implants and normally hearing children*. *J. Music Ther* 2002;39:2-19.
- ²⁷ Anvari SH, Trainor LJ, Woodside J, et al. *Relations among musical skills, phonological processing, and early reading ability in preschool children*. *J Exp Child Psychol* 2002;83:111-30.
- ²⁸ Roy A, Scattergood-Keeper L, Carver C, et al. *Evaluation of a test battery to assess perception of music in children with cochlear implants*. *JAMA Otolaryngol Head Neck Surg*. 2014 Apr 10. [Epub ahead of print].
- ²⁹ Yucel E, Sennaroglu G, Belgin E. *The family oriented musical training for children with cochlear implants: Speech and musical perception results of two year follow-up*. *Int J Pediatr Otorhinolaryngol* 2009;73:1043-52.
- ³⁰ Dastgheib SS, Riyassi M, Anvari M, et al. *Music training program: a method based on language development and principles of neuroscience to optimize speech and language skills in hearing-impaired children*. *Iran J Otorhinolaryngol* 2013;25:91-5.
- ³¹ Looi V, Winter P, Anderson I, et al. *A music quality rating test battery for cochlear implant users to compare the FSP and HDCIS strategies for music appreciation*. *Int J Audiol* 2011;50:503-18.
- ³² Gfeller K, Wilson BS, Schatzer R, et al. *Two new directions in speech processor design for cochlear implants*. *Ear Hear* 2005;26:73-81.
- ³³ Di Nardo W, Scorpecci A, Giannantonio S, et al. *Improving melody recognition in cochlear implant recipients through individualized frequency map fitting*. *Eur Arch Otorhinolaryngol* 2011;268:27-39.
- ³⁴ Pelliccia P, Venail F, Bonafé A, et al. *Cochlea size variability and implications in clinical practice*. *Acta Otorhinolaryngol Ital* 2014;34:42-9.
- ³⁵ Mancini P, Bosco E, D'agosta L, et al. *Implementation of perceptual channels in children implanted with a HiRes 90K device*. *Acta Otolaryngol* 2009;129:1442-50.
- ³⁶ Di Nardo W, Cantore I, Cianfrone F. *Differences between electrode-assigned frequencies and cochlear implant recipient pitch perception*. *Acta Otolaryngol* 2007;127:370-7.
- ³⁷ Bruce J, Gantz MD, Christopher Turner, et al. *Preservation of hearing in cochlear implant surgery: advantages of combined electrical and acoustical speech processing*. *Laryngoscope* 2005;115:796-802.
- ³⁸ Durham D, Park DL, Girod DA. *Central nervous system plasticity during hair cell loss and regeneration*. *Hear Res* 2000;147:145-59.
- ³⁹ Di Nardo W, Giannantonio S, Di Giuda D, et al. *Role of auditory brain function assessment by SPECT in cochlear implant side selection*. *Acta Otorhinolaryngol Ital* 2013;33:23-8.
- ⁴⁰ Guiraud J, Besle J, Arnold L, et al. *Evidence of a tonotopic organization of the auditory cortex in cochlear implant users*. *J Neurosci* 2007;27:7838-46.
- ⁴¹ Pantev C, Oostenveld R, Engelien A, et al. *Increased auditory cortical representation in musicians*. *Nature* 1998;392:811-4.

Received: November 24, 2014 - Accepted: March 8, 2015

Address for correspondence: Roberta Anzivino, Catholic University School of Medicine and Surgery, Department Head and Neck surgery, Institute of Otorhinolaryngology, "A. Gemelli" Hospital, largo A. Gemelli 8, 00168 Rome, Italy. Tel. +39 06 30154439. Fax +39 06 3051194. E-mail: roberta.anzivino@gmail.com

OTOLOGY

Individualised headband simulation test for predicting outcome after percutaneous bone conductive implantation

Il test di simulazione individualizzato con headband per la predizione dei risultati dopo impianto uditivo percutaneo

S. MONINI¹, C. FILIPPI¹, F. ATTURO¹, M. BIAGINI¹, A.I. LAZZARINO², M. BARBARA¹

¹ NESMOS Department, Otolaryngology Clinic, Medicine and Psychology, Sapienza Università di Roma, Italy;

² University College London, Department of Epidemiology and Public Health, London, United Kingdom

SUMMARY

Trans-cutaneous bone conduction (BC) stimulators, when coupled to the HB (BC-HB), are generally used to predict the results that could be achieved after bone conductive implant (BCI) surgery, and their performance is generally considered inferior to that provided by the definitive percutaneous system. The aim of the present study was to compare the performances between BC-HB and BCI of the same typology, when the former's sound processor is fitted in accordance to the individual auditory situation. Twenty-two patients selected for surgical application of a BCI were evaluated and the same audiological protocol was used to select the candidate and assess the final outcome. The BC-HB was properly fitted based on individual hearing loss and personal auditory targets, and tested as primary step of the protocol to obtain the most reliable predictive value. The BAHA Divino and BP100 sound processors were applied in 12 patients with conductive/mixed hearing loss (CMHL) and in 10 subjects with single sided deafness (SSD). Audiometric evaluation included the pure tone average (PTA₃) threshold between 250-1000 Hz; the PTA thresholds at 2000 and 4000 Hz; intelligibility scores as percentage of word recognition (WRS) in quiet and in noise; and subjective evaluation of perceived sound quality by a visual analogue scale (VAS). Statistical evaluation with a student's t test was used for assessment of efficacy of BC-HB and BCI compared with the unaided condition. Spearman's Rho coefficient was used to confirm the reliability of the BC-HB simulation test as a predictor of definitive outcome. The results showed that the mean PTA difference between BCI and BC-HB ranged from 2.54 to 8.27 decibels in the CMHL group and from 1.27 to 3.9 decibels in the SSD group. Compared with the BC-HB, BCI showed a better WRS both in CMHL (16% in quiet and 12% in noise) and in SSD (5% in quiet and a 1% in noise) groups. Spearman's Rho coefficient, calculated for PTA, WRS in quiet and in noise and VAS in the two aided conditions, showed a significant correlation between BC-HB and BCI, between PTA and VAS and between WRS in quiet and VAS. It is possible to conclude that the headband test, when the sound processor of the selected bone conductive implant is fitted and personalised for individual hearing loss and auditory targets of the candidate, may provide highly predictive data of the definitive outcome after BCI implant surgery.

KEY WORDS: Bone conductive implant • Headband test • Hearing loss • Pure tone audiometry • Speech audiometry • VAS

RIASSUNTO

Gli stimolatori transcutanei per via ossea, quando accoppiati ad un archetto o headband (HB), vengono utilizzati per predire i risultati che potranno essere ottenuti dopo l'applicazione chirurgica di impianti uditivi a conduzione ossea (BCI). Generalmente, la loro efficacia viene considerata inferiore a quella fornita dal sistema percutaneo definitivo. In questo studio si è voluta comparare l'efficacia del sistema transcutaneo accoppiato all'HB (BC-HB) ed adattato alla situazione audiologica individuale, con i dati post-operatori ottenuti utilizzando lo stesso processore percutaneo. Ventidue pazienti, selezionati per l'applicazione chirurgica di un BCI, sono stati inclusi in questo studio e sono stati sottoposti ad uno stesso protocollo audiologico, sia per la loro candidatura che per la valutazione post-operatoria. Il BC-HB è stato accuratamente adattato all'ipoacusia ed agli obiettivi uditivi propri per ciascun soggetto, per poter acquisire il massimo valore predittivo. Sono stati utilizzati i processori BAHA Divino and BP100 in 12 pazienti con ipoacusia trasmissiva/mista, ed in 10 pazienti con sordità profonda monolaterale (single sided deafness o SSD). La valutazione audiologica ha incluso la soglia audiometrica tonale media tra 250 e 1000 Hz (PTA₃); quella a 2000 e 4000 Hz; la percentuale di intelligibilità per le parole (WRS) in quiete e nel rumore; e la valutazione soggettiva di qualità del suono percepito usando la scala analogica visiva (VAS). Il coefficiente Spearman Rho è stato utilizzato per valutare l'attendibilità del BC-HB come indicatore del risultato definitivo. I risultati hanno dimostrato che la differenza media tonale tra sistema percutaneo e simulatore varia dai 2,54 e gli 8,27 decibel nel gruppo con ipoacusia trasmissiva/mista, e dall'1,27 ed i 3,9 decibel nel gruppo SSD. Rispetto al simulatore, con il sistema impiantato si è osservato una migliore WRS: del 16% in quiete e del 12% nel rumore nei soggetti con ipoacusia trasmissiva/mista; e del 5% in quiete e dell'1% nel rumore nel gruppo con SSD. Si è in questo modo evidenziata una significativa correlazione tra i dati del simulatore e quelli dell'impianto percutaneo definitivo, tra il PTA ed il VAS, così come tra il WRS in quiete ed il VAS. Si può quindi concludere che il test con simulatore, quando il processore sonoro utilizzato viene adattato e personalizzato alle necessità uditive di ciascun soggetto, può fornire dati altamente predittivi del risultato definitivo di un BCI.

PAROLE CHIAVE: Impianto uditivo per via ossea • Test con archetto • Ipoacusia • Audiometria tonale • Audiometria vocale • VAS

Introduction

Bone conduction (BC) hearing provides a different pathway for sound transmission and represents an alternative to physiologic airborne conduction^{1,2}. Although the actual mechanisms that produce the hearing sensation when sound is transmitted through bone have not been fully elucidated, bone conduction hearing devices, such as conventional hearing aids (HA) or bone-conductive implants (BCI), have allowed to overcome some limitations that an air conduction HA carries in relation to, for example, post-operative sequelae from middle ear surgery or external ear canal chronic diseases^{3,4}. In fact, in the last decades, BCI have been successfully applied not only to patients with conductive or mixed hearing loss of different aetiology, but also to those affected by single-sided sensorineural deafness (SSD) by reproducing a contralateral routing of offside signal (CROS) amplification⁵. For nearly three decades, percutaneous BCIs have been adopted worldwide, allowing the osseointegrated device to directly drive bone stimulation to the cochlea, bypassing the damping effect of the skin and subcutaneous tissue. In case of small children, in whom reduced skull thickness is unlikely to retain the implanted screw, the BC sound processor is usually stabilised with a band, called soft-band, that provides transcutaneous stimulation. Likewise, a transcutaneous BC variant, coupled to the HB, is routinely used during the selection process of potential candidates, since it allows not only to perform the audiological evaluation, but also permits patients to familiarise themselves and subjectively perceive its possible benefit.

It is general opinion that the functional outcome of a transcutaneous bone-conductive system is different from what can be achieved by an osseointegrated implant. The variables in play for the reduced performance of the transcutaneous stimulation are position of the bone vibrator, surface contact area, skin thickness and frequency stimulation. In particular, when considering the frequency range of transmission of osseointegrated and transcutaneous BC devices, an overlapping sensitivity has to be expected below 500 Hz since, up to this frequency, the interposed skin produces no attenuation⁶. Beyond 500 Hz, contrarily, progressive separation of the percutaneous and transcutaneous BC thresholds occurs, the former being superior by approximately 4 to 7 dB when the speech reception threshold values are considered⁶.

The present study was performed to assess the clinical validity of carrying out the preoperative simulation test with HB, when the coupled sound processor has been customised to the patient's hearing loss and auditory targets, as a reliable predictor of the final outcome of BCI.

Materials and methods

Twenty-two adult subjects (10 males, 12 females), implanted at a University Hospital Implanting Center with a single BCI system (BAHA®, Cochlear, Mölnlycke, Sweden) were included in this retrospective study (Table I). Thirteen subjects presented with conductive-mixed hearing loss (CMHL), with mean bone-conduction threshold of 36.5 dB, mean air-conduction threshold of 73.1 dB and mean air-bone gap of 36.6 dB; 9 subjects were affected by single sided deafness (SSD), with a contralateral mild, down-sloping sensorineural hearing loss presumably caused by aging (Table II). A BP100 sound processor (SP) was used in 10 patients and a Divino SP in the remaining 12.

A preoperative simulation test was performed with an individualised fitting of the two different SPs according to type and degree of hearing loss. In the Divino SP, volume level and gain at the low frequencies were manually changed for CMHL patients while, in the SSD ones, the gain at low frequencies was down-regulated in favour of high frequencies. The microphone was always set in the omnidirectional configuration. The BP100 SP was fully programmed using dedicated preset parameters for CMHL and SSD, optimising the fitting software in each patient. In mixed hearing loss, the wide band dynamic range compression was activated. Automatic noise management, active feedback cancellation, acoustic shock protection and the dynamic output stabiliser were also activated in all patients. Even with this SP, the microphone was set in the omnidirectional configuration.

Audiological assessment included:

- Pure tone and speech audiometry, performed inside a soundproof booth with headphones, for choosing the ear (or the first ear) to be implanted;
- Sound-field PTA, word recognition score (WRS) in quiet (at 65 dB HL), and WRS in noise (S/N ratio +10 dB) as maximum percentage of intelligibility at the stimulation level of 80 dB, as maximum output of the loudspeaker, for collecting data. For the speech in noise tests, babble noise and speech were delivered through separate channels calibrated independently, with a S/N ratio +10, to the loudspeakers located in the CMHL group at 0° (speech) and 180° (noise), while in the SSD group the multi-talker babble was directed to the better hearing ear, and speech to the poorer one. In the CMHL group, the better ear was always occluded during tests. The speech material consisted in three lists specific to the patients' mother tongue⁷.

Single values were recorded for the unaided, BC-HB and post-operative BCI outcomes.

All patients also underwent subjective evaluation of sound quality under the three different situations, using a visual analogue scale (VAS), with scores ranging from 0 to 10. Mean values obtained in the CMHL and SSD groups with the BC-HB and the BCI compared with the unaided situation were used to assess the gain of the two aided

situations compared with the unaided one. For statistical analysis, a non-parametric distribution of data was used. Spearman's Rho correlation coefficient (> 0.80 with p value < 0.05) was used to evaluate the correlation and significance of BC-HB values in predicting BCI performance, in the CMHL and SSD groups separately and together, for the following variables:

- the PTA, separately, for low (250-1000 Hz) and high (2000-4000 Hz) frequencies, since at high frequencies different thresholds levels were recorded in the two aided situations^{6,13};
- the percentage of WRS in quiet;
- the maximum WRS in noise;
- VAS as sound quality.

Spearman's rho (ρ) coefficient was also used to assess the correlation of the VAS with both the 2-4 kHz PTA and the WRS in quiet, at baseline, BC-HB and BCI conditions.

The study was performed in accordance with the principles of the 1983 Declaration of Helsinki.

Results

Conductive-mixed hearing loss (CMHL)

PTA

The mean PTA values in the unaided, BC-HB and BCI conditions are shown in Figure 1. Improvement was found with the BC-HB and the BCI compared with the unaided situation. The mean gain at low-mid frequencies (250-1000 Hz) was 19.47 dB with the BC-HB and 22.01 dB with the BCI; at high frequencies (2000-4000 Hz) it was 14.42 dB with the BC-HB and 22.07 with the BCI. The BCI gain exceeded that with the BC-HB by 2.54 dB at low frequencies and by 8.27 dB at high frequencies.

Speech audiometry in quiet – WRS

The mean WRS values at 65 dB in quiet are shown in Figure 2. The WRS values improved with both the BC-HB and BCI. When considering the BC-HB and the BCI compared with the unaided condition, the mean WRS gain was 21% with the BC-HB, and 37% with the BCI, with a 16% difference (Fig. 2).

Speech audiometry in noise (S/R + 10) – Maximum WRS

The mean maximum percentage of word recognition in noise in the three different conditions is shown in Figure 3. The percentage of intelligibility improved with both the BC-HB and BCI. The mean gain compared with the unaided condition was 12.3% with the BC-HB and 24.5% with BCI, with a difference of 12.2% between the two aided conditions (Fig. 3).

Single sided deafness

PTA

The PTA results in all three situations are shown in Figure 1. PTA improvement was found with both the BC-HB and BCI at low and high frequencies. The mean gain at

Table I. Demographics and clinical characteristics of subjects included in the study. M: male; F: female; COM: chronic otitis media; SSD: single sided deafness.

Patient	Age	Gender	Aetiology	Type of hearing loss
A.M.	53	F	Bilateral COM	Mixed bilateral
G.B.	52	M	Right COM	Mixed right
R.B.	40	F	Bilateral COM	Mixed bilateral
M.C.	35	M	Franceschetti S.	Mixed bilateral
B.C.	35	F	Bilateral COM	Mixed bilateral
V.E.	45	F	Right COM	Mixed right
A.F.	56	F	Bilateral COM	Mixed bilateral
C.M.	56	F	Bilateral COM	Mixed bilateral
A.T.	63	F	Bilateral COM	Mixed bilateral
A.R.2	63	F	Bilateral COM	Mixed bilateral
A.R.1	51	M	Goldenhar S.	Mixed bilateral
V.S.	51	M	Bilateral COM	Mixed bilateral
L.T.	55	F	Bilateral COM	Mixed bilateral
C.T.	57	F	Sudden hearing loss	SSD
S.A.	60	M	Sudden hearing loss	SSD
S.A.	64	F	Ear surgery	SSD
R.F.	51	M	Ear surgery	SSD
E.M.	66	F	Ear surgery	SSD
DBL	57	M	Ear surgery	SSD
D.C.	74	F	Sudden hearing loss	SSD
G.F.	67	M	Ear surgery	SSD
O.A.	60	F	Sudden hearing loss	SSD

low frequencies was 3.17 dB with the BC-HB and 4.44 dB with the BCI; at high frequencies, the gain was 4.44 dB with the BC-HB and 8.33 dB with the BCI. The gain difference between the two aided modalities was 1.27 dB at low frequencies and 3.9 dB at high frequencies.

Speech audiometry in quiet – WRS

The mean WRS results in all three conditions are shown in Figure 2. The percentage of word recognition at 65 dB improved with both the BC-HB and BCI. The WRS gain was 9% with the BC-HB and 14% with the BCI; the difference between the two aided modalities was 5%.

Speech audiometry in noise (S/N + 10)

The mean maximum percentage of word recognition in noise in the three different conditions is shown in Figure 3. The mean gain was 1.11% with the BC-HB and 11.11% with the BCI compared with the unaided condition. A 10% percentage difference between the two aided modalities was found. The mean gain was 2 dB with the BC-HB and 5.5 dB with BCI.

VAS of sound quality

The mean VAS values obtained under the unaided, BC-HB and BCI conditions, in the CMHL and SSD groups, are shown in Figure 4.

In the CMHL group, a strict correlation ($\rho = 0.85$, $p < 0.001$) between the PTA thresholds at 250-1000 Hz of the BC-HB and BCI was found, which was also significant for all other parameters (Table III). In the SSD group, the correlation between BC-HB and BCI was also very close and significant

Table II. Pre-operative audiometric data of subjects with mixed hearing loss, as bone-conduction and air-conduction threshold levels. PTA: pure tone audiometry.

Patient	Bone conduction thresholds					Air conduction thresholds				
	250	500	1000	2000	4000	250	500	1000	2000	4000
A.M.	5	15	15	50	35	70	60	50	60	55
G.B.	35	50	55	60	60	105	95	85	90	115
R.B.	10	20	35	30	25	55	60	55	65	60
M.C.	5	25	35	45	40	65	60	65	65	75
B.C.	5	15	20	35	30	45	45	50	60	35
V.E.	40	45	45	65	75	105	100	110	105	110
A.F.	5	20	35	45	40	45	55	65	65	80
C.M.	20	35	40	60	70	85	90	70	90	100
A.T.	20	25	20	25	35	65	70	60	50	110
A.R.2	15	35	40	55	45	80	70	75	65	75
A.R.1	10	25	40	55	50	60	85	90	100	100
V.S.	15	40	55	65	75	55	60	80	65	95
L.T.	50	40	35	55	50	50	60	55	70	90

for all parameters, except for PTA values at 250-1000 Hz. When considering the patients together, strong correlation was found for the entire PTA range, which was significant for all parameters considered (Table IV).

In the CMHL, a high and significant correlation was found between the WRS in quiet and VAS in the unaided ($\rho = 1.00$; $p < 0.001$), BC-HB ($\rho = 0.99$; $p < 0.001$) and BCI ($\rho = 0.99$; $p < 0.001$) conditions. A significant correlation was also found between PTA 2-4 kHz and the VAS in the unaided ($p = 0.010$), BC-HB ($p = 0.004$) and BCI ($p < 0.001$) conditions.

In SSD, a high and significant correlation was found between the WRS in quiet and the VAS in the unaided ($\rho = 1.00$; $p < 0.001$), BC-HB ($\rho = 1.00$; $p < 0.001$) and BCI ($\rho = 0.87$; $p < 0.003$) conditions. No correlation was found between the VAS and PTA 2-4 kHz in the unaided ($p > 0.05$), BC-HB ($p = 0.05$) or BCI ($p > 0.05$) conditions.

Discussion

The differences between the transcutaneous and percutaneous modality of sound conduction of bone generally influence the mean auditory gain, even when a single frequency range is taken into consideration. At high frequencies, for instance, percutaneous BCI usually provides better gain than a transcutaneous system⁸. In clinical practice, a pre-operative trial period and audiometric tests carried out with the transcutaneous simulation system, such as the headband (HB), allow the patient to get acquainted with the sound delivered by the device, and also help the audiologist and surgeon to select the right candidate and anticipate the definitive post-operative result. Pre-operative HB tests enable recording data with a transcutaneous mode of stimulation, and to compare them at a later stage with those obtained via the definitive BCI. Similarly to all HA-related tests, even in this situation audiometric tests are performed in sound fields with variables related to intrinsic (type and severity

of hearing loss, uni- or bilateral hearing loss) and extrinsic factors (type and level of stimulation, loudspeaker position in the azimuth). Generally, in spite of striking methodological differences, few information is usually available in the literature that describes the specific setting of the simulation device, which is instead analysed with fixed stimulation parameters, such as delivering the maximum volume without balancing the frequency gain in relation to the patients' hearing loss and listening need. One may assume that this latter adjustment is meant to compensate for the inferior efficacy of the transcutaneous bone stimulator compared with the percutaneous one. Furthermore, the information collected by simulation tests should be different in individuals affected by CMHL from those with SSD due to the different problems associated with the two hearing conditions, such as for instance loss of binaural hearing that is usually targeted only in SSD. The literature in this regard has mainly focused on CMHL, because after more than 30 years of application of a BCI in this form of hearing impairment, the major target has uniquely been PTA gain⁹⁻¹¹. A recent study compared the pre-operative transcutaneous and postoperative percutaneous conditions, reporting differences in the hearing threshold (5-20 dB for the range 1-4 kHz and 6 dB for that 0.5-1 kHz) as well as in speech recognition thresholds (SRT improvement of 4-7 dB)¹². Other investigators have found that the predictive value at low-frequency was more reliable than at high frequencies, with a hearing gain ranging from 1 to 18 dB¹³. Snapp et al.¹⁴ commented on the low sensitivity of common audiological tests for predicting and monitoring BCI outcomes in SSD patients, stressing that the tests with speech recognition in noise should play a major role for appropriate assessment.

At our department, all patients candidate for a BCI, being affected by either conductive, mixed or profound unilateral sensorineural hearing loss (SSD), routinely undergo a pre-operative trial wearing a HB coupled to the same sound processor that has been chosen to be coupled to the implanted

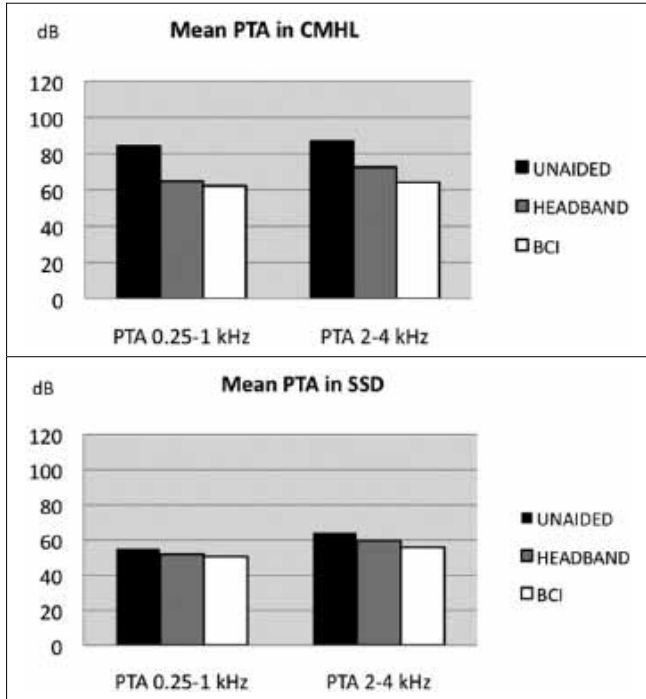


Fig. 1. a) Pure tone average (PTA) in conductive-mixed hearing loss (CMHL) subjects in the unaided, headband and bone-conductive implant (BCI) conditions. b) Pure tone average (PTA) in single-sided deafness (SSD) subjects in the unaided, headband and bone-conductive implant (BCI) conditions.

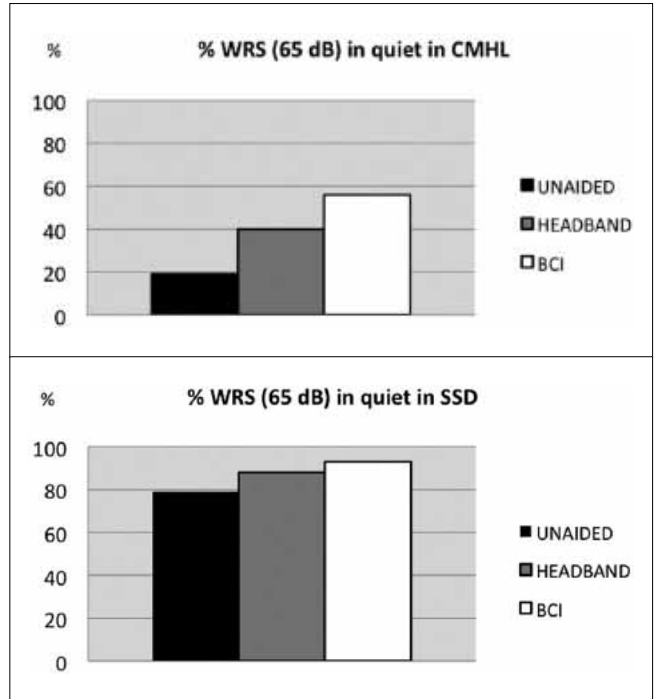


Fig. 2. a) Percentage of word recognition score (WRS) at 65 dB HL in quiet, in conductive-mixed hearing loss (CMHL) subjects, in the unaided, headband and bone-conductive implant (BCI) conditions. b) Percentage of WRS at 65 dB HL in quiet, in single-sided deafness (SSD) subjects, in the unaided, headband and BCI conditions.

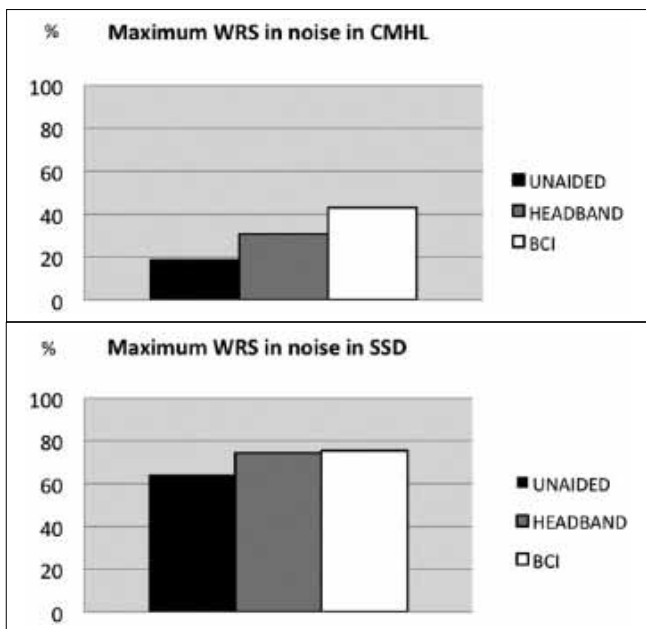


Fig. 3. a) Maximum percentage of word recognition score (WRS) in noise, at stimulation level of maximum WRS in quiet, in conductive-mixed hearing loss (CMHL) subjects, in the unaided, headband and bone-conductive implant (BCI) conditions. b) Maximum percentage of WRS in noise, at stimulation level of maximum WRS in quiet, in single-sided deafness (SSD) subjects, in the unaided, headband and BCI conditions.

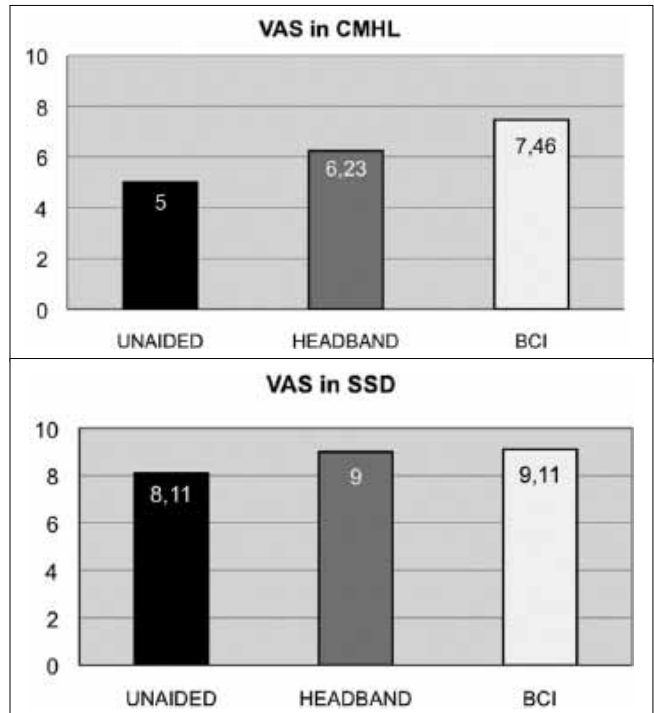


Fig. 4. a) Mean visual analogue scale (VAS) score for conductive-mixed hearing loss (CMHL) subjects in the unaided, headband and bone-conductive implant (BCI) conditions. b) Mean VAS score for single-sided deafness (SSD) subjects in the unaided, headband and BCI conditions.

Table III. Correlation level (Spearman's rho) and significance (p) of the intra-individual changes in variables between the BC-HB and the BCI, for conductive-mixed hearing loss (CMHL, n = 13) and single-sided deafness (SSD, n = 9) subjects. PTA: Pure tone average; WRS: word recognition score.

Predictive Index of pre-operative BC-HB for the BCI outcome		
Variable	Spearman's Rho	p value
CMHL (n = 13)		
Sound quality (VAS)	0.68	0.011
PTA 250-500-1000 Hertz (dB)	0.85	< 0.001
PTA 2-4 KHz (dB)	0.68	0.011
WRS in quiet	0.69	0.010
WRS in noise (%)	0.73	0.005
SSD (n = 9)		
Sound quality (VAS)	0.90	0.001
PTA 250-500-1000 Hertz (dB)	0.56	0.119
PTA 2-4 KHz (dB)	0.88	0.002
WRS in quiet	0.92	0.001
WRS in noise (%)	0.87	0.002

fixture. The specific sound processor is individually fitted, selecting the parameters that would mostly be beneficial for the individual patient. In the present study, two types of sound processors of the same manufacturer were used: the BP100 and the Divino. For the BP100 SP, the fitting parameters set by default for conductive-mixed hearing loss and SSD were modified on the basis of the patient's listening characteristics; for the Divino SP, the volume at the low frequencies was manually regulated depending on the type of hearing loss: in SSD, the gain at low frequencies was decreased to allow better speech perception, especially in noisy environments, while in CMHL, low frequency amplification was only finalised to improve the signal to noise ratio. Due to the limitation of the available devices, which do not allow a home-trial period, the potential candidate was left with the BC-HB for a few hours in different listening environments, before performing a series of audiological tests that have always included the measurement of verbal perception, in quiet and noise, as well as a questionnaire on the quality of the perceived sound in the different listening situations.

The present study has taken into consideration hearing function assessed both with the BC-HB and with the activated BCI, in terms of:

- hearing threshold as PTA (250-4000 Hertz);
- percentage of WRS at 65 dB in quiet;
- maximum percentage of WRS in noise (S/N +10, fixing the stimulation loudness at 80 dB, corresponding to the maximum output of the loudspeaker in sound-field);
- quality of perceived sound with VAS compared with the unaided condition, and the statistical difference of the same parameters between the simulation pre-operative effects and definitive post-operative outcome.

The effect of the BCI, in the simulation and definitive configurations, was significantly better than in the unaided condition for all the qualitative and quantitative param-

Table IV. Correlation level (Spearman's rho) and significance (p) of the intra-individual changes in variables between the BC-HB and the BCI, in the entire study group. PTA: pure tone average; WRS: word recognition score.

Correlation between the intra-individual changes after the BC-HB and the BCI in all subjects		
Variable	Spearman's Rho	p value
PTA 250-500-1000 hertz (dB)	0.85	< 0.001
PTA 2000-4000 hertz (dB)	0.83	> 0.001
WRS in quiet (%)	0.61	0.003
WRS in noise (%)	0.76	< 0.001

eters. Apart from this easily predictable result, the major target of this study was to assess how close the two aided conditions would perform, so as to highlight the predictive role of the BC-HB.

In conductive and mixed hearing loss, a mean intra-individual improvement after BCI was found for the PTA between 250 and 4000 Hz, for word discrimination in quiet and noise, and for the quality of sound. The PTA differences between the BCI and the BC-HB were minimal (around 2.5 dB for low frequencies and 8 dB for high frequencies), while the speech performance with the BCI was better than with the BC-HB (16% in quiet and 12% in noise).

In the SSD group, the performance of the BCI was superior to that of the BC-HB in all parameters considered. The mean PTA gain with the BCI, compared with the BC-HB condition, was minimal (around 1 dB) for low frequencies and up to only 4 dB for high frequencies. When testing speech discrimination, a better percentage of intelligibility was found with the BCI than with the BC-HB, of about 5% in quiet and 10% in noise. The mean VAS values in the CMHL and SSD groups, taken together, showed that the definitive BCI provided a clearer and better sound than both the unaided and the BC-HB condition.

The prediction of the BCI effect derived from the correlation between the intra-individual changes of the variables in the two aided situations was extremely significant in the CMHL group for low-middle frequencies, and to a lesser degree, but still significant, for the other parameters; in the SSD group, however, the correlation for low frequencies was poor. This latter finding is related to the fitting characteristics for the SSD situation and to the minimal gain deliberately received at low frequencies to privilege high frequency gain, while trying to optimise some of the binaural function features. Considering the patients together (CMHL + SSD), close correlation was found for the entire PTA range, which was significant for all parameters.

The correlation between VAS and the other variables revealed differences between the CMHL and SSD groups in the three different situations. In CMHL, in all situations, a close and significant correlation was found between the good perceived quality of sound in terms of clearness and openness and speech perception in quiet. When considering the correlation between VAS and 2000-4000 Hz PTA,

it was shown to be significant in all auditory situations, but correlated highly only with the BCI. The correlation between sound quality, sound-field speech perception and high-frequency gain with a BCI has already been recently shown¹³. In the SSD group, in contrast, a high and significant correlation of VAS was shown only with the WRS percentage in quiet, in all three situations. This finding means that in the SSD, verbal and speech perception are related with directional hearing and follow two separate analytic processing cues, the first simply auditory and the second linked to multi-sensorial inputs.

Apart from the efficacy of the BCI compared to the unaided situation in the CMHL and SSD groups, the present study showed that the use of a personalised, well-fitted SP coupled to a HB in pre-operative simulation tests is reliable in predicting the final BCI advantages not only for hearing improvement, but also for speech perception in noise and quality of listening. The accuracy of the outcome prediction is motivated by the fact that, contrary to previous reports, the differences between PTA and WRS in the two aided conditions were minimal¹⁴. This assumption is also confirmed by the strong and significant correlation with all variables taken into consideration, as well as in the VAS when comparing hearing function with the BC-HB with that of the definitive implant.

It is possible to comment that the main reason for pre-operatively assessing a BCI candidate with a transcutaneous HB-coupled processor is to allow the subject to experience the actual advantages of bone conduction stimulation carried out using a modality that is mostly reproduced by the definitive BCI. In our opinion, these simulation tests can be reliable only if the drawback of the skin attenuation related to the transcutaneous condition is partially compensated by fitting the SP simulator on the basis of individual hearing loss, as well as the needs and individual targets of each candidate, rather than using a preset configuration.

Conclusions

The present study shows that when using pre-operative audiological assessment with a BC-HB simulator as a predictor of a BCI outcome, the simulation device should be fitted with the same modality used for the definitive BCI, while assessing audiological performances not only as PTA auditory gain, but mostly as speech perception in noise and improvement of the quality of perceived sound.

The outcome of such an evaluation may allow patients, audiologists and surgeons to obtain an accurate estimate of the final outcome after BCI application.

References

- 1 Tonndorf J. *Bone conduction. Studies in experimental animals*. Acta Otolaryngol 1966;(Suppl 213):1.
- 2 Stenfelt S, Goode RL. *Bone conducted sound: Physiological and clinical aspects*. Otol Neurotol 2005;26:1245-61.
- 3 Håkansson B, Tjellström A, Rosenhall U, et al. *The bone-anchored hearing aid*. Acta Otolaryngol 1985;100:229-39.
- 4 Albrektsson T, Brånemark PI, Jacobsson M, et al. *Present clinical applications of osteointegrated percutaneous implants*. Plast Reconstr Surg 1987;79:721-31.
- 5 Vanecloo FM, Ruzza I, Hanson JN, et al. *The monoaural psuedo-stereophonic hearing aid (BAHA) in unilateral total deafness: a study of 29 patients*. Rev Laryngol Otol Rhinol (Bord) 2001;122:343-50.
- 6 Håkansson B, Tjellström A, Carlsson P. *Percutaneous vs. transcutaneous transducers for hearing by direct bone conduction*. Otolaryngol Head Neck Surg 1990;102:339-44.
- 7 Turrini M, Cutugno F, Maturi P, et al. *Nuove parole bisillabiche per audiometria vocale in lingua italiana*. Acta Otorhinolaryngol Ital 1993;13:63-77.
- 8 Stenfelt S, Håkansson B, Tjellström A. *Vibration characteristics of bone conduction sound in vitro*. J Acoustic Soc Am 2000;107:422-31.
- 9 Mylanus EA, Snik AF, Cremers CW. *Influence of the thickness of the skin and subcutaneous tissue covering the mastoid on bone-conduction thresholds obtained transcutaneously vs. percutaneously*. Scand Audiol 1994;23:201-3.
- 10 Håkansson B, Tjellström A, Rosenhall U. *Hearing thresholds with direct bone conduction vs. conventional bone conduction*. Scand Audiol 1984;13:3-13.
- 11 Hodgetts WE, Scollie SD, Swain R. *Effects of applied contact force and volume control setting on output force levels of the Baha softband*. Int J Audiol 2006;45:301-8.
- 12 Verstraeten N, Zarowski AJ, Somers T, et al. *Comparison of the audiological results obtained with the bone-anchored hearing aid attached to the headband, the testband, and to the "snap" abutment*. Otol Neurotol 2008;30:70-5.
- 13 Heywood RL, Patel PM, Jonathan DA. *Comparison of hearing thresholds obtained with BAHA preoperative assessment tools and those obtained with the osseointegrated implant*. Ear Nose Throat J 2011;90:21-7.
- 14 McNeil ML, Gulliver M, Morris DP, et al. *Can audiometric results predict qualitative hearing improvements in bone-anchored hearing aid recipients?* J Laryngol Otol 2014;128:35-42.

Received: September 21, 2014 - Accepted: February 3, 2015

Address for correspondence: Maurizio Barbara, Head ENT Clinic, Medicine and Psychology, University Hospital Sant' Andrea, via di Grottarossa 1035, 00189 Rome, Italy. Tel. +39 06 33775628. Fax +39 06 33775058. E-mail: maurizio.barbara@uniroma1.it

PEDIATRIC OTORHINOLARYNGOLOGY

Foreign body injuries in children: a review

Lesioni da corpo estraneo nei bambini: una revisione

D. PASSALI¹, D. GREGORI², G. LORENZONI², S. COCCA¹, M. LOGLISCI¹, F.M. PASSALI³, L. BELLUSSI¹,¹ ENT Clinic University of Siena, Italy; ² Unit of Biostatistics, Epidemiology and Public Health, Department of Cardiac, Thoracic and Vascular Sciences, University of Padova, Italy; ³ ENT Clinic Università di Roma Tor Vergata, Rome, Italy

SUMMARY

The aim of this paper was to overview existing knowledge on foreign body (FB) injuries in children, with particular focus on FB types and anatomical locations, clinical presentation and complications. FB injuries represent a severe public health problem in childhood. The fact that the highest prevalence of FB injuries is reported for children between 0 and 3 years of age depends primarily on the fact that they explore objects using their mouth and are also not able to distinguish edible objects from non-edible ones. Types of FB causing injuries depend on the symptoms related to FB ingestion/inhalation/insertion (providing an early diagnosis of FB injuries) and complications related to the FB characteristics (type, shape, dimensions). The analysis of the Susy Safe database showed that in 10,564 cases, in which the object type was available, 74% of objects were inorganic and were mostly represented by pearls and balls, followed by coins. The main concern about FB injuries is the fact that they may be asymptomatic or that symptoms may be non-specific. Consequently, the FB injury can be misinterpreted as a gastrointestinal or respiratory infection. The absence of specific symptoms indicating the occurrence of FB injury can lead to delays in diagnosis, thereby increasing the risk of complications. Symptoms seem to mostly depend on the anatomical location. Many ingested FBs pass naturally through the gastrointestinal tract without complications or damage. However, severe complications can occur depending on the characteristics of the FB, its anatomical location, the child's age and delays in diagnosis.

KEY WORDS: Foreign bodies • Suffocation • Children • Emergency care

RIASSUNTO

Nel presente lavoro gli Autori sintetizzano le testimonianze relative ai danni provocati da corpi estranei in bambini sottolineandone il tipo, la sede la clinica e le complicanze. I danni provocati da corpi estranei rappresentano un importante e frequente problema di salute pubblica specie nell'infanzia, in quanto i piccoli tra 0 e 3 anni di età hanno l'abitudine di esplorare oggetti sconosciuti portandoli in bocca senza riconoscere se gli stessi sono commestibili o no. L'analisi effettuata nell'ambito del progetto "Susy database" ha permesso di rilevare come nei 10.564 casi esaminati il 74% di oggetti erano inorganici (principalmente perle e palline di ogni genere, seguite da monete). Nella maggior parte dei casi i piccoli non presentavano particolare sintomatologia ovvero sintomi assolutamente non specifici tale da non evidenziarne la causa. L'assenza di specifici sintomi porta generalmente a dilazioni nella diagnosi, aumentando il rischio di complicanze. I sintomi dipendono in massima parte dall'ubicazione e dalla dimensione dell'oggetto inalato ovvero ingerito che può passare attraverso il tratto di gastrointestinale, senza danni. Comunque, è da sottolineare come le complicazioni più importanti sono relative alle caratteristiche del corpo estraneo alle quali bisogna rivolgere particolare attenzione per la scelta terapeutica.

PAROLE CHIAVE: Database Susy Safe • Corpi estranei • Emergenze in pediatria

Acta Otorhinolaryngol Ital 2015;35:265-271

Introduction

Foreign body (FB) injuries represent a severe public health problem in childhood, especially in infants. The fact that the highest prevalence of FB injuries is reported for children between 0 and 3 years of age depends primarily on the fact that young children explore objects using their mouth, are not able to distinguish edible objects from non-edible ones, their teeth are physiologically lacking (they have incisors to tear food, but not cuspids, with consequently difficulties in reducing food in a smooth bolus) and have poor swallowing coordination (compared to older children and adults). Additionally, FB injuries in

pre-schoolers can be related to distractions (e.g. eating and playing at the same time)¹.

FB injuries are related to increased morbidity (they often have a non-specific clinical presentation, resulting in a delay of recognition of FB injury that can lead to serious complications depending on the type of FB, its anatomical location and the child's characteristics²) as well as mortality (choking is one of the main causes of death in kids aged 0-3 years, but it is common also in older children, especially in those up to 14 years of age)³.

In order to improve clinical management of children in whom FB injuries occurred, reduce the risk of complications and death, and to develop strategies for prevention

of FB injury, it is crucial to understand the types of FB that cause injuries, the symptoms related to FB ingestion/inhalation/insertion (providing an early diagnosis of FB injuries) and complications related to the characteristics (type, shape, dimensions) of the FB. However, despite the severity of this type of injury (and the consequently need for evidence to improve clinical management and develop prevention strategies), the availability of high quality evidence on FB injuries is lacking⁴. This is probably related to a lack of systematic collection of data on FB injuries in children: only a few countries have developed a surveillance tool collecting information on FB injuries, and most of the available data come from publication of single case studies^{5,6}, collection of case studies from a single health care centre⁷ and review of previously published case studies⁸ (consequently, data are collected in a heterogeneous manner resulting in difficulties in pooled analysis). Currently, the main surveillance tool providing epidemiological data on FB injuries, is represented by the Susy Safe registry^{9,10}. It was developed to provide a risk profile of products causing injuries in children, investigate the impact of socio-economic disparities in injuries' likelihood and involve consumer associations to educate consumers on the risks of FB injury. It collects information in both European and non-European countries on characteristics, symptoms and complications of FB injury, and on the procedures performed for diagnosis and removal of the FB. This paper aims to overview existing knowledge on the types of FB injuries in children, clinical presentation and complications related to FB type, and to provide an update of the literature.

Foreign body types and anatomical location

Types of FBs ingested/inhaled/swallowed/inserted by the child are generally classified as food and non-food objects. Regarding anatomical location, it is usually reported (e.g. from the Susy Safe registry) using the International Classification of Disease ICD-9, corresponding to codes from 931 to 935 (which are represented, respectively, by FB in: ears, nose, pharynx and larynx, respiratory tract and digestive tract) in order to provide a standardisation of FB injuries. Generally, FB injuries involving the respiratory tract occur more often in young children (less than 4 years of age), while insertion of FBs in ears or nose is reported more frequently in older children¹¹. The results retrieved from the literature on FB characteristics and anatomical location are shown in Table I.

The analysis of 16,878 FB injuries from the Susy Safe database¹² showed that in 10,564 cases in which the object type was available, 74% of objects were inorganic and were mostly represented by pearls and balls, followed by coins. A review of FB injuries reported in the literature demonstrated that coins were the objects most often in-

gested by kids¹³. This finding is similar to those reported from a retrospective study conducted on 192 FB injuries cases, demonstrating that the most frequently found oesophageal objects were coins¹⁴. Moreover, data on Romanian children showed that, among children who swallowed a FB, the objects most frequently retrieved were coins¹⁵, which is consistent with the analysis of 320 oesophageal FB cases in Argentinean children¹⁶. Toys (particularly parts of broken toys and *Lego*[®] type toys) represent a particular category of inorganic objects: they are often found in the upper aero-digestive tract (especially since children insert them in the nose). However, in recent years, the incidence of this type of injury is decreasing thanks to stricter regulations for toy manufacturers and commercialisation^{17,18}.

Regarding organic objects, the analysis of the Susy Safe database showed that only 26% of cases (among those in which the object type was specified) were related to food items and were most frequently found in ears (ICD931), pharynx and larynx (ICD933), trachea, bronchus and lungs (ICD934)¹⁹. The fact that food is the object that is generally most frequently aspirated by children is confirmed also by a retrospective study of 184 cases of FB aspiration, showing that nuts and seeds (especially sunflower seeds and hazelnuts) were more frequently retrieved in the respiratory tract²⁰, which is consistent with data on FB injuries retrospectively revised in a German hospital, showing that organic objects (particularly seeds, nuts and berries) were those that were most often inhaled by children²¹. Additionally, a systematic review of articles reporting on FB injuries demonstrated that food items (especially nuts) were most frequently found in children's airways⁸. Nuts and seeds are found to be the objects most frequently inhaled by children, particularly those younger than 3 years of age²². The high incidence of nut and seed retrieval in young children's airways is mostly associated with difficulties in chewing this type of fruit due to a physiological lack of teeth. Nuts are more commonly retrieved in children living in Western countries, while watermelon seeds are more common in Asian ones²². Additionally, a study conducted among Turkish children highlighted the fact that inhalation of hazelnuts during the hazelnut harvest season represents a severe public health problem²³. These findings clearly indicate that the type of object causing injuries in children is highly dependent on the social, economic and cultural environment in which the child lives.

Symptoms of foreign body injuries

The main concern about FB injuries is the fact that they can be asymptomatic or that symptoms can be non-specific. As a consequence, FB injury can be misinterpreted with a gastrointestinal or respiratory infection. If the injury is not witnessed, the absence of specific symptoms

Table I. Foreign body (FB) types and anatomical location. For FB type, only the three objects most frequently retrieved are reported.

Source	Year	Study Type	Country	No. of cases/ No. of included studies	FB anatomical location	FB type
Šlapák et al. ¹²	2012	Prospective study (Susy Safe's data analysis)	Both EU and non-EU countries	10,564 cases for which the FB type was specified. Analyses were performed on the 7,820 (74%) injuries due to a non-food item	37% Nose 29% Mouth, Oesophagus, Stomach 24% Ear 6% Pharynx and Larynx 4% Trachea, Bronchi and Lungs	22% Pearl, Ball, Marble 20% Coin 8% Other non-food
Sebastian van As et al. ¹⁹	2012	Prospective study (Susy Safe's data analysis)	Both EU and non-EU countries	10,564 cases for which the FB type was specified. Analyses were performed on the 2744 (26%) injuries due to a food item	50% Trachea, Bronchi and Lungs 19% Nose 16% Pharynx and Larynx 8% Mouth, Oesophagus, Stomach 7% Ear	32% Bone 22% Nut 21% Other food
Chinski et al. ¹⁶	2010	Prospective study	Argentina	320 cases	Oesophagus	268 Coins 15 Bones 15 Plastic pieces
Rybojad et al. ¹⁴	2012	Retrospective study	Poland	192 cases were reviewed, a FB was retrieved in 163 cases	Oesophagus	54% Coins 19% Food fragments 7% Toy parts
Jayachandra et al. ¹³	2013	Systematic review		17 articles, corresponding to 5,559 cases	Digestive tract	2 studies analysed exclusively coins ingestion. Among the other 15 studies, 10 reported coins as the objects most frequently ingested
Sarfoleanu et al. ¹⁵	2012	Retrospective study	Romania	455 cases	44.62% Nose 24.18% Mouth, Oesophagus, Stomach 14.73% Trachea, Bronchi and Lungs 12.75% Ears 3.74% Pharynx and Larynx	23.96% Nuts and Seeds (50.46% were aspirated) 12.75% Marbles 12.53% Coins (96.49% were ingested)
Oncel et al. ²⁰	2012	Retrospective study	Turkey	184 cases	Airways	45% Sunflower seeds 26% Pistachio 11% Hazelnut
Göktas et al. ²¹	2010	Retrospective study	Germany	78 cases	Airways	69.2% Seeds, nuts, berries and grains 15.4% Other types of food
Brkic et al. ⁷	2007	Retrospective study	Bosnia and Herzegovina	662 cases	84% Bronchi 14.3% Trachea and Larynx	87.1% Organic objects
Foltran et al. ⁸	2012	Meta-analysis		174 articles, corresponding to 30,477 cases	Airways	6504 Nut 5553 Organic unspecified 3678 Seeds Toys
Foltran et al. ¹⁸	2012	Prospective study (Susy Safe's data analysis)	Both EU and non-EU countries	10,564 cases for which the FB type was specified. Analyses were performed on the 441 (2.6%) injuries due to toys	75% Nose 13% Mouth, Oesophagus, Stomach 9% Trachea, Bronchi and Lungs 4% Pharynx and Larynx	Toys
Foltran et al. ¹⁷	2011	EFSBI (European Survey on Foreign Bodies Injuries), retrospective study	19 European countries	2,094 cases. Analyses were performed on the 121 (5.8%) injuries due to toys	74% Nose 13% Trachea, Bronchi and Lungs 7% Mouth, Oesophagus, Stomach 6% Pharynx and Larynx	29 (31%) Toy 17 (18%) Part of a toy 16 (17%) <i>Lego</i> [®] type toys

Table II. Symptom of FB injury.

Source	Study type	No. of cases/ No. of included studies	Anatomical location
Jayachandra et al. ¹³	Systematic review	17 articles, corresponding to 5559 cases	Digestive tract
Rybojad et al. ¹⁴	Retrospective study	192 cases were reviewed, a FB was retrieved in 163 cases	First, Second and Third narrowing of oesophagus
Balci et al., 2004 ²⁴	Retrospective study	1116 cases	Oesophagus
Chinski et al., 2010 ¹⁶	Prospective study	320 cases	Oesophagus
Foltran et al., 2012 ⁸	Meta-analysis	174 articles, corresponding to 30,477 cases	Airways
Lea et al., 2005 ²⁵	Prospective study	98 cases with suspected FB, in 56 FB was found	Airways

indicating the occurrence of FB injury can lead to delays in diagnosis, thus increasing the risk of complications. Symptoms seem to depend mostly on anatomical location (Table II).

A review of published cases of FB ingestion¹³ showed that symptoms differ in each of the studies, but include mostly gastrointestinal symptoms (vomiting, dysphagia, drooling, gagging) when the FB is located in the upper-mid-lower oesophagus. In studies in which coins were found to be ingested by children, vomiting and drooling were the most frequently reported symptoms. However, some studies reported that injured children were completely asymptomatic. A study conducted in Polish children on FB ingestion, in which most of FB were found to be coins, that most common symptoms were dysphagia, vomiting and drooling¹⁴. Drooling and dysphagia were also most frequently reported in oesophageal FB in a retrospective study conducted on 1116 cases in a Turkish paediatric population²⁴. Gastrointestinal symptoms were frequently encountered among Argentinean children injured by FB located in the oesophagus, although vomiting and

odynophagia were those most frequently reported, while drooling and dysphagia were less prevalent¹⁶. Despite the fact that FB located in the mouth/oesophagus/stomach are more often related to gastrointestinal symptoms, it is difficult to identify a specific pattern of symptoms considering the FB type, location and child's characteristics, as is demonstrated by the fact that significant heterogeneity in clinical presentation was reported among studies.

Regarding FB in the airways, a meta-analysis of published studies showed that most frequent symptoms are cough and fever, followed by dyspnoea and choking, while the most common sign was abnormal breath sounds at auscultation⁸. Consistent with this meta-analysis, a 2-year prospective study on Israeli children showed that the symptoms most frequently associated to FB aspiration were choking, cough and dyspnoea²⁵. Given the high frequency of symptoms such as cough and fever associated with FB inhalation, the risk of misdiagnosing the FB injury with a respiratory tract infection is high. A retrospective study reviewing medical records of children with a suspect diagnosis of FB aspiration reported that all chil-

Symptoms				
Gastrointestinal	Respiratory	Pain	Others	Asymptomatic
7 studies: Vomiting 6 studies: Dysphagia 4 studies: Drooling 2 studies: Gagging 1 study: Fluid intolerance	2 studies: Choking	1 study: Odynophagia 1 study: Retrosternal pain 2 studies: Pain (not specified)		2 studies
First narrowing: 34 Drooling 34 Vomiting 33 Dysphagia Second narrowing: 12 Drooling 13 Vomiting 24 Dysphagia Third narrowing: 2 Drooling 3 Vomiting 8 Dysphagia		First narrowing: 6 pain cases Second narrowing: 9 pain cases Third narrowing: 12 cases		
512 (45.9%) Drooling 298 (26.7%) Dysphagia 12 (1.1%) Vomiting	89 (8%) Wheezing 45 (4%) Respiratory Infection 19 (1.7%) Hemoptysis 11 (1%) Choking/cyanosis 2 (0.2%) Pneumonia	97 (8.7%) Cervical pain 26 (2.3%) Chest pain	4 (0.3%) Fever 1 (0.08%) Anorexia	
92 (28.7%) Vomiting 38 (11.86%) Sialorrhoea 31 (9.69%) Ptyalism 28 (8.75%) Dysphagia		75 (23.4%) Odynophagia		47 (14.69%)
96 Vomiting	12,605 Cough 5947 Choking 4507 Dyspnoea 73 Voice hoarsens 59 Blood stained mucus	111 Throat pain 43 Thoracic pain	1970 Fever 15 Unconsciousness	109
	76.8% Choking 14.3% Cough 3.6% Dyspnoea 1.8% Pneumonia			

dren presented with cough and abnormal breath sounds, but about 20% of FB injury cases were misdiagnosed with tracheobronchial infections or disease (e.g. pneumonia or asthma). Among these, diagnosis was correctly achieved after 3 days and 2 years. Moreover, FB aspiration symptom patterns are unclear with a consequently high risk to misdiagnose the injury with a respiratory infection if the FB aspiration is not witnessed.

Complications of FB injuries

Many ingested FBs pass naturally through the gastrointestinal tract, without complications or damage. However, severe complications can occur that depend on the characteristics of the FB, its anatomical location, the child's age and delay in diagnosis.

FB characteristics play a key role in determining the risk of complications, particularly considering its consistence and shape: rigid and semi-rigid objects and those with sharp and edges are those most commonly found to cause complications such as laceration and perforations²⁶, while

small, round items (e.g. food items like berries) are found to increase choking risk²⁷. Referring, more specifically, to the categories of hazardous organic and inorganic objects, it has been demonstrated that, among food items, bones (especially fish and chicken bones) and broken nut shells can lead to determine mucosal perforation/laceration, although nuts (the food item most frequently retrieved in children's airways) are those most often related to complications, compared to bones and nut shells, because they can also cause an inflammatory reaction determining sudden tracheobronchial obstruction¹⁹. Among inorganic objects, in addition to those that have a rigid/semi-rigid consistence and sharp/edges, there are also two types of items that deserve particular attention because of the severe complications related to their ingestion/inhalation: magnets and batteries. Regarding magnets, if the ingestion of a single magnet is generally not dangerous because it passes naturally through the gastrointestinal tract, the ingestion of multiple magnets is dramatic as they can attract each other once in the gastrointestinal tract (especially in the bowel)²⁸. The most frequently described com-

plications associated with ingestion of multiple magnets are necrosis, bowel obstructions, perforations, sepsis and even death²⁹, which are mainly attributable to delays in diagnosis¹⁵. Additionally, the incidence of the ingestion of multiple magnets has increased in the last years³⁰, highlighting that, despite the fact that the risk related to magnet ingestion is well documented, preventive strategies are lacking. In addition, batteries represent a hazardous item if ingested/inhaled/aspirated: complications can occur not only to battery rupture and release of its toxic content, but, more often, due to the generation of an electronic current from the battery in contact with tissue fluids³¹. This reaction leads to the production of hydroxide, which is dangerous and can lead to severe complications including necrosis, perforation, fistula, haemorrhage and even death. Despite the fact that batteries may pass through the gastrointestinal tract without complications, as an inert FB, the ingestion of button batteries is particularly dangerous. More specifically, the ingestion of a button battery with a diameter of 20 mm by children younger than four years of age increases the risk that the button battery hangs in the oesophagus determining severe complications within two hours³¹⁻³³. There is thus a crucial need for prompt medical attention after button battery ingestion.

Not only for batteries and magnets, but more generally for all types of FB injuries, it has been widely demonstrated that the prevention of complications requires early diagnosis and prompt clinical reaction. A review of 136 cases of FB aspiration conducted in a Israeli hospital demonstrated that children who referred to the health care centre after 2 days (or more) from the injury had a 2-fold increased risk of complications². Another study, conducted on 263 children in whom a tracheobronchial FB was found, demonstrated that no complications occurred in patients who were referred to the hospital within 24 hours from the injury occurrence, while complications were reported for children who referred later to the health care centre. Clearly, in addition to the FB type and anatomical location, another key factor associated with a risk of complications is the time at which children are referred to the hospital: delays in referral or in diagnosis increase the risk of onset and/or worsening of complications.

Conclusions

The aim of this paper was to summarise the existing knowledge on FB injuries in children, with focus on the FB types and anatomical locations, clinical presentation and complications. Young children are more susceptible to FB injuries. Referring to FB characteristics and sites in which they are found, the data in the literature showed that the majority of FB are inorganic objects, while food items (especially nuts and seeds) are those most often retrieved in children's airways. The risk of complications is highly related to the type of FB: rigid and semi-rigid objects and

those with sharp and edges pose a risk of perforation and laceration, while small round items (food items like berries) increase the likelihood of choking. Early referral of injured children to the hospital is crucial to prevent complications; if the injury is not witnessed, misdiagnosis can occur, leading to delays in clinical intervention because symptoms may be non-specific. At present, we could not identify a specific pattern of symptoms related to FB injuries from the published literature.

Given the risk of misdiagnosis of FB injuries due to non-specific clinical presentation and the severity of complications to which a FB injury may be associated, it is essential crucial to develop primary prevention strategies for FB injuries. In particular, educational programs should be carried out for parents to stress the importance that children eat food and play with toys that are appropriate for their age (e.g. avoiding nuts and seeds and, more generally, small round food items, as berries, in kids younger than 4 years of age, guaranteeing adult supervision when young children are playing or eating). Primary prevention is also represented by the involvement of manufacturers and consumer associations, providing strict regulation on manufacturing, packaging, quality control and commercialisation of hazardous objects (particularly toys, magnets and batteries).

References

- Rodríguez H, Passali GC, Gregori D, et al. *Management of foreign bodies in the airway and oesophagus*. *Int J Pediatr Otorhinolaryngol* 2012;76(Suppl 1):S84-91.
- Shlizerman L, Mazzawi S, Rakover Y, et al. *Foreign body aspiration in children: the effects of delayed diagnosis*. *Am J Otolaryngol* 2010;31:320-4.
- Altkorn R, Chen X, Milkovich S, et al. *Fatal and non-fatal food injuries among children (aged 0-14 years)*. *Int J Pediatr Otorhinolaryngol* 2008;72:1041-6.
- Passali D, Kim C-S. *Foreign body injuries: the urgent need for updating the field*. *Int J Pediatr Otorhinolaryngol* 2012;76(Suppl):S2.
- Gohil R, Culshaw J, Jackson P, et al. *Accidental button battery ingestion presenting as croup*. *J Laryngol Otol* 2014;128:292-5.
- Kieu V, Palit S, Wilson G, et al. *Cervical spondylodiscitis following button battery ingestion*. *J Pediatr* 2014;164:1500-1500.e1.
- Brkić F, Umihanić Š. *Tracheobronchial foreign bodies in children: experience at ORL clinic Tuzla, 1954-2004*. *Int J Pediatr Otorhinolaryngol* 2007;71:909-15.
- Foltran F, Ballali S, Passali FM, et al. *Foreign bodies in the airways: a meta-analysis of published papers*. *Int J Pediatr Otorhinolaryngol* 2012;76:S12-9.
- Gregori D. *The Susy Safe Project. A web-based registry of foreign bodies injuries in children*. *Int J Pediatr Otorhinolaryngol* 2006;70:1663-4.
- Group SSW. *The Susy Safe Project*. 2005, Final Report.

- ¹¹ Group SSW. *The Susy Safe project overview after the first four years of activity*. Int J Pediatr Otorhinolaryngol 2012;76(Suppl 1):S3-11.
- ¹² Slapak I, Passali FM, Gulati A, et al. *Non food foreign body injuries*. Int J Pediatr Otorhinolaryngol 2012;76(Suppl 1):S26-32.
- ¹³ Jayachandra S, Eslick GD. *A systematic review of paediatric foreign body ingestion: presentation, complications, and management*. Int J Pediatr Otorhinolaryngol 2013;77:311-7.
- ¹⁴ Rybojad B, Niedzielska G, Niedzielski A, et al. *Esophageal foreign bodies in pediatric patients: a thirteen-year retrospective study*. Scientific World Journal 2012;2012:102642.
- ¹⁵ Sarafoleanu C, Ballali S, Gregori D, et al. *Retrospective study on Romanian foreign bodies injuries in children*. Int J Pediatr Otorhinolaryngol 2012;76(Suppl 1):S73-5.
- ¹⁶ Chinski A, Foltran F, Gregori D, et al. *Foreign bodies in the oesophagus: the experience of the Buenos Aires Paediatric ORL Clinic*. Int J Pediatr Volume 2010 (2010), Article ID 490691.
- ¹⁷ Foltran F, Gregori D, Passali D, et al. *Toys in the upper aerodigestive tract: evidence on their risk as emerging from the ESFBI study*. Auris Nasus Larynx 2011;38:612-7.
- ¹⁸ Foltran F, Passali FM, Berchiolla P, et al. *Toys in the upper aerodigestive tract: new evidence on their risk as emerging from the Susy Safe Study*. Int J Pediatr Otorhinolaryngol 2012;76(Suppl 1):S61-6.
- ¹⁹ Yusof AM, Millar AJ. *Food foreign body injuries*. Int J Pediatr Otorhinolaryngol 2012;76(Suppl):S20-5.
- ²⁰ Oncel M, Sunam GS, Ceran S. *Tracheobronchial aspiration of foreign bodies and rigid bronchoscopy in children*. Pediatr Int 2012;54:532-5.
- ²¹ Göktas O, Snidero S, Jahnke V, et al. *Foreign body aspiration in children: field report of a German hospital*. Pediatr Int 2010;52:100-3.
- ²² Sih T, Bunnag C, Ballali S, et al. *Nuts and seed: a natural yet dangerous foreign body*. Int J Pediatr Otorhinolaryngol 2012;76(Suppl 1):S49-52.
- ²³ Tander B, Kirdar B, Aritürk E, et al. *Why nut? The aspiration of hazelnuts has become a public health problem among small children in the central and eastern Black Sea regions of Turkey*. Pediatr Surg Int 2004;20:502-4.
- ²⁴ Balci AE, Eren S, Eren MN. *Esophageal foreign bodies under cricopharyngeal level in children: an analysis of 1116 cases*. Interact Cardiovasc Thorac Surg 2004;3:14-8.
- ²⁵ Even L, Heno N, Talmon Y, et al. *Diagnostic evaluation of foreign body aspiration in children: a prospective study*. J Pediatr Surg 2005;40:1122-7.
- ²⁶ Gregori D, Morra B, Berchiolla P, et al. *Foreign bodies in the ears causing complications and requiring hospitalization in children 0–14 age: results from the ESFBI study*. Auris Nasus Larynx 2009;36:7-14.
- ²⁷ Gregori D, Salerni L, Scarinzi C, et al. *Foreign bodies in the upper airways causing complications and requiring hospitalization in children aged 0–14 years: results from the ESFBI study*. Eur Archiv Otorhinolaryngol 2008;265:971-8.
- ²⁸ Strickland, M, Rosenfield D, Fecteau A. *Magnetic foreign body injuries: a large pediatric hospital experience*. J Pediatr 2014;165:332-5.
- ²⁹ Tavarez MM, Saladino RA, Gaines BA, et al. *Prevalence, clinical features and management of pediatric magnetic foreign body ingestions*. J Emerg Med 2013;44:261-8.
- ³⁰ Brown JC, Otjen JP, Drugas GT. *Pediatric magnet ingestions: the dark side of the force*. Am J Surg 2014;207:754-9.
- ³¹ Litovitz T, Whitaker N, Clark L. *Preventing battery ingestions: an analysis of 8648 cases*. Pediatrics 2010;125:1178-83.
- ³² McConnell MK. *When button batteries become breakfast: the hidden dangers of button battery ingestion*. J Pediatr Nurs 2013;28:e42-9.
- ³³ Brumbaugh DE, Colson SB, Sandoval JA, et al. *Management of button battery-induced hemorrhage in children*. J Pediatr Gastroenterol Nutr 2011;52:585-9.

Received: May 24, 2015 - Accepted: June 18, 2015

AUDIOLOGY

Does the addition of a second daily session of hyperbaric oxygen therapy to intratympanic steroid influence the outcomes of sudden hearing loss?

L'aggiunta di una seconda sessione giornaliera di camera iperbarica al trattamento steroideo intratimpanico influenza i risultati terapeutici nella sordità improvvisa?

G. ATTANASIO¹, E. COVELLI¹, L. CAGNONI¹, E. MASCI¹, D. FERRARO¹, P. MANCINI¹, E. ALESSANDRI², G. CARTOCCI¹, R. FILIPO¹, M. ROCCO³

¹ Department of Sensory Organs, Sapienza Università di Roma, Rome, Italy; ² Department of Cardiovascular, Respiratory, Nephrologic and Geriatric Sciences, "Umberto I" Hospital, Sapienza Università di Roma, Italy; ³ Pain Unit, Department of Medical-Surgical, Techno-Biomedical Sciences and Translational Medicine, Sapienza Università di Roma, "Sant'Andrea Hospital", Rome, Italy

SUMMARY

The aim of this study is to investigate whether, in addition to intratympanic steroid therapy, additional hyperbaric oxygen therapy (HBOT) sessions per day (twice a day for 5 days) is more useful than one session per day for 10 days in patients affected by severe and profound idiopathic sudden sensorineural hearing loss (ISSNHL). A total of 55 patients affected by unilateral severe and profound ISSNHL were recruited. Two protocols were adopted. In the first, 27 patients (13 with profound and 14 with severe hearing loss) underwent one session of HBOT per day for 10 days, 6 days a week. An HBOT session comprised a period of 14 minutes air compression followed by 90 min at 2.4 atm absolute (ATA) followed by a decompression period of 15 min in oxygen. Patients breathed 100% oxygen through an appropriate mask checked for leaks. Patients were given 0.4 ml of 62.5 mg/ml of intratympanic prednisolone during the first three days of the protocol. In the second protocol, 28 patients (10 with profound and 18 with severe hearing loss) received 10 sessions of HBOT, twice a day for five days, 2.4 ATA 90 min 100% oxygen. The intratympanic injections of prednisolone were given between the two sessions of HBOT during the first three days of the protocol. Since there were no significant differences in hearing outcomes between the two protocols, the present study shows that the protocol of two sessions of HBOT per day is a valid treatment and equally effective as the one HBOT session per day, but with shorter treatment time.

KEY WORDS: Deafness • Prednisolone • Hypoxia • Pure-tone average • Cochlea • Inner ear

RIASSUNTO

La finalità dello studio è stata quella di investigare se, in pazienti affetti da ipoacusia improvvisa di grado severo e profondo, un numero maggiore di sedute giornaliere di ossigenoterapia iperbarica (due volte al giorno per 5 giorni) in associazione alla terapia steroidea intratimpanica, risultati più efficace della tradizionale sessione giornaliera di ossigenoterapia iperbarica effettuata per 10 giorni. 55 pazienti affetti da ipoacusia idiopatica unilaterale severa e profonda sono stati reclutati nello studio. Sono stati utilizzati due diversi protocolli terapeutici: il primo è consistito di 27 pazienti (13 con ipoacusia improvvisa profonda e 14 con ipoacusia improvvisa severa) che sono stati sottoposti ad una sessione di camera iperbarica giornaliera per un totale di 10 giorni (sei giorni a settimana). La sessione di camera iperbarica è consistita in un periodo di 14 minuti di compressione in aria seguiti da un periodo di trattamento a 2,4 atmosfere assolute (ATA) per 90 minuti e poi ad un successivo periodo di decompressione di 15 minuti in ossigeno. I pazienti hanno respirato ossigeno al 100% attraverso un'apposita maschera. Ai pazienti è stata somministrata una dose intratimpanica di 0.4 ml di prednisolone a 62,5 mg/ml durante i primi tre giorni del protocollo. Il secondo protocollo è consistito di 28 pazienti (10 con ipoacusia profonda e 18 con ipoacusia severa) che hanno ricevuto 10 trattamenti di camera iperbarica 2 volte al giorno 2,4 ATA, 90 minuti con ossigeno al 100%. Le infiltrazioni intratimpaniche di prednisolone sono state effettuate nel tempo intercorrente tra le due sessioni giornaliere di camera iperbarica durante i primi tre giorni del protocollo. Lo studio, non avendo evidenziato alcuna significativa differenza in termini di risultati uditivi tra i due protocolli sperimentali, permette di considerare il protocollo con la doppia sessione giornaliera di camera iperbarica una valida alternativa alla sessione unica giornaliera garantendo una significativa riduzione della durata complessiva della terapia.

PAROLE CHIAVE: Sordità • Prednisolone • Ipossia • Pure-tone average • Coclea • Orecchio interno

Introduction

Idiopathic sudden sensorineural hearing loss (ISSNHL) is defined by the US National Institute for Deafness and Communication Disorders as a decline in hearing over 3 days or less, affecting three or more contiguous audiometric frequencies by 30 dB or more, with no identifiable aetiology¹. The treatment of patients with ISSNHL varies at different otological centres, but corticosteroids are considered the gold standard therapy².

In the literature a number of different regimens have been proposed as therapy for ISSNHL including vasodilators, anticoagulants, antioxidants, plasma expanders, antiviral agents, H.E.L.P. apheresis, carbogen and corticosteroids³⁻⁵. Hyperbaric oxygen therapy (HBOT) is also used in ISSNHL to increase the partial oxygen pressure and to improve the blood profile and microcirculation. Solubility of gases in liquids depends on pressure, and during HBOT, due to the increased external pressure, a much larger amount of oxygen enters the blood from the alveoli. Blood with a higher concentration of oxygen crossing from the thin alveolar walls is transported through the bloodstream to all parts of the body. The more dissolved oxygen is in the blood, the better it gets into the organs and tissues^{6,7}.

In 2002 Aslan et al. demonstrated the efficacy of one daily HBOT session in addition to conventional treatment modalities for ISSNHL⁸. In 2012, the efficacy of one daily session of HBOT was demonstrated in association with short duration intratympanic steroid therapy (ITS) in patients affected by severe and profound ISSNHL known to be less responsive to systemic steroid treatment⁹.

It is also known that an increase in hyperbaric sessions per day significantly improves soft tissue and bone recovery, wound healing, infection control, ulcers and compromised flap recovery^{10,11}. In 2011, Thom et al. demonstrated that HBOT can mobilize bone marrow stem cells by stimulating nitric oxide synthase. It was found that nitric oxide synthase activity is acutely increased in platelets following HBOT that remained elevated for at least 20 hours. HBOT stimulates vasculogenic stem cell mobilization from bone marrow of diabetics, and more cells are recruited to skin wounds¹².

The aim of this study is to investigate whether, in addition to ITS, a higher number of HBOT sessions per day (twice a day for 5 days) is more useful than one session per day for 10 days in patients affected by severe and profound ISSNHL.

Materials and methods

A total of 55 patients affected by unilateral severe and profound ISSNHL who were examined by the ENT Emergency Room staff of the Department of Sensory Organs of Sapienza Università di Roma from Janu-

ary 2012 to December 2013 were enrolled in this randomised pilot study. Severe ISSNHL is defined by a pure-tone average (PTA) between 70 and 90 dB and profound ISSNHL by a PTA > 90 dB. All patients met the following inclusion criteria: age between 19 and 85 years, time elapsed between the onset of ISSNHL and beginning of therapy not exceeding 15 days, no previous therapy for ISSNHL, no surgery affecting the ipsilateral ear and no retrocochlear disease, no acoustic trauma and no autoimmune or fluctuating hearing loss. The exclusion criteria were: chronic bronco-pulmonary obstructive syndrome, emphysema, sinusitis, seizure syndrome, pregnancy and claustrophobia in a hyperbaric environment. Informed written consent was obtained from each patient.

Treatment strategies

Two protocols were adopted. The first (HBOT1) consisted of 27 patients (13 with profound and 14 with severe sudden hearing loss) who underwent one session of HBOT per day for 10 days in a multi-place hyperbaric chamber, 6 days a week. A HBOT session comprised a period of 14 min compression in air followed by a treatment period at 2.4 atm absolute (ATA) for 90 min and then a decompression period of 15 min in oxygen. Patients breathed 100% oxygen through an appropriate mask checked for leaks. Patients were given 0.4 ml of 62.5 mg/ml of intratympanic prednisolone (Deltacortene Sol® Bruno Farmaceutici, Rome, Italy) before the HBOT session during the first three days of the protocol. The IT injection technique has been reported¹³.

The second protocol (HBOT2) consisted of 28 patients (10 with profound and 18 with severe sudden hearing loss) who received 10 sessions of HBOT, twice a day for five days, 2.4 ATA 90 min 100% oxygen in a multi-place hyperbaric chamber. Intratympanic injections of prednisolone were given between the two sessions of HBOT during the first three days of the protocol. Within each protocol, patients were homogenous according to age, sex and PTA.

Standard assessment

The standard assessment includes audiometric testing PTA and impedance audiometry, vestibular tests, routine serological test, coagulation, high resolution CT of temporal bone and MRI of the brain (specifically of the cerebellopontine angle with gadolinium).

Audiological evaluation and hearing improvement

All patients underwent evaluation of PTA immediately before the beginning of the treatment and one day after the last session of HBOT (11 days after HBOT1 treatment and 6 days after HBOT2). The results were compared. PTA was calculated as the mean of thresholds at the six frequencies (250, 500, 1000, 2000, 4000 and 8000 Hz).

Thresholds that could not be measured due to the limit of the audiometric equipment were “dummy coded” with the highest test level of audiometric equipment, as suggested in a recent study^{14,15}. In these cases they were set at 130 dB.

Criteria adopted for evaluating audiological improvement were based on those used by Furuhashi et al.¹⁶ who classified the outcomes as complete recovery, marked improvement, partial improvement, or non-recovery. Successful treatment is defined as complete recovery or marked improvement in PTA at six frequencies (250, 500, 1000, 2000, 4000 and 8000 Hz) (Table I).

Table I. Criteria used to define audiological improvement.

Hearing Outcome	Furuhashi's criteria
Complete recovery*	PTA ≤ 25 dB or identical to the contralateral, non-affected ear
Marked improvement*	PTA improvement > 30 dB
Slight improvement	PTA improvement between 10 and 30 dB
No recovery	PTA improvement < 10 dB

* Successful treatment: complete recovery and marked recovery.

Statistical analysis

Statistical analysis on PTA values was performed using ANOVA two-way repeated measurements. Bonferroni post-hoc test was performed for the analysis of statistically significant interactions. Unpaired *t*-test was performed in the comparison between the two groups in the pre-treatment phase. Fisher's exact test was performed in the comparison of treatment outcomes between and within groups (HBOT1 and HBOT2 severe and profound hearing loss).

Results

PTA

The frequency averages of patients treated with the two protocols, before and after the therapy, is shown in Figure 1.

Any statistically significant difference of PTA values was observed comparing the pre-treatment phase between the two groups HBOT1 and HBOT2 ($p = 0.17$).

In all patients the comparison of PTA before and after treatment showed a statistically significant reduction ($p < 0.0001$). The average PTA decreased for HBOT1 from 92.04 ± 18.6 to 62.65 ± 29.14 , and for HBOT2 from 85.53 ± 16.3 to 56.07 ± 29.19 with a statistical significance of $p < 0.001$ for each protocol (Fig. 2). Comparing the results within the severe and profound hearing loss group a statistically significant reduction of PTA was observed, while no significant difference regarding the two protocols was seen ($p = 0.27$) (Fig. 3).

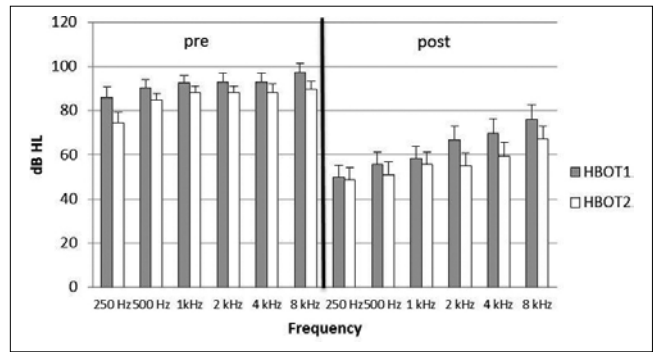


Fig. 1. Threshold average of frequencies in the patients treated with the two protocols. *Pre*: before therapy; *post*: at the end of therapy.

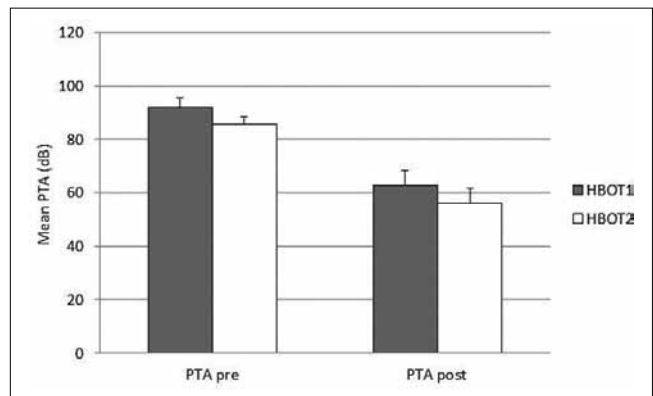


Fig. 2. Average PTA for each protocol before and after treatment.

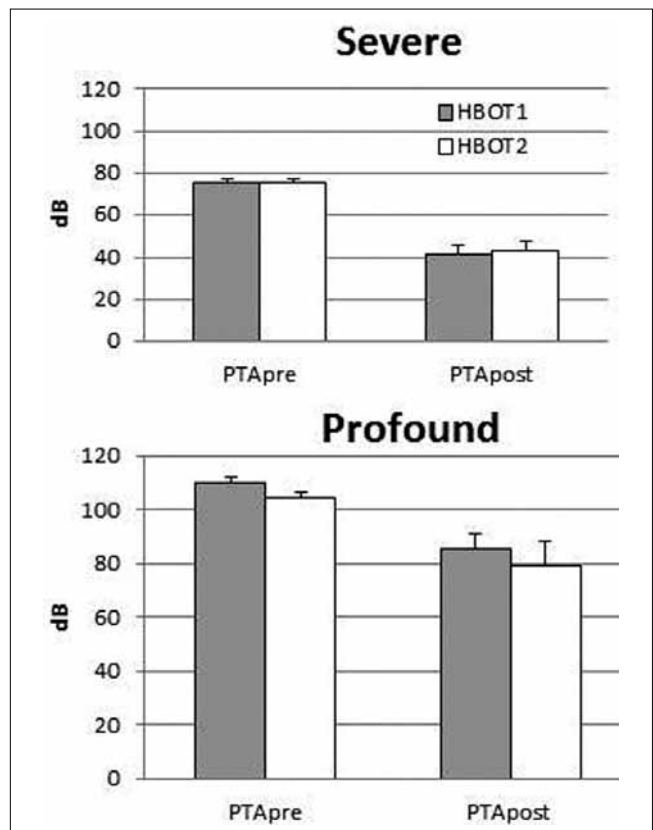


Fig. 3. Mean PTA based on the two protocols in profound and severe hearing loss.

Clinical evaluation of hearing outcomes

According to the audiological criteria of Furuhashi, there was no significant difference between the two protocols ($p = 0.58$) (Table II).

Table II. Audiological results according to Furuhashi's criteria.

Hearing outcomes (Furuhashi's criteria)	Severe SSNHL		Profound SSNHL	
	HBOT1 n = 14	HBOT2 n = 18	HBOT1 n = 13	HBOT2 n = 10
Successful treatment	10	14	6	5
Unsuccessful treatment	4	4	7	5

No significant differences were observed in the audiometric division in severe or profound hearing loss (severe $p = 0.7$; profound $p = 1$) and between the two experimental groups (HBOT1 $p = 0.25$; HBOT2 $p = 0.21$) (Fig. 4).

Discussion

In the last few years, ITS injection has been considered a good treatment for ISSNHL as it permits the greatest possible intra-cochlear concentration of cortisone, without the risk of adverse systemic effects, although the exact mechanism is still unclear. In the literature, ITS injection is favoured not also as a first line therapy, but also as salvage therapy¹⁷.

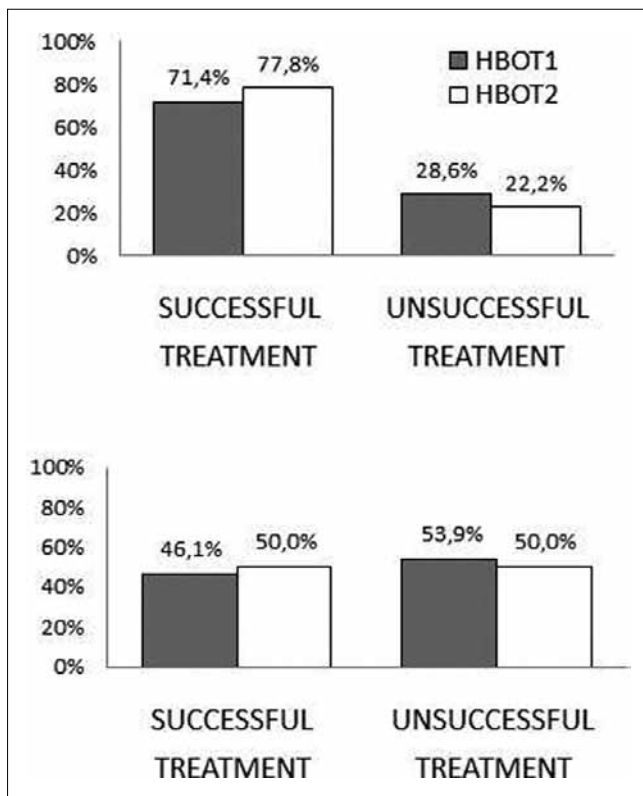


Fig. 4. Hearing outcomes following Furuhashi's criteria based on the two protocols in severe (top) and profound (bottom) hearing loss.

The logical basis for the use of HBOT in ISSNHL is linked to the pathogenetic hypothesis. Whatever the aetiology – vascular, viral, autoimmune, or metabolic – the final event triggering cochlear damage is always the same: hypoxia. Accumulation of CO₂ leads to anaerobic glycolysis, acidosis, tissue oedema, a further reduction of blood flow and ultimately to increasingly serious oxygen debt, with evident consequences on homeostasis of inner and outer hair cells and labyrinthine fluids. Furthermore, HBOT has been shown to provide a significant additional effect when used in combination with a steroid therapy for ISSNHL⁹.

To improve hearing outcomes in patients affected by ISSNHL, the present study proposed an increase in the frequency of HBOT sessions per day, as in the treatment of some other pathologies (crush syndrome, soft tissue infections, burns, etc.).

Regardless of the severity of the hearing loss, the results obtained show that patients with severe or profound hearing loss respond similarly to both protocols of ITS injection associated with one or two HBOT sessions per day. Considering the two protocols individually, both demonstrated the efficacy of the treatment for ISSNHL. The percentages of recovery and the values of PTA do not show any different effects with one session of HBOT per day or two, in combination with ITS.

Possible complications during HBOT include barotraumatic lesions (middle ear, nasal sinuses, inner ear, lung, teeth), oxygen toxicity (central nervous system, lung), confinement anxiety and ocular effects (myopia, cataract growth)¹⁸. There are also some potential disadvantages to ITS such as otitis media, transient vertigo, otomycosis, perforations of tympanic membrane, myringitis¹⁹ and pneumolabyrinth²⁰. In our study, no patient experienced these side effects.

Since there were no significant differences in hearing outcomes between the two regimens, the present study demonstrates that a protocol of two sessions of HBOT per day is a valid treatment and equally effective as the one HBOT session per day, with a shorter duration, and that it may also be less stressful and more acceptable for the patient. The protocol of two HBOT sessions per day could be more flexible and adaptable to the needs of patients.

References

- 1 National Institute of Health. *Sudden deafness*. Bethesda, MD: National Institute of Health NH publication; 2000. p. 4757.
- 2 Jarvis SJ, Giangrande V, John G, et al. *Management of acute idiopathic sensorineural hearing loss: a survey of UK ENT consultants*. Acta Otorhinolaryngol Ital 2011;31:85-9.
- 3 Schreiber BE, Agrup C, Haskard DO, et al. *Sudden sensorineural hearing loss*. Lancet 2010;375:1203-11.
- 4 G. Bianchin, G. Russi, N. Romano, et al. *Role of H.E.L.P.-apheresis in the treatment of sudden sensorineural hearing*

- loss in a group of 230 patients. *Acta Otorhinolaryngol Ital* 2011;31:395-8.
- ⁵ Filipo R, Attanasio G, Russo FY, et al. *Oral versus Short-Term Intratympanic Prednisolone Therapy for Idiopathic Sudden Hearing Loss*. *Audiol Neurotol* 2014;19:225-33.
- ⁶ Stachler RJ, Chandrasekhar SS, Archer SM, et al. *Clinical practice guideline: sudden hearing loss*. *Otolaryngol Head Neck Surg* 2012;146(3 Suppl):S1-35.
- ⁷ Goto F, Fujita T, Kitani Y, et al. *Hyperbaric oxygen and stellate ganglion blocks for idiopathic sudden hearing loss*. *Acta Otolaryngol* 1979;88:335-42.
- ⁸ Vincey P, Mechineau Y, Lafond P, et al. *Treatment of acute acoustic trauma. Comparative results of normovolemichemodilution*. *Rev Laryngol Otol Rhinol (Bord)* 1987;108:339-41.
- ⁹ Aslan I, Oysu C, Veyseller B, et al. *Does the addition of hyperbaric oxygen therapy to the conventional treatment modalities influence the outcome of sudden deafness?* *Otolaryngol Head Neck Surg* 2002;126:121-6.
- ¹⁰ Filipo R, Attanasio G, Viccaro M, et al. *Hyperbaric oxygen therapy with short duration intratympanic steroid therapy for sudden hearing loss*. *Acta Otolaryngol* 2012;132:475-81.
- ¹¹ Smolle-Jüttner FM, Pinter H, Neuhold KH, et al. *Hyperbaric surgery and oxygen therapy in clostridial myonecrosis*. *Wien Klin Wochenschr* 1995;107:739-41.
- ¹² Gustilo SJ, Mendoza RM, Williams DN. *Problems in the management of type III (severe) open fractures: a new classification of type III open fractures*. *J Trauma* 1984;24:742-6.
- ¹³ Thom SR, Milovanova TN, Yang M, et al. *Vasculogenic stem cell mobilization and wound recruitment in diabetic patients: increased cell number and intracellular regulatory protein content associated with hyperbaric oxygen therapy*. 2011;19:149-61.
- ¹⁴ Filipo R, Covelli E, Balsamo G, et al. *Intratympanic prednisolone therapy for sudden sensorineural hearing loss: A new protocol*. *Acta Otolaryngol* 2010;130:1209-13.
- ¹⁵ Plontke SK, Löwenheim H, Mertens J, et al. *Randomized, double blind, placebo controlled trial on the safety and efficacy of continuous intratympanic dexamethasone delivered via a round window catheter for severe to profound sudden idiopathic sensorineural hearing loss after failure of systemic therapy*. *Laryngoscope* 2009;119:359-69.
- ¹⁶ Chen CY, Halpin C, Rauch SD. *Oral steroid treatment of sudden sensorineural hearing loss: a ten year retrospective analysis*. *Otol Neurotol* 2003;24:728-33.
- ¹⁷ Furuhashi A, Matsuda K, Asahi K, et al. *Sudden deafness: long term follow-up and recurrence*. *Clin Otolaryngol* 2002;27:458-63.
- ¹⁸ Plaza G1, Herráiz C. *Intratympanic steroids for treatment of sudden hearing loss after failure of intravenous therapy*. *Otolaryngol Head Neck Surg* 2007;137:74-8.
- ¹⁹ Plafki C, Peters P, Almeling M, et al. *Complications and side effects of hyperbaric oxygen therapy*. *Aviat Space Environ Med* 2000;71:119-24.
- ²⁰ Covelli E, Attanasio G, Cagnoni L, et al. *Pneumolabyrinth after intratympanic steroid injection in patient with prosthesis of the stapes: a case report*. *Am J Otolaryngol* 2013;34:759-61.

Received: May 22, 2014 - Accepted: November 8, 2014

BASIC RESEARCH IN OTORHINOLARYNGOLOGY

Quantification of cells expressing markers of proliferation and apoptosis in chronic tonsillitis

Quantificazione delle cellule che esprimono i marcatori di proliferazione e apoptosi nelle tonsilliti croniche

V. AVRAMOVIĆ¹, V. PETROVIĆ¹, M. JOVIĆ¹, P. VLAHOVIĆ²

¹Institute of Histology and Embryology, Faculty of Medicine University of Niš, Serbia; ²Centre for Medical Biochemistry, Clinical Centre Niš, Serbia

SUMMARY

During chronic tonsillitis, the relationship between proliferation and apoptosis of lymphocytes in tonsillar follicles can be disturbed, which gives rise to attenuation of tonsil immunocompetence and diminishing its contribution in systemic immunity. In this study, we have quantified the cells expressing the markers of proliferation and apoptosis in the follicles of the palatine tonsil. Six tonsils from patients aged 10-29 years with hypertrophic tonsillitis and five tonsils from patients aged 18-22 years with recurrent tonsillitis were studied. The sections of paraffin blocks of tonsillar tissue were stained by the immunohistochemical LSAB/HRP method with the utilisation of antibodies for: Ki-67 antigen-cell marker of proliferation; Bcl-2 and survivin anti-apoptotic factors and Fas/CD95, caspase-3 and Bax pro-apoptotic factors. The size of lymphoid follicles, i.e. mean follicle area and number of lymphoid follicle immunopositive cells per mm² of a slice area, i.e. numerical areal density were determined by the quantitative image analysis. The localisation of Ki-67, Bcl-2, survivin, Fas/CD95, caspase-3 and Bax- immunopositive cells inside the palatine tonsil was similar in both types of tonsillitis. The number of Ki-67 immunopositive cells was significantly ($p < 0.01$) larger in the tonsils with hypertrophic tonsillitis (14681.4 ± 1460.5) in comparison to those with recurrent tonsillitis (12491.4 ± 2321.6), although the number of survivin and caspase-3 immunopositive cells was significantly ($p < 0.05$) larger in recurrent tonsillitis (survivin, 406.9 ± 98.4 ; caspase-3, 350.4 ± 119.4) when compared to those with hypertrophic tonsillitis (survivin, 117.4 ± 14.5 ; caspase-3, 210 ± 24). Our results show that the rate of the proliferation and apoptosis of follicular lymphocytes is different in various types of tonsillitis. This suggests that the immunological potential of the palatine tonsil varies in patients with hypertrophic and recurrent tonsillitis, which in practice poses a dilemma over the choice of conservative or surgical treatment.

KEY WORDS: Human palatine tonsil • Lymphoid follicle • Cell proliferation • Apoptosis • Quantification

RIASSUNTO

Durante una tonsillite cronica, il rapporto tra proliferazione e apoptosi dei linfociti nei follicoli tonsillari può essere alterato: ciò spiega l'attenuazione dell'immunocompetenza tonsillare e la riduzione del suo contributo all'immunità sistemica. In questo studio abbiamo quantificato le cellule che esprimono i marker di proliferazione e apoptosi nei follicoli delle tonsille palatine. Sono state studiate sei tonsille da pazienti di età compresa tra 10 e 29 anni con tonsillite ipertrofica e cinque tonsille da pazienti di età compresa tra 18 e 22 anni con tonsillite ricorrente. Le sezioni di tessuto tonsillare incluso in paraffina sono state colorate con il metodo immunoistochimico di LSAB/HRP attraverso l'applicazione di anticorpi per: l'antigene ki-67, marcatore cellulare di proliferazione; Bcl-2 e survivina, fattori antiapoptotici; Fas/CD95, caspasi 3 e Bax, fattori proapoptotici. La dimensione dei follicoli linfatici, ossia l'area del follicolo e il numero delle cellule immunopositive del follicolo per mm², ossia la densità numerica dell'area, sono state determinate attraverso una analisi quantitativa dell'immagine. La localizzazione delle cellule immunopositive a ki-67, Bcl-2, survivina, Fas/CD95, caspasi 3 e Bax all'interno della tonsilla palatina è stata simile nei due tipi di tonsillite. Il numero delle cellule immunopositive per Ki-67 è stato significativamente ($p < 0,01$) maggiore nelle tonsille con tonsillite ipertrofica ($14681,4 \pm 1460,5$) rispetto a quelle con tonsillite ricorrente ($12491,4 \pm 2321,6$), sebbene il numero di cellule immunopositive per survivina e caspasi 3 fosse significativamente ($p < 0,05$) maggiore nelle tonsilliti ricorrenti (survivina, $406,9 \pm 98,4$; caspasi-3, $350,4 \pm 119,4$) rispetto alle tonsille con tonsilliti ipertrofiche (survivina, $117,4 \pm 14,5$; caspasi-3, 210 ± 24). I nostri risultati mostrano che il tasso di proliferazione e apoptosi dei linfociti follicolari è diverso nei vari tipi di tonsillite. Questo indica che il potenziale immunologico della tonsilla palatina varia nei pazienti con tonsillite ipertrofica rispetto a quelli con tonsillite ricorrente: ciò, nella pratica, pone un dilemma in merito alla scelta del trattamento conservativo o chirurgico.

PAROLE CHIAVE: Tonsilla palatina • follicolo linfatico • proliferazione cellulare • Apoptosi • Quantificazione

Acta Otorhinolaryngol Ital 2015;35:277-284

Introduction

Human palatine tonsil is an organ of a local (mucous) and systemic immune response¹⁻⁴. Due to the specific location in the oropharynx and permanent antigen stimu-

lation, the human tonsil is subject to inflammatory processes that frequently turn chronic. According to clinical parameters and morphological substrate, Surjan et al.⁵ have defined two types of chronic tonsillitis in adult pa-

tients: hypertrophic tonsillitis (HT) and recurrent tonsillitis (RT).

The lymphoid follicles (B-dependent zone) of the human tonsil contain two morphologically and functionally different parts: germinal centre (GC) and mantle zone (MZ). The mantle zone is populated by B memory lymphocytes and GC contains centroblasts and centrocytes, representing the spot where proliferation, differentiation and clonal selection of antigen-stimulated B lymphocytes takes place⁶. Differentiation of stimulated B lymphocytes into B memory cells and plasma cells is precisely regulated by the cellular interaction among follicular B cells, CD4⁺ (Th2) cells and follicular dendritic cells (FDC)^{7,8}. Apoptosis represents one of the control mechanisms in the process of clonal selection of stimulated B lymphocytes, which protects the organism from created "low-grade" B cells^{9,10}. In particular, the follicular B cells that did not receive the signals for positive selection leave their cell cycle, undergo apoptosis¹¹⁻¹³ and are phagocytosed by follicular macrophages¹⁴.

In order to determine the role of the human palatine tonsil in the humoral immune response, Surjan et al.⁵ and Korsrud and Brandtzaeg¹⁵ were the first who quantified the immunoglobulin (Ig)-producing cells in human palatine tonsils with HT and RT, and found some differences related to the type of tonsillitis. Over the last two decades, a specific microenvironment of lymphoid follicles was defined by immunohistochemistry as the place of production of cell-stimulating cytokines¹⁶⁻¹⁸, presence of a variety of FDC subtypes¹⁹, expression of Fas receptors and Fas ligands (FasL)^{9,20} and caspase-3²¹; however, there is a small number of published works^{22,23} which have quantified the above mentioned factors using morphometric methods.

In recent years, there has been a growing interest in survivin, which is described as a member of the inhibitor of apoptosis protein family and an indicator of cell survival²⁴. Its expression has been observed in the cell nucleus, which confirms its role, primarily in the control of cell division^{25,26}.

In order to determine if there is a difference in the immune activity of the lymphoid follicles in chronic tonsillitis, we quantified the cells expressing biological markers of proliferation and apoptosis in the lymphoid follicles of human tonsils with HT and RT.

Materials and methods

Palatine tonsils were obtained at the ENT Clinic of Clinical Centre Niš from patients who had undergone elective tonsillectomy due to chronic tonsillitis, and were obtained from 5 patients aged 18-22 years (mean 20.3 years) with RT and 6 patients aged 10-29 years (mean 20.8 years) with HT. In their case histories, patients reported recurrent episodes of tonsillitis (more than four times a year for more than 1-2 years), which, in patients with HT were commonly associated with dysphagia due to enlarged tonsils.

After removal, only one tonsil from each patient was taken; all tonsils were routinely processed from paraffin blocks for light microscope study. Histopathological analysis was performed on 3-5 µm thick sections that had been routinely stained with H&E.

Immunohistochemistry

The immunohistochemical LSAB/HRP method was applied with antibodies for: (1) Ki-67 antigen (mouse monoclonal antibody, N1633, ready to use, DAKO, Denmark) for proliferative activity; (2) Bcl-2 protein (mouse monoclonal antibodies, M0887, DAKO, Denmark, dilution 1:100) and survivin (mouse monoclonal antibodies, M3624, DAKO, Denmark, dilution 1:100) for anti-apoptotic activity; and (3) Fas/CD95 receptor (rabbit polyclonal antibody, ab2437, Abcam, UK, dilution 1:10); caspase-3 (mouse monoclonal antibody, ab2171, Abcam, UK, dilution 1:200) and Bax protein (rabbit polyclonal antibody, A3533, DAKO, Denmark, dilution 1:1000) for apoptotic activity.

Immunohistochemistry was performed on 3-5 µm thick paraffin sections using 45-minute heat-induced epitope retrieval in 0.01 M citrate buffer at pH 6.0, followed by overnight incubation with the primary antibody at +4°C°. For visualisation, we used the LSAB2 system HRP (K0673, DAKO, Denmark). After staining with DAB, slides were counterstained with Mayer's haematoxylin, dehydrated through a graded ethanol series and mounted with Canada balsam.

Quantitative image analysis

Lymphoid follicles area and numerical areal density (N_A) of follicular immunopositive cells were determined by digital image analysis using Image J software (National Institutes of Health, Maryland, USA, <http://imagej.nih.gov/ij/>). The images were obtained on Leica DMR light microscope equipped with a digital camera (Leica Micro-Systems, Reuil-Malmaison, France). The objective × 4 was used for determination of the follicle area as well as germinal centre area, while × 40 was applied to determine the numerical areal density of follicular immunopositive cells, i.e. the average number of cells per mm² of tonsillar tissue.

For measuring lymphoid follicle surfaces, we examined all lymphoid follicles on three sections of each tonsil; the distance between the slices was 30 µm. For quantitative analysis of follicular immunopositive cells, 20 fields per slice (simple random sampling) were examined. Statistical analysis of the results was performed using the Mann-Whitney rank sum test.

Results

The lymphoid follicles in tonsils with HT contained hyperplastic GC and thinned MZ (Fig. 1a), while the lymphoid follicles in the tonsils with RT were small and the space

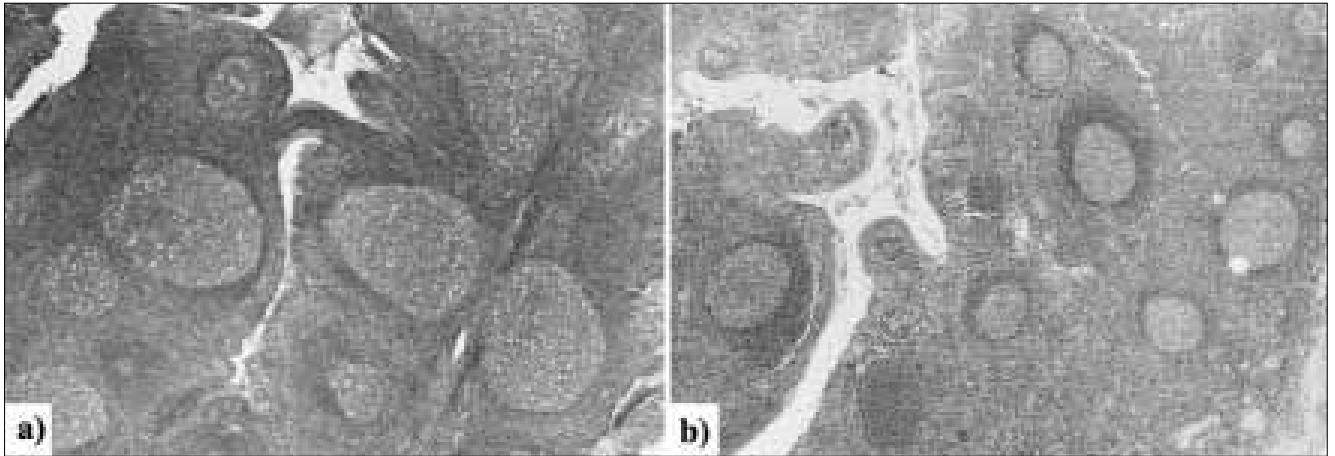


Fig. 1. Light micrograph of the palatine tonsil with: a) hypertrophic tonsillitis and b) recurrent tonsillitis. The pictures show the lymphoid follicles in which the pale-stained germinal centres and dark-stained mantle zones are visible. H&E $\times 100$.

between them, the interfollicular region, was dominant (Fig. 1b). The mean follicle area in HT ($0.38 \pm 0.17 \text{ mm}^2$) was significantly ($p < 0.05$) increased compared with RT ($0.28 \pm 0.12 \text{ mm}^2$). The measurement of the GC area showed significant ($p < 0.01$) differences between HT ($0.26 \pm 0.13 \text{ mm}^2$) and RT ($0.17 \pm 0.09 \text{ mm}^2$).

Ki-67 expression in lymphoid follicles

Follicular Ki-67-immunopositive cells (Fig. 2a) have similar localisation in both types of tonsillitis. The majority of Ki-67-immunopositive cells can be spotted in the dark zone of GC (Fig. 2b). They are also present to a lesser extent in the light zone of GC and in MZ. Numerical areal density (N_A) of Ki-67-immunopositive cells (Table I) was greater in tonsils with HT compared with RT, with a statistically significant ($p < 0.01$) difference for the dark zone of GC and MZ of lymphoid follicles.

Bcl-2 and survivin expression in lymphoid follicles

In both types of tonsillitis, Bcl-2-expressing cells were found primarily in MZ of lymphoid follicles (Fig. 2c, d). By quantitative analysis, we obtained a larger number of Bcl-2-expressing cells in RT, in comparison with HT, without statistical significance (Table I).

The expression of survivin (Fig. 2e) had typical nuclear localisation and the nuclei of the survivin immunopositive cells in GC displayed mitotic figures with strong delineation of chromosomes (Fig. 2f). By quantification of survivin-expressing cells, we obtained significantly higher values for GC of the lymphoid follicles in tonsils with RT in comparison with HT (Table I).

Fas/CD95, caspase-3 and Bax expression in lymphoid follicles

Fas/CD95 is expressed, mostly, by the cells of GC and smaller cells of MZ (Fig. 3a, b). In both types of tonsillitis

Table I. Number of lymphoid follicle cells per mm^2 of tonsillar slice area (N_A) in hypertrophic tonsillitis (HT) and recurrent tonsillitis (RT).

Antigen	Localisation	Numerical areal density (N_A)	
		HT (n = 6)	RT (n = 5)
Ki-67	Germinal centre dark zone	14,681.4 \pm 1460.5	12,491.4 \pm 2321.6**
	Germinal centre light zone	8014.4 \pm 1404.7	7844.2 \pm 1360.6
	Mantle zone	1406.9 \pm 393.1	1001 \pm 540.7**
Bcl-2	Germinal centre	Absent	Absent
	Mantle zone	10,856.4 \pm 1171.3	13,253.7 \pm 2226
Survivin	Germinal centre	117.4 \pm 14.5	406.9 \pm 98.4*
	Mantle zone	44.7 \pm 9.1	50.2 \pm 13.6
Fas/CD95	Germinal centre	291.1 \pm 73.5	285.6 \pm 94.7
	Mantle zone	85.9 \pm 31.5	116 \pm 21.9
Caspase-3	Germinal centre	210 \pm 24	350.4 \pm 119.4*
	Mantle zone	60.5 \pm 25	257.8 \pm 29.6*
Bax	Germinal centre	Scattered	Scattered
	Mantle zone	Absent	Absent

* $p < 0.05$ vs HT; ** $p < 0.01$ vs HT.

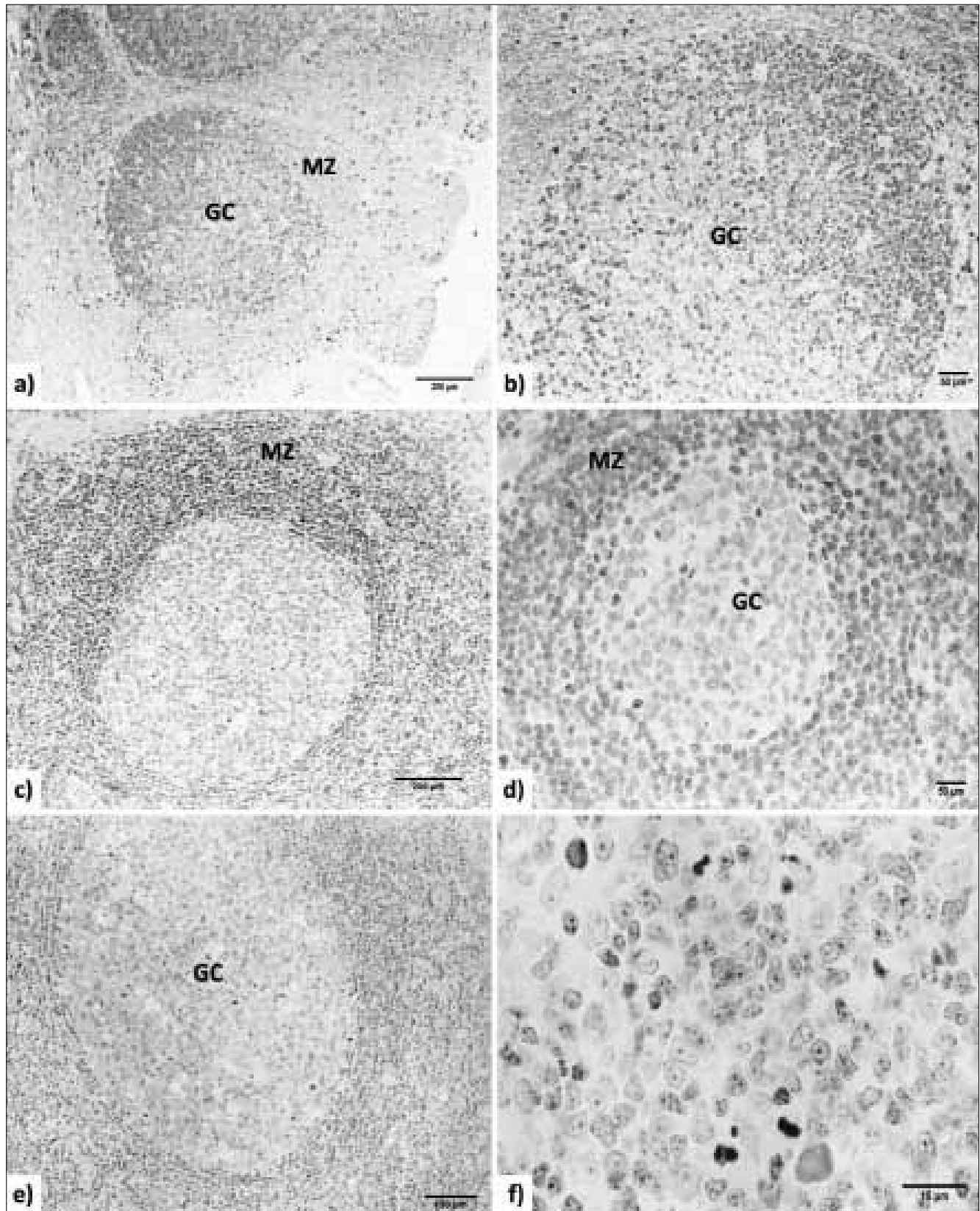


Fig. 2. Immunohistochemistry of proliferative and anti-apoptotic activity in tonsillar lymphoid follicles. LSAB/HRP method: a) Expression of Ki-67 in germinal centre (GC) and mantle zone (MZ) of lymphoid follicle ($\times 200$); b) Detail from the previous picture: Ki-67-immunopositive cells are the most numerous in the dark zone of germinal centre (GC) ($\times 400$); c) Bcl-2 protein is expressed by the cells of the follicular mantle zone (MZ), ($\times 200$); d) Absence of Bcl-2 expression in the germinal centre (GC) and strong expression in the mantle zone (MZ) is noticed ($\times 400$); e) Survivin-expressing cells are present in the germinal centre (GC) of the lymphoid follicle ($\times 100$); f) Survivin expression in a non-dividing cell (upper left corner) as well as the survivin-expressing cells with strongly stained mitotic figures (low central) are noticed ($\times 400$).

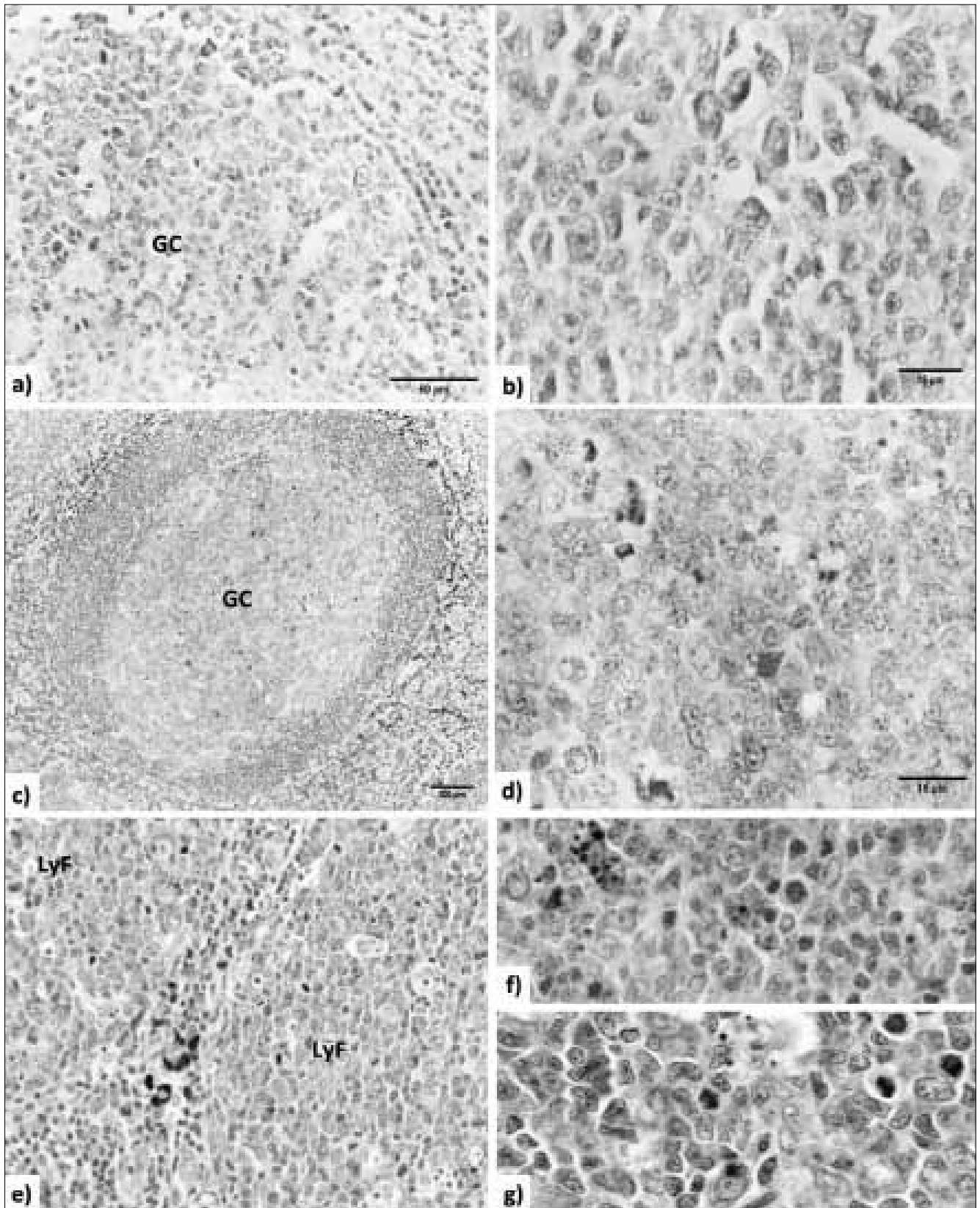


Fig. 3. Immunohistochemistry of apoptotic activity in tonsillar lymphoid follicles. LSAB/HRP method: a) A part of the lymphoid follicle germinal centre (GC) with numerous Fas/CD95- expressing cells ($\times 400$); b) Detail from the previous picture ($\times 1000$); c) Individual caspase-3- expressing cells in the germinal centre (GC), ($\times 100$); d) Detail from the previous picture: cytoplasm of the cell which morphologically corresponds to the follicular macrophage (upper left part), contains caspase-3 immunopositivity ($\times 1000$); e) Strong Bax immunopositivity can be seen between the two lymphoid follicles (LyF), and weak immunopositivity in germinal centre cells ($\times 400$); f) Germinal centre cells (upper lower part) show granular Bax immunopositivity, possibly phagocytosed apoptotic bodies ($\times 630$); g) In the lower part of the picture a cell with strong Bax immunopositivity can be seen ($\times 1000$).

there was the presence of a larger number of Fas/CD95-expressing cells in GC, comparing to MZ, but without any statistical difference (Table I).

In both types of tonsillitis, caspase-3 is detected in GC and MZ (Fig. 3c, d). The larger number of cells that express caspase-3 was seen in RT in comparison with HT (Table I).

Clear expression of Bax protein was observed in a few cells in the GC and on the border between the GC and MZ (Fig. 3e-g), with no differences in relation to the type of tonsillitis. Due to the small number of Bax-immunopositive cells, quantitative analysis was not performed.

Discussion

In this study, we have quantified the cells expressing the cell proliferation and cell death markers in the lymphoid follicles of the human palatine tonsil in two different entities of chronic tonsillitis: HT and RT.

The ultimate role of the GC of the lymphoid follicle is to differentiate B memory lymphocytes which express Ig-receptors with high affinity for binding to an antigen, and to differentiate into plasma cells secreting Ig with high affinity for a specific antigen³⁶. Some B cells do not allow antigen-specific B-cell responses, and as aberrant cells activate pro-apoptotic factors and die by apoptosis^{7 12 13}.

The cell marker of proliferation, Ki-67 protein²⁷, was the most strongly expressed in the dark zone of GC. A larger number of follicular Ki-67-immunopositive cells in HT clearly displays higher proliferative activity in the lymphoid follicles of tonsils with HT, compared to those with RT. Based on the data according to which FDC precursors are predominantly localised in the dark zone and highly differentiated FDC subtypes in the light zone of GC², and considering the localisation of Ki-67-immunopositive cells in our samples, we can assume that the highest proliferative activity of B lymphocytes in GC co-localises with precursors of FDC, whereas the lowest proliferative activity can be observed in the region corresponding to the localisation of differentiated FDC subsets. A fewer number of Ki-67-immunopositive cells in apical region of the light zone of GC is expected, because this part of GC is the place where selection of B cells occurs exclusively, with the help of corresponding subsets of FDC¹⁹. In our study, the higher GC proliferative activity in HT correlated with the GC surface values, which is in agreement with the results of Zhang et al.²⁸ who determined the size of the lymphoid follicles in HT and RT by the similar morphometric method.

The apoptosis inhibitor Bcl-2, together with pro-apoptotic factor Bax protein, controls transport through the pores on the external mitochondrial membrane by preventing the exit of cytochrome c from mitochondria and apoptosis initiation^{29 30}. Kondo and Yoshio¹³ recently reported that GC-cells do not display the expression of Bcl-2, whereas

cells in the MZ express a high level of Bcl-2. In our study, strong expression of Bcl-2 in MZ-cells, along with the absence of Bax expression, confirms that B memory cells in the MZ are highly differentiated cells that underwent a process of clonal selection and are protected from apoptosis by expression of Bcl-2 protein.

Studies of apoptosis in lymphoid organs have shown strong expression of Fas and FasL^{9 12}. Apart from that, the Fas/FasL signal is one of the best studied and described mechanisms of apoptosis, which is characteristic of various cell types including B lymphocytes in lymphoid follicles^{6 10 21 30}. By comparing the number of the cells expressing Fas/CD95 with the number of Bax-expressing cells in GC, we noticed domination of expression Fas/CD95, which shows that apoptosis in GC cells is initiated primarily by the extrinsic pathway of activation²⁴.

We demonstrated that tonsillar follicle cells express caspase-3, as described by Lukeš et al.²¹. It is necessary to point out that we found expression of caspase-3 in the cytoplasm of numerous cells that are morphologically related to follicular macrophages, which confirms the role of such cells in phagocytosis of apoptotic cells¹⁴ and supports the fact that proteolytic activity of caspase-3 takes place rapidly²⁴. Hence, it cannot always and in due time be noted in dying cells on histological preparations. The presence of caspase-3 expression and absence of Bcl-2 expression in GC are indicators of two diametrically opposed processes taking place in GC, namely cell death and cell survival.

Unlike previous studies that mostly relied on morphological identification and description of the localisation of Fas- and caspase-3-expressing cells, we morphometrically quantified these cells and found a significantly larger number of caspase-3-immunopositive cells in RT than in HT. Lopez-Gonzales et al.¹¹ previously pointed out that apoptotic parameters decreased in the tonsils with HT compared to those with RT. With respect to their data, as a verification of the validity of our results, more prominent apoptosis in the tonsils with RT can be explained by the greater production of inflammatory cytokines and their effect on immunological processes inside GC¹⁷.

A significantly smaller number of survivin-expressing cells in GC in HT suggests that its expression is independent of proliferative activity, yet it may be related to the expression of pro-apoptotic factors, i.e. with apoptosis. Our hypothesis is supported by the fact that intracytoplasmic localisation of survivin is associated with apoptosis inhibition through the degradation of caspase-3, caspase-7 and caspase-9^{31 32}. Considering our findings that both greater apoptotic activity and stronger expression of survivin were observed in lymphoid follicles of tonsils with RT, it is assumed that survivin is expressed in those cells which have already received some death signal and which attempt to prevent dying by stopping the cell cycle.

In this study, we have shown that proliferative activity of

cells in GC of lymphoid follicles is dominant in tonsils with HT in comparison to those with RT, and that, contrary to this, the cells in GC die by apoptosis at a higher rate in tonsils with RT than in those with HT. Moreover, the similar expression of Fas receptors in both types of tonsillitis confirms that activation of Fas receptors is the main signal for the initiation of apoptosis in the cells of GCs.

Conclusions

The relationship between the intensity of proliferative and apoptotic activities in tonsils with HT and RT is a good indicator of tonsil immunological potential, and can thus serve to better understand the immunological status of patients with various types of chronic tonsillitis. However, the knowledge of biological processes going on in the palatine tonsil is not yet sufficient to guide final decisions on how to best treat chronic tonsillitis, conservatively or surgically.

Acknowledgements

This study was supported by grant no. 175092 and grant no. 175061 from the Ministry of Education, Science and Technological Development of the Republic of Serbia.

References

- Perry M, Whyte A. *Immunology of the tonsils*. Immunol Today 1998;19:414-21.
- Nave H, Gebert A, Pabst R. *Morphology and immunology of the human palatine tonsil*. Anat Embryol (Berl) 2001;204:367-73.
- Brandtzaeg P. *Immunology of tonsils and adenoids: everything the ENT surgeon needs to know*. Int J Pediatr Otorhinolaryngol 2003;67:s69-76.
- Passàli D, Damiani V, Passàli GC, et al. *Structural and immunological characteristics of chronically inflamed adenotonsillar tissue in childhood*. Clin Diagn Lab Immunol 2004;11:1154-7.
- Surjan JR, Brandtzaeg P, Berdal P. *Immunoglobulin systems in human tonsils II. Patients with chronic tonsillitis or tonsillar hyperplasia: quantification of Ig-producing cells, tonsillar morphometry and serum Ig concentrations*. Clin Exp Immunol 1978;31:382-90.
- Guzman-Rojas L, Sims-Mourtada CJ, Rangel R, et al. *Life and death within germinal centres: a double-edged sword*. Immunology 2002;107:167-75.
- Johansson-Lindbom B, Ingvarsson S, Borrebaeck CA. *Germinal centers regulate human Th2 development*. J Immunol 2003;171:1657-66.
- Park CS, Choi YS. *How do follicular dendritic cells interact intimately with B cells in germinal centre*. Immunology 2005;114:2-10.
- Kuki K, Hotomi M, Yamanaka N. *A study of apoptosis in the human palatine tonsil*. Acta Otolaryngol Suppl 1996;523:68-70.
- Kondo E, Yoshino T, Nishiuchi R, et al. *Expression of Fas ligand mRNA in germinal centres of the human tonsil*. J Pathol 1997;183:75-9.
- López-González MA, Díaz P, Delgado F, et al. *Lack of lymphoid cell apoptosis in the pathogenesis of tonsillar hypertrophy as compared to recurrent tonsillitis*. Eur J Pediatr 1999;158:469-73.
- Kucera T, Páková H, Veselý D, et al. *Apoptosis and cell proliferation in chronic tonsillitis and oropharyngeal carcinoma: role of nitric oxide and cytokines*. Biomed Papers 2004;148:225-7.
- Kondo E, Yoshino T. *Expression of apoptosis regulators in germinal centers and germinal center-derived B-cell lymphomas: Insight into B-cell lymphomagenesis*. Pathol Int 2007;57:391-7.
- Schrijvers DM, De Meyer GR, Kockx MM, et al. *Comparison of apoptosis detection markers combined with macrophage immunostaining to study phagocytosis of apoptotic cells in situ*. Biomarker Insights 2007;1:193-200.
- Korsrud FR, Brandtzaeg P. *Immune systems of human nasopharyngeal and palatine tonsils: Histomorphometry of lymphoid components and quantification of immunoglobulin-producing cells in health and disease*. Clin Exp Immunol 1980;39:361-70.
- Butch AW, Chung GH, Hoffmann JW, et al. *Cytokine expression by germinal center cells*. J Immunol 1993;150:39-47.
- Toellner KM, Scheel-Toellner D, Sprenger R, et al. *The human germinal centre cells, follicular dendritic cells and germinal centre T cells produce B cell-stimulating cytokines*. Cytokine 1995;7:344-54.
- Komorowska A, Komorowski J, Banasik M, et al. *Cytokines locally produced by lymphocytes removed from the hypertrophic nasopharyngeal and palatine tonsils*. Int J Pediatr Otorhinolaryngol 2005;69:937-41.
- Steiniger B, Trabandt M, Barth PJ. *Follicular dendritic cell network in secondary follicles of human palatine tonsils and spleens*. Histochem Cell Biol 2011;135:327-36.
- Verbeke CS, Wenthe U, Zentgraf H. *Fas ligand expression in germinal centre*. J Pathol 1999;189:155-60.
- Lukeš P, Pacova H, Kučera T, et al. *Expression of endothelial and inducible nitric oxide synthase and caspase-3 in tonsillar cancer, chronic tonsillitis and healthy tonsil*. Folia Biologica (Praha) 2008;54:141-5.
- Garrity MM, Burgart LJ, Riehle DL, et al. *Identifying and quantifying apoptosis: Navigating technical pitfalls*. Mod Pathol 2003;16:389-94.
- Resendes AR, Majo N, Segales J, et al. *Apoptosis in normal lymphoid organs from healthy normal conventional pigs at different ages detected by TUNEL and cleaved caspase-3 immunohistochemistry in paraffin-embedded tissues*. Veterinary Immunol and Immunopathol 2004;99:203-13.
- Elmore S. *Apoptosis: A review of programmed cell death*. Toxicol Pathol 2007;35:495-516.
- Martinez A, Bellosillo B, Bosch F, et al. *Nuclear survivin expression in mantle cell lymphoma is associated with cell proliferation and survival*. Am J Pathol 2004;164:501-10.
- Stauber RH, Mann W, Knauer SK. *Prognostic and therapeutic nuclear and cytoplasmic surviving: Molecular mechanism*. Cancer Res 2007;67:5999-6002.

- ²⁷ Schluter C, Duchrow M, Wohlenberg C, et al. *The cell proliferation-associated antigen of antibody Ki-67: a very large, ubiquitous nuclear protein with numerous repeated elements, representing a new kind of cell cycle-maintaining proteins.* J Cell Biol 1993;123:513-22.
- ²⁸ Zhang PC, Pang YT, Loh KS, et al. *Comparison of histology between recurrent tonsillitis and tonsillar hypertrophy.* Clin Otolaryngol Allied Sci 2003;28:235-9.
- ²⁹ Portt L, Norman G, Clapp C, et al. *Anti-apoptosis and cell survival: A review.* Biochim Biophys Acta 2011;1813:238-59.
- ³⁰ Strasser A, Jost PJ, Nagata S. *The many roles of Fas receptor signaling in the immune system.* Immunity 2009;30:180-92.
- ³¹ Mita CA, Mita MM, Nawrocki ST, et al. *Survivin: Key regulator of mitosis and apoptosis and novel target for cancer therapeutics.* Cancer Res 2008;14:5000-5.
- ³² Altieri DC. *Survivin and IAP proteins in cell death mechanisms.* Biochem J 2010;430:199-205.

Received: August 3, 2014- Accepted: April 3, 2015

CLINICAL TECHNIQUES AND TECHNOLOGY

Correction of a mandibular asymmetry after fibula reconstruction using a custom-made polyetheretherketone (PEEK) onlay after implant supported occlusal rehabilitation

Correzione di asimmetria mandibolare a seguito di ricostruzione con fibula mediante protesi customizzata in polietheretherketone (PEEK) dopo riabilitazione protesica impianto supportata

M. BERRONE¹, C. ALDIANO², M. PENTENERO³, S. BERRONE⁴

¹Dept. of Oncology, PhD program in Experimental Medicine and Therapy, University of Turin, Italy; ²Dept. of Oncology, Oral Surgery Specialty School, University of Turin, Italy; ³Dept. of Oncology, Oral Medicine and Oral Oncology Unit, University of Turin, Italy; ⁴Dept. of Oncology, Professor of Maxillofacial Surgery, University of Turin, Italy

SUMMARY

This study describes an unusual case of mandibular asymmetry after fibula free flap reconstruction in a young man following major facial trauma that was corrected using a custom-made polyetheretherketone prosthesis. There is little information in the literature on the use of alloplasts to correct mandibular asymmetry as interest in 'aesthetic re-modelling' has traditionally focused on nasal, zygomatic and chin regions. This report demonstrates that this technique can be used successfully to address selected cases of mandibular asymmetry.

KEY WORDS: Virtual surgery • Mandibular reconstruction • Fibular free flap • Oromandibular reconstruction • Mandibular asymmetry

SUMMARY

Questo studio descrive un caso insolito di asimmetria mandibolare dopo ricostruzione con lembo libero di fibula in un giovane paziente a causa di un grave trauma facciale corretto mediante l'utilizzo di protesi custom-made in polyetheretherketone. C'è poco riportato in letteratura sull'utilizzo di protesi alloplastiche per correggere asimmetrie mandibolari; l'interesse per il rimodellamento estetico si è concentrato sulle regioni nasale, zigomatica e del mento. Questo caso dimostra che questa tecnica può essere utilizzata con successo per affrontare alcuni casi di asimmetria mandibolare.

PAROLE CHIAVE: Chirurgia virtuale • Ricostruzione mandibolare • Lembo libero di fibula • Ricostruzione oro-mandibolare • Asimmetria mandibolare

Acta Otorhinolaryngol Ital 2015;35:285-288

Introduction

The complexity of the three-dimensional anatomy of the oro-maxillo-facial region creates a genuine challenge for surgical reconstruction and correction of deformities. Advances in CAD-CAM technology have created an increasing number of applications for virtual surgical planning in oro-maxillo-facial surgery, such as stereolithographic models, preoperative planning¹, fabrication of cutting guides and manufacture of custom implants². The use of patient-specific implants (PSIs) should be considered as a viable option for the treatment of facial asymmetry. This report describes the surgical planning and technique, and aesthetic and functional outcomes of a custom-made pre-

fabricated PEEK PSI (Synthes GmbH, Oberdorf, Switzerland) using CAD-CAM for the correction of mandibular asymmetry after fibula free flap reconstruction.

Case report

A 27-year-old man was referred to our department for correction of facial asymmetry as a result of major trauma with loss of the hemi-mandible, which had been reconstructed with a fibula free flap 3 years earlier in another department (Fig. 1A-C). After implant positioning in the fibula and provisional dental restoration to stabilise the maxillo-mandibular relationship, 64-slice high resolution computed tomography (CT) scan of

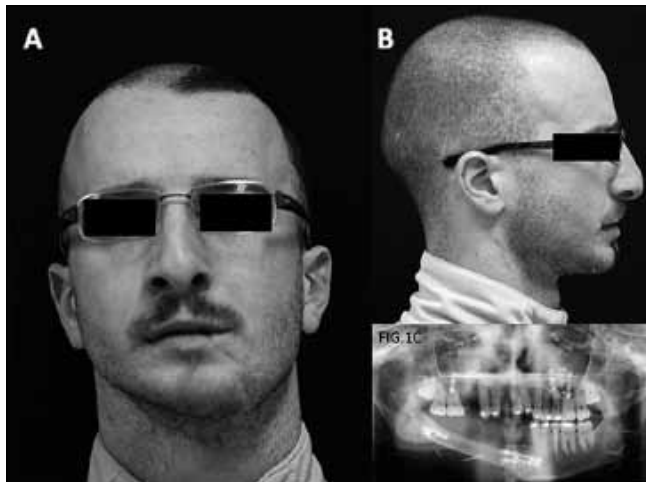


Fig. 1. Aesthetic outcome after fibula free flap reconstruction: frontal view (A), lateral view (B) and orthopantomography (C).

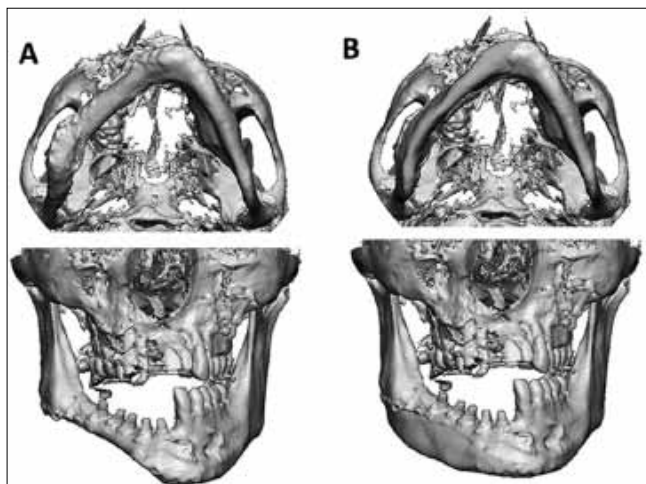


Fig. 2. 3D reconstruction of the craniofacial skeleton: actual inferior view and frontal view (A) virtual inferior view and frontal view after positioning of the custom-made prosthesis (B).

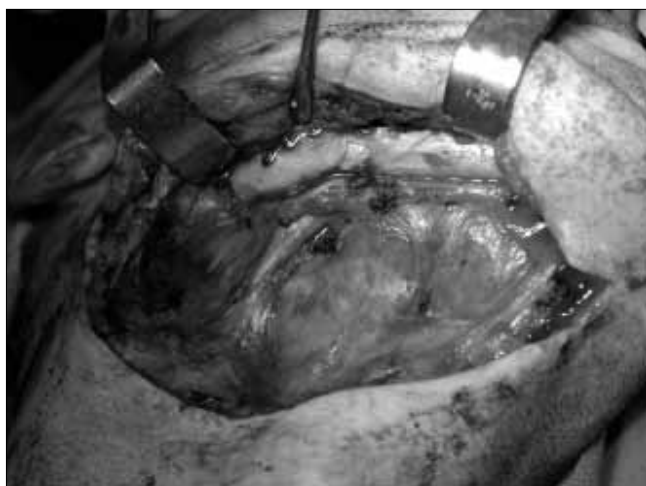

Fig. 3. Surgical technique: access to the mandible and identification of the vascular pedicle.

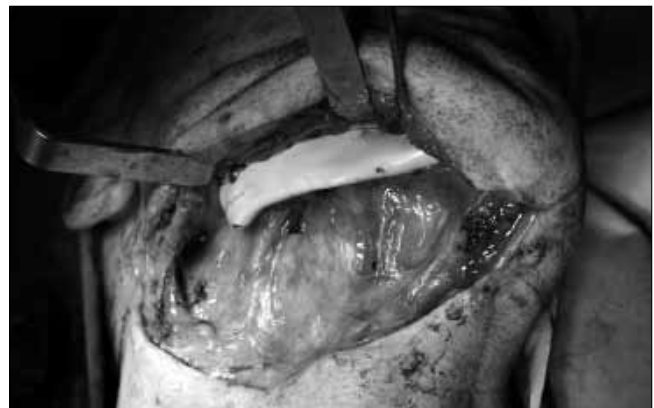

Fig. 4. Fixation of the custom-made prosthesis to the mandible.

the craniofacial skeleton was performed. 3D rendering based on the DICOM data was performed using CMF software 6.1 (Materialise, Leuven, Belgium), which produced a three-dimensional virtual model of the mandible. Using the mirroring technique, a patient-specific implant (PSI) was produced virtually to obtain optimal mandibular bone symmetry. 3D computer images of the defect (Fig. 2A), the implant and the implant fitted into the defect (Fig. 2B) were sent electronically for final approval by surgeons before manufacturing of the final custom-made prefabricated PEEK PSI (PEEK Optimal-LT onlay; Synthes). Under general anaesthesia, an extended submandibular approach was performed. After identification of the fibular vascular pedicle, the fascia was incised and the bone was exposed paying particular attention to try to eliminate any interference from soft tissues (Fig. 3). The final PSI fit on the bone was excellent and it was fixed with two 1.5 diameter screws, 15 mm in length (Fig. 4). The post-operative period was uneventful and the patient was discharged on the second day with antibiotic therapy (amoxicillin-clavulanic acid 1 g, three times a day for 8 days), and the cutaneous sutures were removed after 7 days. After 8 months of follow-up, there were no clinical or radiological complications (Fig. 5A, B).

Discussion

Today, mandibular reconstruction with a fibula free flap is considered to be the workhorse in head and neck surgery; however, vascular complications, infections, plate exposure, plate fracture, or vascular pedicle ossification can occur³. The introduction of computer-assisted mandibular reconstruction (CAMR) with the pivotal role of virtual surgical planning has increased the accuracy of pre-operative planning, leading to greater surgical precision, reduction in surgical time and an improved aesthetic result⁴. However, due to high costs, at present the most popular method used to restore correct mandibular segment po-

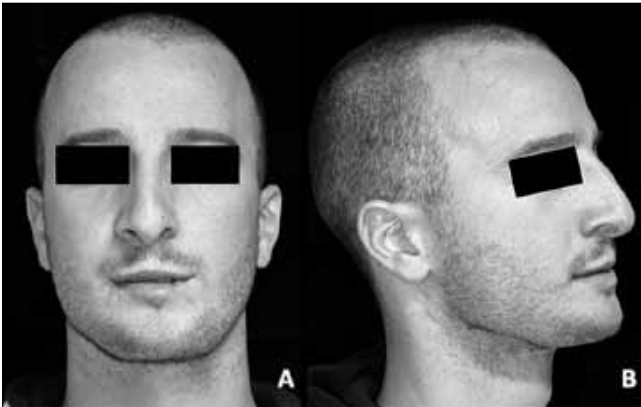

Fig. 5. Aesthetic outcome: frontal (A) and lateral view (B).

sitioning is the technique of pre-plating. In the literature, we can find many techniques described for pre-plating^{5,6} and mandibular non-tooth bearing segment repositioning⁷. Despite the accuracy of the pre-operative planning and surgical execution, mandibular reconstruction can sometimes result in a facial deformity or asymmetry. Treatment of mandibular asymmetries in patients who have undergone mandibular reconstruction, can pose a significant clinical problem. We have described a case of facial asymmetry secondary to mandibular lower profile and angle deficiency in a young man that was reconstructed with a fibula osteofascial flap after a major trauma corrected by the manufacture and placement of a PSI. Although alternative methods were potentially available to correct this deformity, patient factors including occlusion, dental/skeletal relationship and chin position limited our options. Furthermore, construction of the custom-made onlay involved the development of a computer-generated 3D virtual model and computer-aided design and computer-aided manufacture (CAD-CAM) of the onlay. There is little information in the literature on the use of alloplasts to correct mandibular asymmetry^{8,9}, as traditionally interest in ‘aesthetic re-modelling’ has focused on nasal, zygomatic and chin regions¹⁰⁻¹². Correction of mandibular asymmetry after reconstruction as well as oral rehabilitation with osseointegrated implants should be considered an integral part of the reconstructive process. In our opinion, in selected cases, the bone flap position for implant rehabilitation is more important than an excellent aesthetic outcome which then needs to be corrected at a later time using a PSI, as described herein. Bone height and position correction for successful implant rehabilitation is more difficult to achieve than aesthetic refinements, especially in irradiated patients who have undergone mandibular reconstruction for oral malignancies. Nowadays, virtual surgery allows fibular segments to be placed in the correct position for possible dental rehabilitation. Planning for implantation begins before surgery, and the positioning of final fibular segments

should also be programmed as a function of a possible dental rehabilitation with osseointegrated implants, which are often an integral part of mandibular reconstruction. In the authors’ experience, it is very important to perform, when possible, the most precise reconstruction for both aesthetic and future functional outcomes. Occlusal stability is a key point that must be achieved before aesthetic evaluation and a corrective program; fibula free flap implant supported rehabilitation is considered to be the best choice. Considering the concept of ‘two arches’ in mandibular reconstruction as described by Chen et al.¹³, on many occasions and for many reasons, this concept translates into a compromise choice where necessary additional secondary corrections can then be made, as in the case described. In this case, we used a custom-made PEEK Optima-LT onlay (Synthes). PEEK is a semi-crystalline thermoplastic with excellent mechanical and chemical resistance properties that are retained at high temperatures. It is considered to be an advanced biomaterial used in medical implants engineered for strength, stability and biocompatibility. This material is radiolucent (minimal MRI artefact) with bone-like stiffness and strength, and is very light weight compared to other implants. Moreover, it is autoclavable and withstands repeated sterilisation. After 8 months of follow-up, there were no clinical or radiological problems.

In conclusion, the aesthetic result and perfect bone-prosthesis contact demonstrate how computer aided design and computer aided manufacture are becoming increasingly important in surgery, especially in the oro-maxillo-facial region.

References

- Roser SM, Ramachandra S, Blair H, et al. *The accuracy of virtual surgical planning in free fibula mandibular reconstruction: Comparison of planned and final results.* J Oral Maxillofac Surg 2010;68:2824-32.
- Gerbino G, Bianchi FA, Zavattoni E, et al. *Single-step resection and reconstruction using patient-specific implants in the treatment of benign cranio-orbital tumors.* J Oral Maxillofac Surg 2013;71:1969-82.
- Tarsitano A, Sgarzani R, Betti E, et al. *Vascular pedicle ossification of free fibular flap: is it a rare phenomenon? Is it possible to avoid this risk?* Acta Otorhinolaryngol Ital 2013;33:307-10.
- Succo G, Berrone M, Battiston B, et al. *Step-by-step surgical technique for mandibular reconstruction with fibular free flap: application of digital technology in virtual surgical planning.* Eur Arch Otorhinolaryngol 2015;272:1491-501.
- Marchetti C, Bianchi A, Mazzoni S, et al. *Oromandibular reconstruction using a fibula osteocutaneous free flap: four different “preplating” techniques.* Plast Reconstr Surg 2006;118:643-51.
- Pellini R, Mercante G, Spriano G. *Step-by-step mandibular reconstruction with free fibula flap modeling.* Acta Otorhinolaryngol Ital 2012;32:405-9.

- ⁷ Berrone M, Crosetti E, Succo G. *Repositioning template for mandibular reconstruction with fibular free flaps: an alternative technique to pre-plating and virtual surgical planning*. *Acta Otorhinolaryngol Ital* 2014;34:278-82.
- ⁸ Yates JM, Wildgoose DG, van Noort R. *Correction of a mandibular asymmetry using a custom-made titanium onlay*. *J Plast Reconstr Aesthet Surg* 2009;62:e247-50.
- ⁹ Watson J, Hatamleh M, Alwahadni A, et al. *Correction of facial and mandibular asymmetry using a computer aided design/computer aided manufacturing prefabricated titanium implant*. *J Craniofac Surg* 2014;25:1099-101.
- ¹⁰ Goodson ML, Farr D, Keith D, et al. *Use of two-piece polyetheretherketone (PEEK) implants in orbitozygomatic reconstruction*. *Br J Oral Maxillofac Surg* 2012;50:268-9.
- ¹¹ Lai JB, Sittitavornwong S, Waite PD. *Computer-assisted designed and computer-assisted manufactured polyetheretherketone prosthesis for complex fronto-orbito-temporal defect*. *J Oral Maxillofac Surg* 2011;69:1175-80.
- ¹² Frodel JL Jr. *Computer-designed implants for fronto-orbital defect reconstruction*. *Facial Plast Surg* 2008;24:22-34.
- ¹³ Chen YS, Hu KY, Lin TW. *The concept of "two arches" in mandibular reconstruction*. *Ann Plast Surg* 2012;69:616-21.

Received: January 15, 2015 - Accepted: February 4, 2015

CASE SERIES AND REPORTS

Parapharyngeal metastases from thyroid cancer: surgical management of two cases with minimally-invasive video-assisted technique

Metastasi dello spazio parafaringeo da carcinoma della tiroide: trattamento chirurgico di due casi con tecnica video-assistita mini-invasiva

L. GIORDANO, F. PILOLLI, S. TOMA, M. BUSSI

Otorhinolaryngology Unit, Head and Neck Department, "San Raffaele" Hospital and Vita-Salute University, Milano, Italy

SUMMARY

Metastases to parapharyngeal or retropharyngeal lymph nodes are rare in well-differentiated thyroid cancers. A review of English literature found only 112 cases reported in the last two decades, with an incidence of parapharyngeal lymph nodes metastases ranging from 0.43 to 2.5%. Surgical resection is the most effective treatment for patients with parapharyngeal lymph node metastasis from thyroid carcinoma. We describe two cases of thyroid cancer parapharyngeal lymph node metastases that were surgically removed using a traditional transcervical approach, with the help of a minimally-invasive video-assisted technique. A video-assisted minimally-invasive transcervical approach is a new technique for excision of sizable benign tumours and selected malignant tumours. The endoscopic technique allows clear identification of critical surgical landmarks that guide the dissection through the correct cleavage plane in a nearly bloodless surgical field, thus decreasing the rate of complications. In both patients postoperative follow-up showed no sequelae and recurrence after 20 and 15 months from surgery.

KEY WORDS: Thyroid cancer • Parapharyngeal space metastases • Video-assisted transcervical approach

RIASSUNTO

Le metastasi dei tumori tiroidei ben differenziati nello spazio parafaringeo o nei linfonodi retrofaringei rappresentano una rara condizione. La nostra revisione della letteratura documenta solo 112 casi descritti negli ultimi vent'anni, con una incidenza di metastasi parafaringee che si attesta tra lo 0,43 e il 2,5%. Il trattamento di scelta di tali secondarismi è rappresentato dall'exeresi chirurgica. In questo lavoro descriviamo due casi di metastasi parafaringee da carcinoma papillare della tiroide trattati chirurgicamente mediante un approccio trans-cervicale associato all'ausilio di una tecnica video-assistita mini-invasiva. L'approccio trans-cervicale mini-invasivo video-assistito è una nuova tecnica che trova indicazione nell'exeresi di tumori benigni e di selezionati tumori maligni dello spazio parafaringeo. La tecnica endoscopica permette una chiara identificazione dei punti di repere e dei piani di clivaggio, consentendo una meticolosa dissezione in un campo chirurgico quasi esangue. La metodica risulta pertanto gravata da un ridotto tasso di complicanze post-operatorie con uguale radicalità oncologica. In entrambi i pazienti il follow-up post-operatorio non ha mostrato sequele né segni di recidiva a distanza di 20 e 15 mesi dall'intervento.

PAROLE CHIAVE: Carcinoma tiroideo • Metastasi dello spazio parafaringeo • Approccio trans-cervicale video-assistito

Acta Otorhinolaryngol Ital 2015;35:289-292

Introduction

Well-differentiated thyroid cancers are characterised by a 20-50% rate of regional lymph node metastases¹, which are usually found in the internal jugular and recurrent laryngeal chain^{2,3}. Metastases to retropharyngeal lymph nodes (RPLN) or parapharyngeal lymph nodes (PPLN) are rare. To the best of our knowledge, only 112 cases of PPLN and RPLN metastases have been reported during the last two decades, and the reported incidence of PPLN metastases of well-differentiated thyroid cancers varies widely, from 0.43% to 2.5%⁴⁻⁶.

Complete surgical removal is the only curative treatment

in such cases^{4,7}. We describe two cases of thyroid cancer PPLN metastases that were surgically removed using a traditional transcervical approach with the help of a minimally-invasive video-assisted technique to improve the limited working space.

Case reports

In the past 10 years, 2 patients underwent surgical treatment for PPLN thyroid papillary carcinoma metastases at San Raffaele Scientific Institute in Milan, Italy. Both patients were female and had no symptoms related to the parapharyngeal masses.

Case 1

A 53-year-old Caucasian woman presented with a complex history of papillary thyroid carcinoma diagnosed in April 1987. The patient had undergone right hemithyroidectomy with selective neck dissection (levels II-IV and VI) in another hospital. Histopathological analysis demonstrated a pT2 PN1a papillary thyroid carcinoma. In the same year, completion total thyroidectomy was performed on the left lobe. Radioactive iodine treatment (RAI) was then performed one year later. In June 2000, the patient underwent revision of the III right Robbin's level for a single nodal relapse, followed by RAI. In 2011, a new recurrence was suspected due to elevated thyroglobulin. Positron emission tomography (PET) – computed tomography showed a right parapharyngeal area of increased glucose uptake. Contrast-enhanced MRI demonstrated a 36-14-19 mm well-circumscribed heterogeneous mass in the right parapharyngeal retrostyloid space that compressed the internal carotid artery, without infiltration. Transcervical fine needle aspiration cytology (FNAC) performed on the parapharyngeal mass was strongly suggestive for metastasis of papillary thyroid carcinoma.

The lesion was treated with radiotherapy (70 Gy) from October 2011 to December 2011. In February 2012, PET imaging and MRI demonstrated persistence of the mass. In April 2012, the patient was finally referred to our centre. We performed a right transcervical approach to the parapharyngeal space with a 56 mm skin incision. Under direct endoscopic visualisation, using 0° and 30° Hopkin's telescopes, the tumour was carefully separated from surrounding tissues. Tumour excision was performed following an extracapsular dissection plane upwards and circumferentially. The tumour was removed en bloc. The drain was removed on postoperative day 4 and the patient was discharged the day after. No complications were observed. Histopathological diagnosis was papillary thyroid carcinoma metastasis.

The patient underwent postoperative RAI. MRI and scintigraphy have shown no evidence of tumour recurrence at 20 months after surgery.

Case 2

In October 2012, a 42-year-old woman was referred to our centre for multiple right neck lymph nodal metastases and right PPLN localisation of papillary thyroid carcinoma. In March 2012, the patient had undergone subtotal thyroidectomy for papillary thyroid carcinoma (pT1b cN0) in another centre. In September 2012, a cervical swelling was noted and FNAC suggested the presence of papillary thyroid carcinoma. Subsequent MRI showed multiple pathological lymph nodes in levels II, III, IV and VI on the right side, along with residual thyroid tissue in the right tracheo-oesophageal space in close contact with the aberrant right subclavian artery (luscian artery), and a right parapharyngeal mass.

A long 140 mm incision was performed to obtain wide surgical access. Revision thyroidectomy was technically complex due to the tight adhesions between the residual thyroid tissue, the oesophagus and the aberrant subclavian artery. Right selective neck dissection of levels II, III, IV and VI was performed. The PPLN was excised with the assistance of a video-endoscope. The 2 drains were removed on postoperative day 3 and the patient was discharged the day after. No postoperative complications were observed. Post-operative MRI follow-up has shown no evidence of tumour recurrence at 15 months after surgery.

Discussion

The potential for PPLN and RPLN metastatisation of oropharyngeal and hypopharyngeal carcinomas is well known, although PPLN and RPLN thyroid carcinoma metastatisation is a rare occurrence. Desuter et al.⁴ reported that only 0.43% (3/696) of thyroid papillary carcinomas had parapharyngeal node metastasis. Wang et al.⁶ presented 25 PPLNs tumours in a series of 5381 thyroid cancers (0.43%). As described by Kainuma⁸, recurrent cases of RPLN or PPLN metastasis are predominant.

Wang et al.⁶ reported the largest single centre series of RPLN and PPLN metastases (25 patients, 22 papillary carcinomas, 2 medullary carcinomas, and 1 follicular carcinoma). They identified 3 types of presentation of PPLN metastases:

1. nodal relapse in PPLN after previous surgical treatment (16/25, 64%);
2. cervical and parapharyngeal node involvement as the initial presentation of thyroid carcinoma (5/25, 20%);
3. PPLN metastasis as the only nodal involvement at first diagnosis (4/25, 16%).

The authors emphasised that, in the first two types of presentation, neck dissection and/or widespread cervical lymph node metastases might alter the direction of lymphatic drainage, and increase retropharyngeal drainage resulting in PPLN metastasis.

In 1938, the anatomist Rouvier⁹ described a lymphatic connection between the upper pole of the thyroid and the retropharyngeal lymphatic system, which occurred in one fifth of the cadaver dissection specimens he analysed. This lymphatic vessel was called the postero-superior collecting vessel. The retropharyngeal space communicates with the parapharyngeal space (PPS) through a dehiscence of the superior constrictor fascia, permitting potential lymphatic spread from the RPLN into the PPLN. These observations provide a satisfactory explanation for PPLN metastasis from occult thyroid carcinomas¹⁰.

Since parapharyngeal metastases are usually asymptomatic and difficult to examine clinically, all patients with thyroid cancer who have previously undergone neck dissection or who have widespread cervical lymph node metastases should be studied with accurate preoperative head and neck imaging. Ultrasonography can define thy-

roid disease and lymphadenopathy of the neck, but it cannot investigate the parapharyngeal and retropharyngeal spaces. Contrast-enhanced CT scan can show characteristic features such as a cystic mass or calcifications in the PPS⁶, but it is not normally recommended due to associated delay in I-131 therapy. Magnetic resonance contrast enhanced imaging is not routinely performed, but it avoids the limitations inherent to iodinated contrast agents.

The anatomic complexity of the PPS space has led to the development of various surgical approaches: transcervical, transparotid, transmanibular, transoral, and orbitozygomatic-middle fossa approach¹¹. The transcervical approach was first described in 1964 by Ballantyne¹². In patients with isolated and small (< 2.5 cm) metastases, a transoral approach using ultrasound guidance or the da Vinci surgical robotic system can offer adequate oncological resection and adequate prevention of complications¹³.

Since the first endoscopic approaches in thyroid surgery^{14 15}, video-assisted procedures are improving functional and aesthetic outcomes in head and neck surgery. This technique was used successfully in submandibular sialoadenectomy¹⁶, in parathyroid gland sialoadenectomy¹⁷, in parathyroidectomy¹⁸ and for neck dissection¹⁹.

In this report, we describe two cases of rare parapharyngeal metastasis from thyroid carcinoma treated with a minimally-invasive video-assisted transcervical approach to support a traditional open technique. According to the

NCCN guidelines for thyroid carcinoma²⁰, we usually perform neck dissection in case of suspected lymph node metastases documented by ultrasound and/or cytology, and in lymph nodal metastases palpable at surgical exploration for tumours greater than 4 cm or with extracapsular extension. The first endoscopic PPS approach was published in 2010 for drainage of paediatric abscess²¹. Subsequent reports were published with transoral²² and transcervical²³ endoscopic approaches for benign PPS tumours. Traditional transcervical approaches allow very limited surgical exposure: the parapharyngeal space is located 4-5 cm deep to the cervical incision and surgeon works in a deep, dark and narrow tunnel. Digital exploration and digitoclasia are helpful, but visual control is not possible during these interventions.

The goal of our video-endoscopy assisted technique was to evaluate the advantages of endoscopic visualisation of the PPS rather than to obtain the best cosmetic result. Moreover, 0° and angled telescopes can support an open traditional approach by allowing constant monitoring of the relationship between the PPS mass and surrounding vessels or cranial nerves, adding a minimal amount of extra surgical time. The close visual control and the image magnification allow the surgeon to precisely follow the tumour surface and facilitate recognition of the correct cleavage plane.

Our video-assisted technique simplifies the identification of small vessels, allowing accurate haemostasis. Furthermore, when using a suction-dissector it is possible to

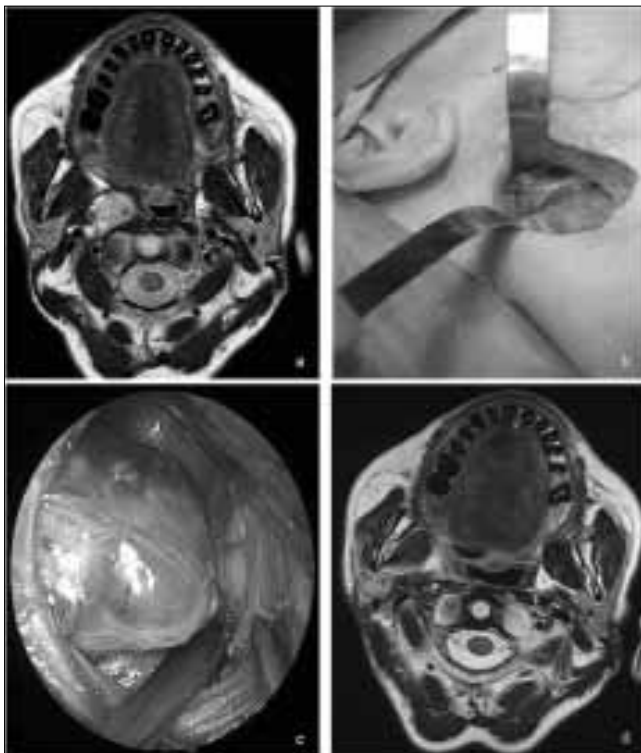


Fig. 1. Preoperative MRI (a), right transcervical approach with a short skin incision (b), endoscopic extracapsular tumour dissection (c), 20 months after surgery MRI (d).

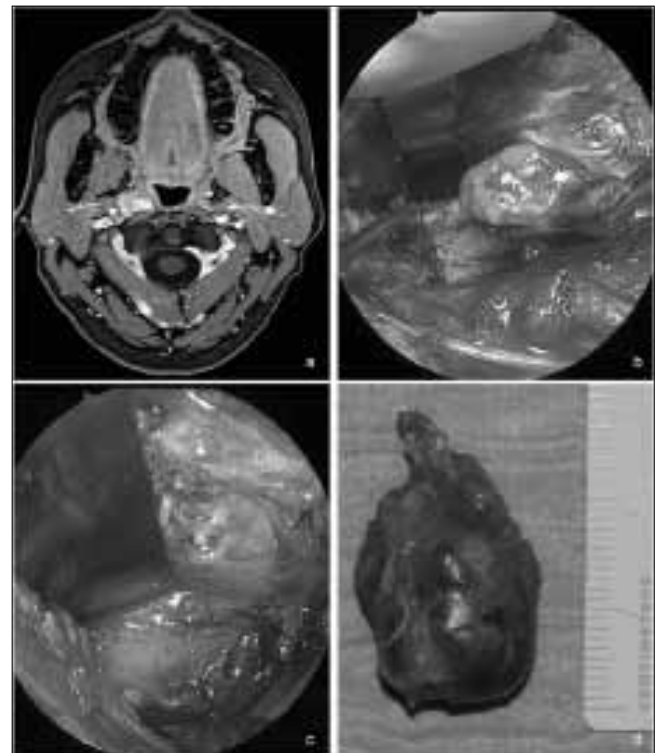


Fig. 2. Preoperative MRI (a), video-assisted right parapharyngeal mass dissection (b), endoscopic view after tumour excision (c), excised tumour (d).

work in a near-bloodless surgical field, due to one-hand simultaneous or alternate dissection and aspiration. Early or late minor or major sequelae were not observed in either of the present cases.

Conclusion

Presence of parapharyngeal metastases should be considered at the time of diagnosis of thyroid carcinoma, even if their occurrence is rare. In addition, differential diagnosis of a mass in the PPS should include metastasis from occult thyroid carcinoma. Ultrasonography of the neck cannot properly investigate parapharyngeal and retropharyngeal spaces, and for this reason CT or MRI are mandatory, especially in patients with widespread cervical lymph node metastatisation or with a history of prior neck dissection. A video-assisted minimally-invasive transcervical approach is a new technique for excision of sizable benign tumours and selected malignant tumours. The technique allows clear identification of critical surgical landmarks that guide the dissection through the correct cleavage plane in a nearly bloodless surgical field, thus decreasing the rate of complications.

References

- 1 Som PM, Brandwein M, Lidov M, et al. *The varied presentations of papillary thyroid carcinoma cervical nodal disease: CT and MR findings*. AJNR Am J Neuroradiol 1994;15:1123-8.
- 2 Yüce I, Çağlı S, Bayram A, et al. *Regional metastatic pattern of papillary thyroid carcinoma*. Eur Arch Otorhinolaryngol 2010;267:437-41.
- 3 Giugliano G, Proh M, Gibelli B, et al. *Central neck dissection in differentiated thyroid cancer: technical notes*. Acta Otorhinolaryngol Ital 2014;34:9-14.
- 4 Desuter G, Lonneux M, Plouin-Gaudon I, et al. *Parapharyngeal metastases from thyroid cancer*. Eur J Surg Oncol 2004;30:80-4.
- 5 Qiu Z-L, Xu Y-H, Song H-J, et al. *Localization and identification of parapharyngeal metastases from differentiated thyroid carcinoma by 131I-SPECT/CT*. Head Neck 2011;33:171-7.
- 6 Wang X-L, Xu Z-G, Wu Y-H, et al. *Surgical management of parapharyngeal lymph node metastasis of thyroid carcinoma: a retrospective study of 25 patients*. Chin Med J (Engl) 2012;125:3635-9.
- 7 Spriano G, Ruscito P, Pellini R, et al. *Pattern of regional metastases and prognostic factors in differentiated thyroid carcinoma*. Acta Otorhinolaryngol Ital 2009;29:312-6.
- 8 Kainuma K, Kitoh R, Yoshimura H, et al. *The first report of bilateral retropharyngeal lymph node metastasis from papillary thyroid carcinoma and review of the literature*. Acta Otolaryngol 2011;131:1341-8.
- 9 Rouvier H. *Anatomy of the human lymphatic system*. Ann Arbor, MI: Edwards Brothers; 1938.
- 10 Saydam L, Kalcioğlu T, Demirkiran A, et al. *Occult papillary thyroid carcinoma presenting as a parapharyngeal metastasis*. Am J Otolaryngol 1999;20:166-8.
- 11 Sergi B, Limongelli A, Scarano E, et al. *Giant deep lobe parotid gland pleomorphic adenoma involving the parapharyngeal space. Report of three cases and review of the diagnostic and therapeutic approaches*. Acta Otorhinolaryngol Ital 2008;28:261-5.
- 12 Ballantyne AJ. *Significance of retropharyngeal nodes in cancer of the head and neck*. Am J Surg 1964;108:500-4.
- 13 Andrews GA, Kwon M, Clayman G, et al. *Technical refinement of ultrasound-guided transoral resection of parapharyngeal/retropharyngeal thyroid carcinoma metastases*. Head Neck 2011;33:166-70.
- 14 Shimizu K. *Minimally invasive thyroid surgery*. Best Pract Res Clin Endocrinol Metab 2001;15:123-37.
- 15 Gottlieb A, Sprung J, Zheng XM, et al. *Massive subcutaneous emphysema and severe hypercarbia in a patient during endoscopic transcervical parathyroidectomy using carbon dioxide insufflation*. Anesth Analg 1997;84:1154-6.
- 16 Meningaud J-P, Pitak-Arnop P, Bertrand J-C. *Endoscope-assisted submandibular sialoadenectomy: a pilot study*. J Oral Maxillofac Surg 2006;64:1366-70.
- 17 Li B, Zhang L, Zhao Z, et al. *Minimally invasive endoscopic resection of benign tumours of the accessory parotid gland: an updated approach*. Br J Oral Maxillofac Surg 2013;51:342-6.
- 18 De Crea C, Raffaelli M, Traini E, et al. *Is there a role for video-assisted parathyroidectomy in regions with high prevalence of goitre?* Acta Otorhinolaryngol Ital 2013;33:388-92.
- 19 Lombardi CP, Raffaelli M, Princi P, et al. *Minimally invasive video-assisted functional lateral neck dissection for metastatic papillary thyroid carcinoma*. Am J Surg 2007;193:114-8.
- 20 National Comprehensive Cancer Network. *National Comprehensive Care Network Guidelines for Thyroid Cancer*, 2014.
- 21 Lee C-H, Lee T-J, Chen C-W. *Transnasal endoscopic approach for drainage of pediatric parapharyngeal space abscess*. Otolaryngol Head Neck Surg 2010;143:467-8.
- 22 Chiang TY, Chen MK. *Endoscope-assisted transoral excision of a huge parapharyngeal pleomorphic adenoma*. B-ENT 2011;7:143-6.
- 23 Beswick DM, Vaezi A, Caicedo-Granados E, et al. *Minimally invasive surgery for parapharyngeal space tumors*. Laryngoscope 2012;122:1072-8.

Received: June 12, 2014 - Accepted: November 24, 2015

Address for correspondence: Leone Giordano, Otorhinolaryngology Unit, "San Raffaele" Hospital, via Olgettina 60, 20132 Milan, Italy. Tel. +39 02 26433522. Fax +39 02 26433508. E-mail: giordano.leone@hsr.it

CASE SERIES AND REPORTS

Giant pleomorphic adenoma of the parotid gland: an unusual case presentation and literature review

Adenoma pleomorfo gigante della ghiandola parotide: caso clinico e revisione della letteratura

A. TARSITANO, A. PIZZIGALLO, F. GIORGINI, C. MARCHETTI

Maxillofacial Surgery Unit, Policlinico "S. Orsola-Malpighi", "Alma Mater Studiorum", University of Bologna, Italy

SUMMARY

Pleomorphic adenoma is the most common type of all salivary gland tumours. Although uncommon, cases of giant pleomorphic adenomas have been described in the medical literature, the majority involving the parotid gland. This paper describes an unusual case of a giant adenoma arising in the parotid gland. The patient underwent surgical resection of the giant tumour, which was one of the largest pleomorphic adenoma reported in recent literature. This case has prompted us to evaluate the behaviour of those benign tumours, which suggested that aesthetic and social morbidity is sufficient to justify, when possible, early tumour excision, despite the relatively low risk of malignant transformation. Management of this unusual tumour is discussed, and the literature on giant parotid tumours is reviewed.

KEY WORDS: Giant pleomorphic adenoma • Parotid tumours • Neck mass

RIASSUNTO

L'adenoma pleomorfo rappresenta il più comune isotipo tumorale interessante le ghiandole salivari. Quantunque non siano comuni, la letteratura medica internazionale ha descritto alcuni rari casi di adenoma pleomorfo gigante. La maggior parte di essi era di origine parotide. Questo articolo vuole descrivere un inusuale caso di adenoma gigante di origine parotide. La crescita abnorme che la massa tumorale ha avuto in questo caso, ne ha determinato la discesa per gravità verso il torace del paziente. Il paziente è stato sottoposto ad exeresi chirurgica del tumore, che è apparso essere uno dei più voluminosi adenomi pleomorfi riportati nella letteratura recente. Questo atipico caso ci ha portato a riflettere in merito al comportamento clinico di siffatte forme tumorali benigne. È evidente come le morbidità estetiche e sociali siano sufficienti a giustificare, quando possibile, una precoce asportazione del tumore, malgrado il relativamente basso rischio di trasformazione maligna. Di seguito discuteremo la gestione clinica e chirurgica di questo raro caso. Forniremo inoltre una revisione della letteratura in merito.

PAROLE CHIAVE: Adenoma pleomorfo gigante • Tumori parotidici • Tumefazioni cervicali

Acta Otorhinolaryngol Ital 2015;35:293-296

Introduction

About 70% of all salivary gland tumours arise in the parotid gland, and approximately 85% are benign; of these, 80% are pleomorphic adenoma¹. These tumours are almost uniformly characterised by a slow-growing, painless mass, usually varying from 2 to 6 cm in diameter when resected². In 4% of cases, tumours may be malignant.

Cases of giant pleomorphic adenomas have been reported in the parotid gland, presenting as an irregular multinodular mass that can weigh more than 8 kg³. Most cases of giant adenomas were seen before the 1980s, but some have been published recently⁴. Given the relative ease of diagnosis of pleomorphic adenomas based on clinical and cytological findings, and the low risk of ma-

lignant degeneration, some authors have an expectant management policy for those patients who do not desire surgery¹. This is in contrast to traditional management, which emphasises that "aggressive treatment of primary and recurrent mixed tumours is necessary"⁵ due to their malignant potential.

This paper describes an unusual case of a giant pleomorphic adenoma arising in the parotid gland, along with the reasons for diagnostic delay. This case prompted us to evaluate the behaviour of benign tumors that do not undergo malignant transformation. This case and others like it demonstrate that aesthetic and social morbidity is sufficient to justify, when possible, early tumour excision, despite the relatively low risk of malignant transformation.

Case report

An 83-year-old Caucasian man complained of a slow-growing mass on the left side of his face for more than 30 years. The patient's social history was significant for the events surrounding dismissal from work. The patient lived alone, isolated from his family, and was homeless. He denied knowledge of any past illness, but admitted to not having seen a physician for more than 30 years. He affirmed that the mass had begun to develop about 30 years ago, and had slowly enlarged without symptoms. Since that time he refused any interaction with his family and healthcare providers.

The patient came to our attention when the mass has become too large to allow normal walking. After a week of frequent visits, we finally gained the patient's confidence and took over his management.

Clinical examination showed a giant, firm, multinodular, irregular and painless mass measuring approximately 35 cm x 28 cm, involving the left parotid and cervical region (Fig. 1). The arrangement of the mass along the chest had the typical appearance of a beard.

Despite of the large dimension of the mass, there were no signs of facial nerve palsy, and the skin that covered the lesion did not present ulcerated areas. CT scan and magnetic resonance angiography were performed to evaluate the extent of the mass (Fig. 2). The lesion had an arterial blood supply from the facial artery and venous drainage in the internal jugular vein (Fig. 3). The main hypothesis for diagnosis was a benign tumour of the parotid gland, most likely pleomorphic adenoma.

Incisional biopsy was performed and confirmed the suspicion of adenoma.

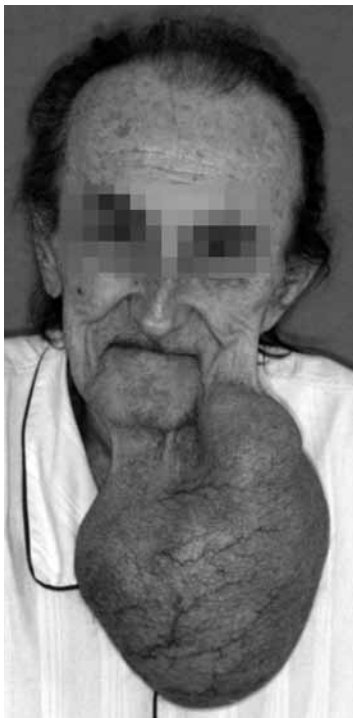

Fig. 1. The patient at initial examination, showing a large, multinodular left neck mass extending from the parotid region onto the chest.

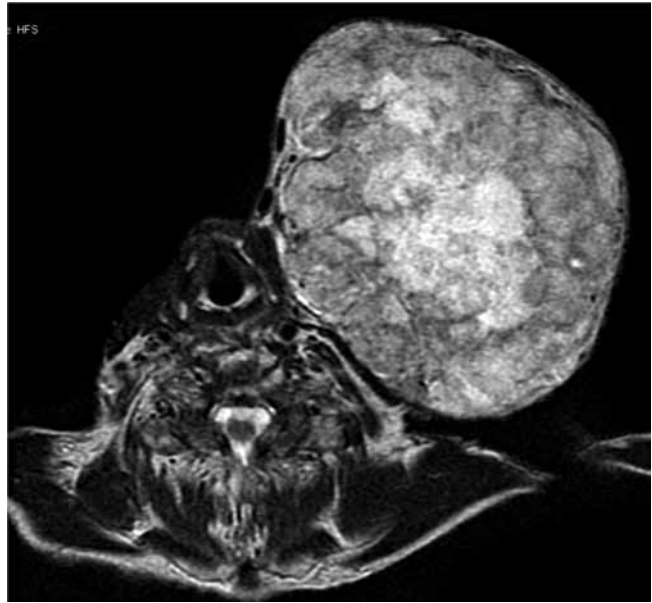

Fig. 2. Pre-operative imaging evaluation. MRI showing the giant mass. The outline of the heterogeneous lesion is clearly demarcated, and tissue planes preserved.

The tumour was excised under general anaesthesia. Despite the size of the mass, a clear plane of dissection was found. The sternocleidomastoid muscle was greatly hypertrophied, and the tumour displaced it posteriorly. Due to many years of traction, the mass had descended well below the angle of the mandible and the facial nerve was avoided without difficulty. Skin flaps were raised off the sides of the mass to provide sufficient tissue for neck closure. The post-operative course was uneventful.

Macroscopically, the excised mass measured 33 cm x 27 cm x 16 cm and weighed 7.3 kg (Fig. 4).

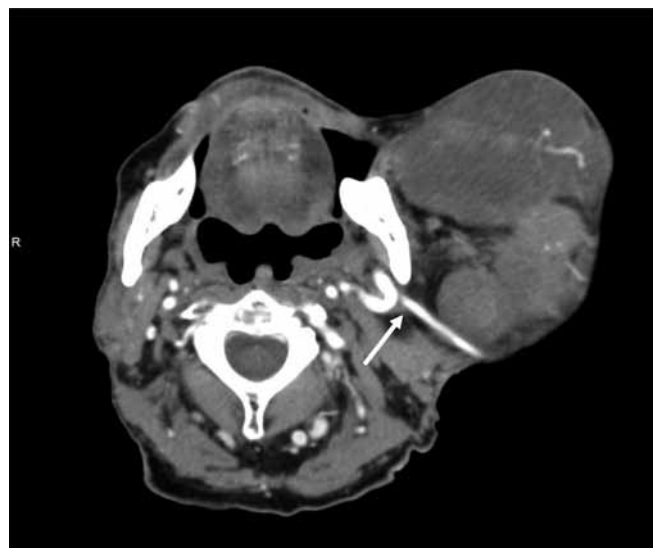

Fig. 3. Pre-operative CT scan showing the tumour pedicle (arrow) arising from facial artery. It measured about 15 cm in length, and demonstrated numerous feeding vessels.

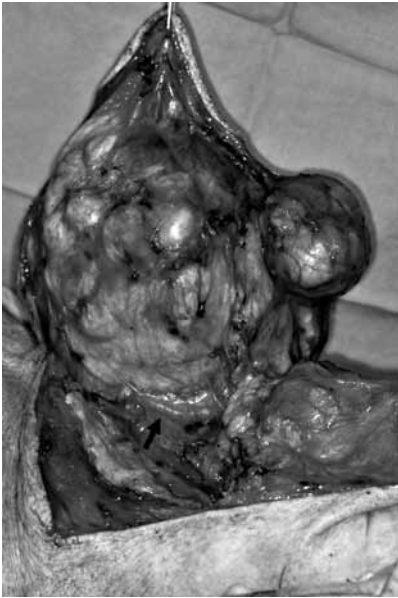


Fig. 4. Intra-operative image showing the multinodular tumour and the main vascular pedicle (arrow).

Microscopically, the tumour was composed of islands and strands of epithelial cells in a hyaline stroma. Spindle and plasmocytoid myoepithelial cells in a myxoid stroma were also abundant. All areas of the surgical specimen were microscopically analysed, and none showed evidence of malignant transformation. On histological analysis and immunohistochemistry, the lesion was identified as a pleomorphic adenoma with negative surgical margins. The patient presented good aesthetic and functional results (Fig. 5), without signs of facial nerve dysfunction (House Brackmann grade I). At 5-year follow-up the patient was doing well, without clinical or radiographic evidence of recurrence.

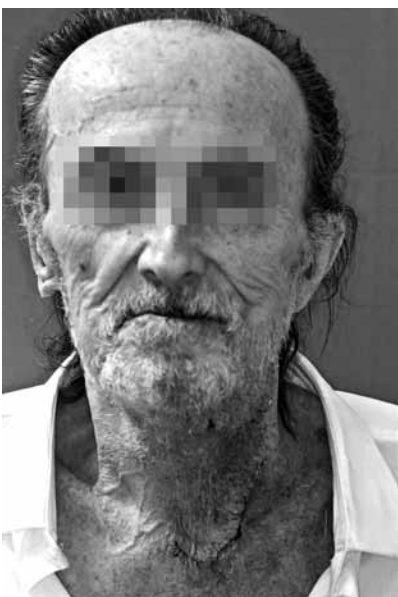

Fig. 5. Post-operative image showing clinical aspect after giant tumour removal with facial nerve preservation.

Discussion

Pleomorphic adenoma is the most common salivary gland tumour. The main site of occurrence is the parotid gland, affecting patients of any age, most frequently between the fifth and sixth decades of life³. Although uncommon, cases of giant pleomorphic adenomas have been described the majority of which involved the parotid gland. The first case of giant pleomorphic adenoma published in medical literature was reported by Spence in 1863⁶, who described the treatment of a mixed tumour > 1 kg.

In 1956, Short and Pullar⁷ published an English language review of massive pleomorphic adenomas and a case-report of a 2.3 kg adenoma. In 1989, Schultz-Coulon⁸ reviewed 31 cases of giant pleomorphic adenomas of the parotid gland. The author found a female predominance (64.5%), with an age range from 20 to 40 years old, and a tumour weight between 1 to 27 kg.

Buenting reported the 10 largest pleomorphic adenomas published in the English language literature, and found a mean tumour weight of 7.8 kg; nine of 10 occurred in females, with a mean age of 56 years. His case was the 5th largest pleomorphic adenoma reported (6.85 kg).

In our case, the patient was a man who presented a mass with a 30-year history of evolution that weighed 7.3 kg, more than the Buenting case report.

In most of the cases described in the literature, the lack of information and patient's negligence are considered as the most relevant aspects influencing the treatment delay. In our case, it must be considered that the patient was homeless and away from his family.

The incidence of malignant transformation in adenomas ranges from 1.9% to 23.3%⁹. The risk increases in tumours with long-standing evolution, recurrence, advanced age of the patient and location in a major salivary gland¹⁰. Some authors postulated that the risk of malignant transformation increases from 1.6% in tumours with less than 5 years of evolution, to 9.5% for those presenting for more than 15 years¹¹.

The classic clinical history of carcinoma ex-pleomorphic adenoma is a slow-growing mass for many years, with a recent fast growth phase. A case of a giant PA with malignant transformation with this typical history was reported in 2005 by Honda⁴ in a 72-year-old woman with a slow growing parotid lesion for 20 years, with a rapid increase in the last 3 months.

In the Schultz-Coulon⁸ review, 3 of 31 cases of giant adenomas showed areas of malignant transformation. In our case, although the patient presented all the characteristics for an increased risk of malignancy, clinically and histologically there was no such evidence.

Neglecting even a benign parotid tumour carries an increasing risk of facial nerve injury when treatment is performed. The bony and muscular deformity associated with such tumours is uniformly disfiguring and incapaci-

tating. Although it is generally accepted that the majority of all giant adenomas remain non-malignant, this case and others like it should serve to remind us that the clinical course of these masses can be far from benign. We believe that early excision of parotid pleomorphic adenomas is desirable if the patient will tolerate surgery.

References

- ¹ Phillips DE, Jones AS. *Reliability of clinical examination in the diagnosis of parotid tumors*. JR Coll Surg Edinb 1994;392:100-2.
- ² Buenting JE, Smith TL, Holmes DK. *Giant pleomorphic adenoma of the parotid gland: case report and review of the literature*. Ear Nose Throat J 1998;77:634, 637-8, 640.
- ³ Ellis GL, Auclair PL, editors. *Atlas of tumor pathology. Tumours of the salivary glands*. Washington, DC: Armed Forces Institute of Pathology; 1995; 39-41.
- ⁴ Honda T, Yamamoto Y, Isago T, et al. *Giant pleomorphic adenoma of the parotid gland with malignant transformation*. Ann Plast Surg 2005;55:524-7.
- ⁵ Duck SW, McConnel FM. *Malignant degeneration of pleomorphic adenoma. Clinical implications*. Am J Otolaryngol 1993;14:175-8.
- ⁶ Spence J. *Case of enormous deep-seated tumour of the face and neck, successfully removed by operation plates*. The Dublin Journal of Medical Science 1863;36:272-83.
- ⁷ Short DW, Pular P. *Giant parotid tumors: with report of a case*. J Roy Coll Surg (Edinburgh) 1956;3:240-8.
- ⁸ Schultz-Coulon HJ. *Pleomorphic giant adenomas of the parotid gland*. Laryngorhinootologie 1989;68:445-9.
- ⁹ Auclair PL, Ellis GL. *Atypical features in salivary gland mixed tumors: their relationship to malignant transformation*. Mod Pathol 1996;9:652-7.
- ¹⁰ Yamamoto Y. *Clinical signs and histology of carcinoma in pleomorphic adenoma*. Otologia 1994;87:1320-4.
- ¹¹ Eneroth CM, Zetterberg A. *Malignancy in pleomorphic adenoma. A clinical and microspectrophotometric study*. Acta Otolaryngol 1974;77:426-32.

Received: November 14, 2011 - Accepted: January 19, 2012

Address for correspondence: Achille Tarsitano, Maxillofacial Surgery Unit, "S. Orsola-Malpighi" Hospital, University of Bologna, via G. Massarenti 9, 40100 Bologna, Italy. Tel. +39 051 6364204. E-mail: achilletarsitano@gmail.com

CASE SERIES AND REPORTS

Minimally invasive surgical removal of an intracochlear schwannoma causing an intractable paroxysmal positional vertigo

Trattamento chirurgico mini-invasivo di un neurinoma cocleare scatenante una vertigine parossistica posizionale non responsiva al trattamento

B. SERGI, E. DE CORSO, D. LUCIDI, G. PALUDETTI

Clinic of Otorhinolaryngology, Università Cattolica del Sacro Cuore, Rome, Italy

SUMMARY

Intracochlear schwannomas are rare tumours. Diagnosis is based on high-resolution MRI, which should be used for accurate determination of the location of tumours. We report a case of a cochlear schwannoma that presented with profound hearing loss and intractable paroxysmal positional vertigo, which was diagnosed with gadolinium-enhanced MRI and removed using a transcanal minimally-invasive transotic approach.

KEY WORDS: Intracochlear schwannoma • MR • Surgical approach

RIASSUNTO

I neurinomi intracocleari sono tumori rari. La diagnosi si basa sulla RM, che fornisce accurate informazioni sulla loro localizzazione. Descriviamo un caso di neurinoma intracocleare manifestatosi con ipoacusia profonda e una intrattabile vertigine posizionale: la diagnosi è stata effettuata con la RM con gadolinio e il tumore rimosso mediante un approccio mini-invasivo transotico transcanalare.

PAROLE CHIAVE: Neurinoma intracocleare • RM • Approccio chirurgico

Acta Otorhinolaryngol Ital 2015;35:297-299

Introduction

Intracochlear schwannoma is a rare clinical entity and its diagnosis is facilitated with MRI with gadolinium used for the investigation of hearing loss and vertigo.

In the literature, only a few case reports and small series have described the clinical features, radiological findings and treatment options of this pathology. Intracochlear schwannomas typically present with sensorineural hearing loss which is usually progressive, and 75% of cases exhibit total deafness in the affected ear; approximately 15 to 32% of cases can present with sudden hearing loss^{1,2}. Occasionally, a mixed type hearing loss can occur, presumably because of increased intracochlear impedance³. Vertigo is less frequent, but may be pharmacologically intractable, requiring surgery, and it may be due to tumour extension to vestibular cavities, vestibular nerve compression, or to secondary endolymphatic hydrops².

We present a case of an intracochlear schwannoma that presented with intractable paroxysmal positional vertigo and profound hearing loss that progressed over approximately 3 years and diagnosed by MRI.

Case report

A 29-year-old man presented with a 5-year history of left-sided hearing loss: the symptoms started with a mild hearing loss limited to 500 and 1000 Hz frequencies and progressively worsened to profound hearing loss in 3 years. Two MRIs were obtained secondary to hearing loss (2008-2010), and both scans were reported to be normal. He referred to our clinic two years later for the onset of vertigo. Clinical examination was negative and audiometric testing confirmed profound left hearing loss with absence of otoacoustic emissions. The Dix-Hallpike manoeuvre showed a left paroxysmal positional vertigo and it was treated with an Epley manoeuvre. The patient was followed up every 14 days: he reported a slight benefit from the manoeuvres but his symptoms did not disappear; after two months, for the persisting positional vertigo despite the repositioning manoeuvres, he was submitted to a new MRI which showed a lesion filling almost all the left cochlea. The soft tissue mass appeared enhanced on T1-weighted images with gadolinium and hypointense on T2-weighted images (Fig. 1) leading to the diagnosis of schwannoma. Upon more careful analysis of the previ-

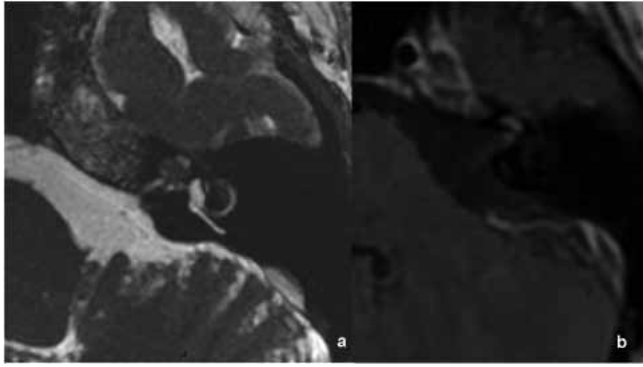


Fig. 1. Axial MRI: (a) the T2-weighted image demonstrates a hypointensity of almost all the cochlea with the loss of the normal fluid signal of the endolymphatic space; (b) the post-contrast T1-weighted image shows diffuse enhancement of the left cochlea up to the fundus of the internal auditory canal and no abnormal enhancement of the vestibule.

ous MRIs, a very small mass limited to the basal turn of the cochlea was apparent (Fig. 2). Because of severe vertigo, a complete resection was performed via a transcanal minimally-invasive transotic approach: monitoring facial nerve function, a postauricular incision was performed, the ear canal was skeletonised and the ear drum was elevated; after the removal of the incus and the stapes, the promontory was drilled out starting from the area between the round and oval windows, exposing the basal turn of the cochlea; once the soft tissue mass was individuated, it was gently removed up to the fundus of the internal auditory canal. The remnant of the cochlea was filled with a piece of temporal muscle and sealed with fibrin glue. The histologic findings were consistent with the radiologic diagnosis of schwannoma. Post-operative period was uneventful and his symptoms resolved.

Discussion

Intralabyrinthine schwannomas have variable presenting symptoms and, even if extremely rare, should be considered in any patient who presents with unilateral hearing loss⁴. We presented a case of a young patient with a single-sided deafness and paroxysmal positional vertigo that did not improve despite repositioning manoeuvres: indeed such patients, after treatment, reported only reduction of symptoms probably due to a transient rehabilitation of the involved side.

Diagnosis is made with T1- and T2-weighted MRI sequences with gadolinium enhancement even if it is limited by tumour size. Small intralabyrinthine lesions may be particularly difficult to see, and may be seen only in retrospect when the attention of the radiologist is focused on it⁵. MRI is also necessary for differential diagnosis that has to be made mainly with labyrinthitis: in these pathologies, the enhancement is less sharp and often involves all the cochlea and/or the vestibule, and during follow-up it tends to decrease⁶.

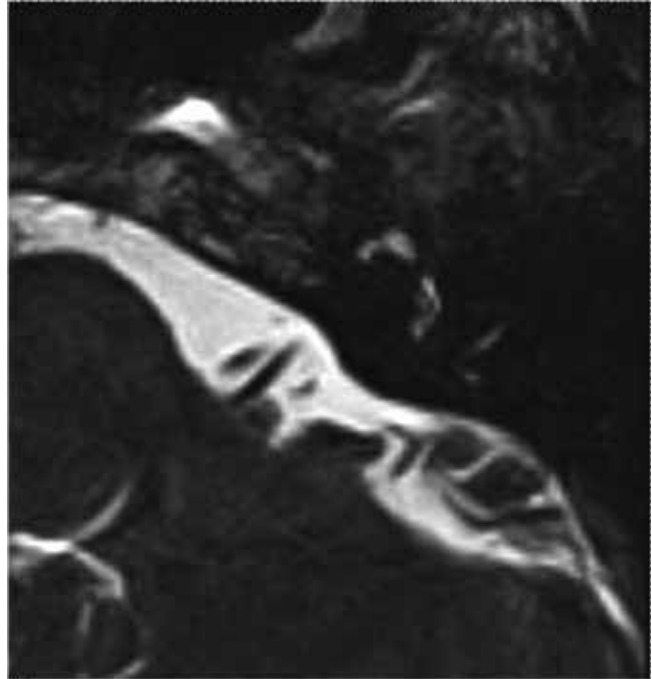


Fig. 2. Axial T2-weighted image demonstrates a hypointensity limited to the basal turn of the cochlea.

Kennedy proposed a classification system related to the site of the tumour: intravestibular, intracochlear, intravestibulocochlear, transmodiolar, transmacular, transotic and tympanolabyrinthine. Our case was a pure intracochlear type, which is one of the most common types of intralabyrinthine schwannoma and accounting for 28% of all reported cases³.

Concerning the origin of an intracochlear schwannoma, several causes have been hypothesised: the Schwann cells are distally limited to the modiolum for the cochlear nerve and a schwannoma may extend to the cochlea directly from the modiolum or the fundus of the internal auditory canal or indirectly from the scarpa ganglion through the vestibular cavities³.

Surgical intervention for intracochlear schwannoma is indicated in patients with intractable vertigo, wide extension of the tumour into the cerebellopontine angle or middle ear, evidence of tumour growth and concern about pathologic diagnosis⁷.

The surgical approach depends on the location of the tumour and its extension into the internal auditory canal, if present. Tumours confined to the cochlea can be removed using a postauricular transcanal transotic approach, as in our surgery, or using a transcanal approach⁸. Using these approaches particular care must be reserved to the petrous carotid artery, which can be very close to the cochlea, and not to injure the facial nerve when opening the middle turn of the cochlea. The traditional transmastoid transotic approach will be reserved for larger tumours extending into the internal auditory canal. Entering the modiolum will result

in egress of cerebrospinal fluid from the internal auditory canal into the middle ear, leading to the need of obliterate the middle ear to prevent cerebrospinal fluid leakage; in our case, we conservatively managed the cerebrospinal fluid leakage packing the cochlear remnant with soft tissue and sealing it with fibrin glue. Stereotactic radiosurgery may be indicated in progressively enlarging tumours, which are asymptomatic or in patients with comorbid medical conditions that preclude surgery. Non-surgical management with serial MRI scans is an option when the patient still has residual hearing or if the patient is asymptomatic³.

Conclusions

A cochlear schwannoma is a rare diagnosis in case of bilateral hearing loss, but it should always be considered in case of unilateral hearing loss. Also, the radiologist should be aware of this rare clinical entity as they examine the MRI which represents the diagnostic test of choice. As hearing preservation is not an outcome of intracochlear schwannoma resection, observation with serial MRI scans is indicated for the majority of patients. Surgical excision should be considered in case of tumour growth and/or intractable vertigo.

References

- ¹ Daniels RL, Swallow C, Shelton C, et al. *Causes of unilateral sensorineural hearing loss screened by high-resolution fast spin echo magnetic resonance imaging: review of 1,070 consecutive cases*. *Am J Otol* 2000;21:173-80.
- ² Grayeli AB, Fond C, Kalamarides M, et al. *Diagnosis and management of intracochlear schwannomas*. *Otol Neurotol* 2007;28:951-7.
- ³ Kennedy R, Shelton C, Salzman K, et al. *Intralabyrinthine schwannomas: diagnosis, management, and a new classification system*. *Otol Neurotol* 2004;25:160-7.
- ⁴ Jackson LE, Hoffmann KK, Rosenberg SI. *Intralabyrinthine schwannoma: subtle differentiating symptomatology*. *Otolaryngol Head Neck Surg* 2003;129:439-40.
- ⁵ Miller ME, Moriarty JM, Linetsky M, et al. *Intracochlear schwannoma presenting as diffuse cochlear enhancement: diagnostic challenges of a rare cause of deafness*. *Ir J Med Sci* 2012;181:131-4.
- ⁶ Magliulo G, Colicchio G, Romana AF, et al. *Intracochlear schwannoma*. *Skull Base* 2010;20:115-8.
- ⁷ Jiang ZY, Kutz JW Jr, Roland PS, et al. *Intracochlear schwannomas confined to the otic capsule*. *Otol Neurotol* 2011;32:1175-9.
- ⁸ Zhu AF, McKinnon BJ. *Transcanal surgical excision of an intracochlear schwannoma*. *Am J Otolaryngol* 2012;33:779-81.

Received: August 3, 2012 - Accepted: February 7, 2013

In Memoriam of Prof. Giorgio Sulsenti

Prof. Giorgio Sulsenti passed away on March 19, 2015. He left us in his own inimitable style, without fanfare, but accompanied with his usual sense of humour and profound wisdom. He was born in Modica, one of the most beautiful cities in Sicily. The “island” was always in his heart and soul, and especially in his Sicilian accent that never abandoned him.

Prof. Giorgio Sulsenti graduated in Medicine and Surgery in Catania, and soon after moved to Bologna where he specialised in both Otorhinolaryngology and Anesthesiology. His professional and academic career fully developed in Bologna. In the mid-sixties, he visited Maurice Cottle in Chicago, and introduced Cottle’s concepts in Italy and Europe. This marked the birth of modern rhinology in Europe under the guidance of many talented rhinologists (Masing, Montserrat-Viladiu, Guillen, Krajina, van Dishoek and the young Huizing, among many others) that followed Cottle’s philosophy. Soonafter, his practice surpassed all expectations and brought him patients from far and wide.

In 1972, Prof. Sulsenti created the first Division of Rhinology in an Italian public hospital. In the same year, he published his book *‘Chirurgia Funzionale ed Estetica del Naso’*, which was the first book on functional-aesthetic nasal surgery based on new concepts. In his book, Prof. Sulsenti described the terminology, instruments and various surgical approaches and techniques.

The text was beautifully illustrated with the excellent drawings by A. Faggioli in black and white with red accents. These illustrations played an important role in the 1970s and 1980s. A revised and expanded version was published in 1994 with the collaboration of Pietro Palma.

In the late 1970s, he pioneered international live-surgery rhinology courses in Bologna that attracted hundreds of colleagues worldwide, with growing success until the mid 1990s.

In 1980, he was elected President of the European Rhinologic Society (ERS), and organised the ERS Congress in Bologna coupled with an international live-surgery course featuring top-notch rhinosurgeons, from America and Europe.

Starting from the early 1970s, Prof. Sulsenti became an acclaimed international speaker in courses and conferences all around the world.

He was the founder of the Italian Academy of Rhinology, and became the source of reference for the entire Italian rhinologic community. His teaching activity reached a zenith when he became the Chief of the ENT Department at



Imola, Bologna. He organised several courses each year and his department was populated by national and foreign colleagues willing to improve their surgical skills in rhinology. Prof. Sulsenti was a true innovator, and understood the limitations of dogmatic teaching. He incorporated the newest aesthetic rhinoplasty techniques into the well-established *corpus* of Cottle’s philosophy. The unforgettable excitement of his mid-eighties courses attended by Prof. Gene Tardy and Prof. Stammberger as guest speakers and surgeons remains emblazoned in our memories. The newest techniques in rhinoplasty and endoscopic sinus surgery enthralled the audience for many days.

On a personal level, Prof. Sulsenti was a highly charismatic person with a very strong personality blessed by self-confidence that allowed him to win many battles, especially at a time when he was a kind of “lone wolf” in the domestic rhinoplasty arena dominated by general plastic surgeons. He placed his greatest demands on himself, and encouraged his colleagues to become masters of the technical aspects of rhinology and the ethical aspects of the doctor-patient relationship.

We have both been fortunate to have had him as our professional mentor and a matchless peer during the trials and tribulations of life. He will always live in the hearts of those who were introduced by his passion and talent to the fascinating world of surgical rhinology.

Pietro Palma and Ignazio Tasca

NOTIZIARIO SIO

CONSIGLIO DIRETTIVO SIO (2015/2016)

Filipo R.	Presidente SIO	(Scad. Maggio 2016)
Leone C.A.	Vice-Presidente	(Scad. Maggio 2016)
Cassandro E.	Vice-Presidente	(Scad. Maggio 2017)
Scasso F.	Segretario	(Scad. Maggio 2016)
Gallo A.	Tesoriere	(Scad. Maggio 2016)
Ralli G.	Bibliotecario	(Scad. Maggio 2018)
	Segretario del Presidente	(Scad. Maggio 2016)
Barbara M.	Consigliere	(Scad. Maggio 2016)
Bellussi M.L.	Consigliere	(Scad. Maggio 2016)
Berettini S.	Consigliere	(Scad. Maggio 2016)
Galli J.	Consigliere	(Scad. Maggio 2016)
Iemma M.	Consigliere	(Scad. Maggio 2016)
Iengo M.	Consigliere	(Scad. Maggio 2016)
Martini A.	Consigliere	(Scad. Maggio 2016)
Piane R.	Consigliere	(Scad. Maggio 2016)
Pisani P.	Consigliere	(Scad. Maggio 2016)
Vicini C.	Consigliere	(Scad. Maggio 2016)
Spriano G.	Past president	(Scad. Maggio 2016)
Paiano M.T.	Consigliere agg. LP	(Scad. Maggio 2015)

Comitato permanente per l'aggiornamento dello statuto e del regolamento

Filipo R.	Presidente SIO	(Scad. Maggio 2016)
Lauriello M.	Segretario dell'AUORL	(Scad. Maggio 2018)
Rugiu M.G.	Segretario dell'AOOI	(Scad. Maggio 2017)
Scasso F.	Segretario SIO	(Scad. Maggio 2016)
Maiolino L., Motta S., Passali GC.	Collegi nominati dall'AUORL	(Scad. Maggio 2017)
Grasso R., Piemonte M., Tagliabue A.	Collegi nominati dall'AOOI	(Scad. Maggio 2017)

Revisori dei conti SIO

Cappello V.	(Scad. Maggio 2018)
Panetti G.	(Scad. Maggio 2018)
Sessa M.	(Scad. Maggio 2018)
Tirelli G.	(Scad. Maggio 2018)

Collegio dei Proibiviri SIO

Chiesa F.	(Scad. Maggio 2018)
Conticello S.	(Scad. Maggio 2018)
De Benedetto M.	(Scad. Maggio 2018)
Fiorella R.	(Scad. Maggio 2018)
Passali D.	(Scad. Maggio 2018)

Responsabile gestione della qualità

Della Vecchia L.	(Scad. Maggio 2018)
------------------	---------------------

Organo di consulenza SIO

Bussi M., Camaioni A., Casolino D., Conticello S., Coppo L., Cuda D., De Benedetto M., De Campora E., De Campora L., De Vincentiis I., Felisati D., Fiorella R., Laudadio P., Marcucci L., Miani P., Motta G., Ottaviani A., Passali D., Paludetti G., Piemonte M., Puxeddu P., Rinaldi Ceroni A., Sartoris A., Serra A., Sperati G., Zaoli G.

Delegati

EUFOS	Piantanida R.	(Scad. Maggio 2016)
	Fiorella M.L.	(Scad. Maggio 2017)
IFOS	Piemonte M.	(Scad. Maggio 2016)
	Galli J.	(Scad. Maggio 2017)
UEMS	Piantanida R.	(Scad. Maggio 2016)
	Motta G.	(Scad. Maggio 2017)
EHNS	Piantanida R.	(Scad. Maggio 2016)
	Motta G.	(Scad. Maggio 2017)

CONSIGLIO DIRETTIVO AOOI

Cuda D.	Presidente	(Scad. Maggio 2016)
Danesi G.	Vice-Presidente	(Scad. Maggio 2016)
Radici M.	Vice-Presidente	(Scad. Maggio 2016)
Tortoriello G.	Vice-Presidente	(Scad. Maggio 2016)
Rugiu M.G.	Segretario-tesoriere	(Scad. Maggio 2017)
Ansarin M.	Consigliere	(Scad. Maggio 2016)
Campanini A.	Consigliere	(Scad. Maggio 2016)
Gianformaggio C.	Consigliere	(Scad. Maggio 2016)
Miani C.	Consigliere	(Scad. Maggio 2016)
Napolitano A.	Consigliere	(Scad. Maggio 2016)
Panu F.	Consigliere	(Scad. Maggio 2016)
Piantanida R.	Consigliere	(Scad. Maggio 2016)
Ruscito P.	Consigliere	(Scad. Maggio 2016)
Santandrea L.	Consigliere	(Scad. Maggio 2016)

Collegio dei probiviri AOOI

Chiesa F.	(Scad. Maggio 2016)
De Benedetto M.	(Scad. Maggio 2016)
Laudadio P.	(Scad. Maggio 2016)
Sperati G.	(Scad. Maggio 2016)
Villari G.	(Scad. Maggio 2016)

Comitato permanente per l'aggiornamento dello statuto e del regolamento (A.O.O.I.)

Grasso R.	(Scad. Maggio 2017)
Piemonte M.	(Scad. Maggio 2017)
Tagliabue A.	(Scad. Maggio 2017)

Delegati

IFOS	Piemonte M.	(Scad. Maggio 2016)
UEMS EUFOS EHNS	Piantanida R.	(Scad. Maggio 2016)

CONSIGLIO DIRETTIVO AUORL

Bussi M.	Presidente	(Scad. Maggio 2017)
Paludetti G.	Vice-Presidente	(Scad. Maggio 2017)
Nicolai P.	Vice-Presidente	(Scad. Maggio 2017)

Lauriello M.	Segretario-tesoriere	(Scad. Maggio 2018)
Aluffi Valletti P.	Consigliere	(Scad. Maggio 2017)
Maiolino L.	Consigliere	(Scad. Maggio 2017)
Martini A.	Consigliere	(Scad. Maggio 2017)
Motta G.	Consigliere	(Scad. Maggio 2017)
Passali F.M.	Consigliere	(Scad. Maggio 2017)
Quaranta N.	Consigliere	(Scad. Maggio 2017)
Sellari Franceschini S.	Consigliere	(Scad. Maggio 2017)
Cassandro E.	Past-President	(Scad. Maggio 2017)

Collegio dei probiviri

Barillari U.	(Scad. Maggio 2017)
Fusetti M.	(Scad. Maggio 2017)
Marchiori C.	(Scad. Maggio 2017)
Rinaldi Ceroni A.	(Scad. Maggio 2017)
Staffieri A.	(Scad. Maggio 2017)

Revisori dei conti

Bussi M.	(Scad. Maggio 2017)
Mancini P.	(Scad. Maggio 2017)

Comitato permanente per l'aggiornamento dello statuto e del regolamento

Bellussi L.	(Scad. Maggio 2017)
Chiarella G.	(Scad. Maggio 2017)
Ralli G.	(Scad. Maggio 2017)

Delegati

UEMS	Motta G.	(Scad. Maggio 2017)
EUFOS	Fiorella M.L.	(Scad. Maggio 2017)
IFOS	Galli J.	(Scad. Maggio 2017)
EHNS	Motta G.	(Scad. Maggio 2017)

Congresso Nazionale SIO Roma 2016

Relazione Ufficiale

Piemonte M. - Tecnologie d'oggi in ORL: dall'indicazione clinica all'impatto economico-assistenziale

Temi di Comunicazione

Attualità in otologia e audiologia (Leone C.A.)

Attualità in otorinolaringoiatria pediatrica (Barbara M.)

Attualità in rinologia (Serra A.)

Attualità in ambito cervico-cefalico (Bussi M.)

Tavola Rotonda

De Vincentiis M. - Chirurgia ricostruttiva verso protocolli di preservazione d'organo nel cancro della laringe

Relazione Ufficiale 2017

Cianfrone G. - Controversie diagnostico-terapeutiche in otorinolaringoiatria

Calendar of events – Italian and International Meetings and Courses

Acta Otorhinolaryngol Ital 2015;35:304-305

Information, following the style of the present list, should be submitted to the Editorial Secretariat of Acta Otorhinolaryngologica Italica (actaitalicaorl@rm.unicatt.it).

In accordance with the Regulations of S.I.O. and Ch.C.-F. (Art. 8) Members of the Society organising Courses, Congresses or other scientific events should inform the Secretary of the Association (A.U.O.R.L., A.O.O.I.) within the deadlines set down in the respective Statutes and Regulations.

OCTOBER-DECEMBER 2015

INTERNATIONAL WORKSHOP “OPEN PARTIAL HORIZONTAL LARYNGECTOMIES (OPHL) VERSUS TRANSORAL LASER MICROSURGERY (TLM) IN LARYNX CANCER”

October 8-10, 2015 • Castel Brando (TV) – Italy

Chairman: G. Rizzotto – Email: mail@nordestcongressi.it – Websites: www.nordestcongressi.it, www.oncolarynx.it

XXXIX CONVEGNO NAZIONALE AOOI (ASSOCIAZIONE OTORINOLARINGOLOGI OSPEDALIERI ITALIANI) • *October 16-17, 2015 • Genova – Italy*

President: Felice Scasso – E-mail: nec@nordestcongressi.it – Website: www.nordestcongressi.it

7th INTERNATIONAL SYMPOSIUM ON MENIERE’S DISEASE AND INNER EAR DISORDERS *October 17-20, 2015 • Rome – Italy*

Website: meniere2015.eu

VII INTERNATIONAL SYMPOSIUM ON RECENT ADVANCES IN RHINOSINUSITIS AND NASAL POLYPOSIS *October 22-25, 2015 • Panama*

Information: congresors2015@gmail.com

SESTO CONGRESSO NAZIONALE AICEF RCF • *October 23-24, 2015 • Rome – Italy*

Chairmen: Fabrizio Ottaviani, Gaetano Paludetti and Pier Giorgio Giacomini – Scientific Secretariat: pggiacomini@tiscali.it. Tel. +39 049 8601818 – Fax +39 0498602389

CURSO DE DISECCIÓN ENDOSCÓPICA DE LOS SENOS PARANASALES ENDOSCOPIC SINUS SURGICAL DISSECTION COURSE N. 49 *October 29-31, 2015 • Barcelona – Spain*

Info: Sra. Isabel – Tel. 93 205 02 04 – Fax 93 205 43 67 –E-mail: fundacion@iogi.org

3rd VIS (SOCIETÀ ITALIANA DI VESTIBOLOGIA) CONGRESS • *October 30-31, 2015 • Modena – Italy*

Website: www.vestibologyitaliansociety.com

SIOP (SOCIETÀ ITALIANA DI OTORINOLARINGOIATRIA PEDIATRICA) NATIONAL CONGRESS *November 5-7, 2015 • Rome – Italy*

E-mail: info@formazioneventisrl.it – Website: www.formazioneventisrl.it

CURSO DE MICROCIRUGÍA DEL OÍDO Y DISECCIÓN DEL HUESO TEMPORAL TEMPORAL BONE SURGICAL DISSECTION COURSE N. 118 • *November 18-20, 2015 • Barcelona – Spain*

Info: Sra. Conchi Castilla – Tel. 93 205 02 04 – Fax 93 205 43 67 – E-mail: entsecretaria@hotmail.es, info@iogi.org

XXXV CONGRESSO NAZIONALE SIAF – AGGIORNAMENTI IN AUDIOLOGIA INFANTILE**December 16-18, 2015 • Milan – Italy**Chairman: Antonio Cesarani – Website: www.sia-f.it**JANUARY-DECEMBER 2016****CORSO DI DISSEZIONE OTOLOGICA, OTONEUROLOGICA e IMPLANTOLOGIA Uditiva****January 5-7, 2016 • Paris – France**Course Directors: Olivier Sterkers, Daniele Bernardeschi. Info: daniele.bernardeschi@aphp.fr**INFLAMMATION – WINTER SYMPOSIUM • January 24-27, 2016 • Miami – USA**Directors: Sylvia Daunert, Angelo Azzi, Joseph Kissil, Stephen Nimer, Claes Wahlestedt, William J. Whelan – Website: www.miamiwintersymposium.com**6° CONGRESSO NAZIONALE CO.R.TE. • March 10-12, 2016 • Rome – Italy**President: Nicolò Scuderi – Tel. +39 06 35497114 – E-mail: corte@jaka.it**VI INTERNATIONAL WORKSHOP ON ENDOSCOPIC EAR SURGERY****April 7-9, 2016 • Modena and Verona – Italy**Course Directors: Livio Presutti and Daniele Marchioni – E-mail: Italy-ear-surgery@hotmail.com – Website: www.nordestcongressi.it**7th INTERNATIONAL SYMPOSIUM ON SENTINEL NODE BIOPSY IN HEAD AND NECK CANCER****April 8-9, 2016 • Rome - Italy**Organised by: M.G. Vigili and G. Tartaglione – Website: www.seventhsnb.com**15th INTERNATIONAL MEETING OF THE MEDITERRANEAN SOCIETY OF OTOLGY AND AUDIOLOGY****April 28-30, 2016 • Cappadocia – Turkey**President: S. Armagan Incesulu – Website: www.msoa2016.org**ENDOCHICAGO 7th WORLD CONGRESS FOR ENDOSCOPIC SURGERY OF THE SKULL BASE AND BRAIN • May 15-18, 2016 • Chicago (IL) – USA**Course Directors: Amin B. Kassam, Martin Corsten, Ricardo L. Carrau, Daniel M. Prevedello, Vijay Anand, Theodore H. Schwartz – Website: www.endoworld.org/d-1_7TH_WORLD_CONGRESS**103° CONGRESSO NAZIONALE SIO SOCIETA ITALIANA DI OTORINOLARINGOLOGIA E CHIRURGIA CERVICO-FACCIALE • May 25-28, 2016 • Rome – Italy**President: Roberto Filippo – Website: www.sioechcf.it**HEAL (HEARING ACROSS THE LIFESPAN): “EARLY INTERVENTION: THE KEY TO BETTER HEARING CARE” • June 2-4, 2016 • Lake Como – Italy**Website: www.heal2016.org – E-mail: meet@meetandwork.com – Tel. +39 049 8601818 – Fax +39 0498602389**CORSO PRATICO DI ANATOMIA CHIRURGICA E DISSEZIONE SPERIMENTALE OTOLOGICA 2° LIVELLO - XXVII EDIZIONE • June 6-10, 2016 • Sanremo (IM) – Italy**

A cura di: A. Tombolini, F. Baricalla – Coordinato da: A. Tombolini

26th CONGRESS OF THE EUROPEAN RHINOLOGIC AND THE 35TH INTERNATIONAL SYMPOSIUM OF INFECTION AND ALLERGY OF THE NOSE & 17th CONGRESS OF THE INTERNATIONAL RHINOLOGIC SOCIETY (ERS 2016) • July 3-7, 2016 • Stockholm – SwedenPresident: Pär Stjärne – Website: www.ers-isian2016.com**INSTRUCTIONAL WORKSHOP EUROPEAN ACADEMY OF OTOLGY AND NEURO-OTOLGY September 28 - October 1, 2016 • İzmir, Turkey**President: O. Nuri Ozgirgin – Website: www.eaono.org